

Justin Elfred Lan B. Paber, MD¹
 Michael Salvador D. Cabato, MD²
 Romeo L. Villarta, Jr, MD, MPH³
 Josefino G. Hernandez, MD³

¹Department of Otorhinolaryngology
 Philippine General Hospital
 University of the Philippines Manila

²Department of Radiology
 Philippine General Hospital
 University of the Philippines Manila

³Department of Otorhinolaryngology
 College of Medicine – Philippine General Hospital
 University of the Philippines Manila

Radiographic Analysis of the Ethmoid Roof based on KEROS Classification among Filipinos

ABSTRACT

Objective: The objective of the study was to describe the distribution of Keros classification among Filipinos.

Methods:

Study Design: Retrospective review of consecutive paranasal sinus computed tomography (PNS CT) scans.

Setting and Participants: One hundred and twenty-eight consecutive PNS CT scans done at the Philippine General Hospital from January 2006 to August 2007 were reviewed; 109 PNS CT scans were included in the study. The bilateral heights of the lateral lamellae of the cribriform plate were obtained, independently coded, and classified according to Keros classification.

Results: The mean height of the lateral lamella among Filipinos was 2.21mm. One hundred sixty five cases (81.6%) were classified as Keros I. Fifty two cases (17.9%) were classified as Keros II and one (0.5%) case was classified as Keros III. There was no significant difference in the height of the lateral lamella (t-test: $p=0.77$, CI 95%) and the distribution of Keros classification (Fisher's Exact test: $p = 0.78$) among younger (1-14 year) and older (>14 year) Filipino age groups. There was significant difference in the height (t-test: $p=0.05$, CI 95%) and the distribution of Keros classification (Fishers Exact Test: $p=0.01$) between Filipino females and males. There was no significant difference in the height of the bilateral lateral lamellae among Filipinos (paired t-test: $p=0.51$, CI 95%). There was no significant difference in the distribution of Keros classification (Fisher's Exact Test: $p=0.48$) between the right and left lateral lamella.

Conclusions: In over 80% of the time, Filipinos are classified as Keros I. Risk of inadvertent intracranial entry through the lateral lamella among Filipinos is less compared to populations with majority of cases classified as Keros II or III.

Keywords: *Keros classification, Filipino, Paranasal Sinus, PNS-CT, Ethmoid roof, Ethmoid anatomy*

Correspondence:
 Josefino G. Hernandez, MD
 Department of Otorhinolaryngology
 UP College of Medicine, University of the Philippines Manila
 Ward 10, Philippine General Hospital
 Taft Avenue, Ermita, Manila 1000
 Philippines
 Phone: (632) 526 4360
 Fax: (632) 525 5444
 Reprints will not be available from the author.

No funding support was received for this study. The authors signed disclosures that they have no proprietary or financial interest with an organization that may have a direct interest in the subject matter of this manuscript, or in any product used or cited in this study.

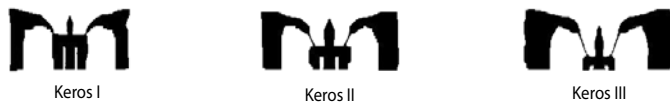
Presented at The 12th Asian Research Symposium in Rhinology Research Contest (1st place), Sofitel Philippine Plaza Manila, Pasay City, November 30, 2007.

Analytical Poster Presentation (2nd place), Philippine Society of Otolaryngology Head and Neck Surgery 51st Annual Convention, Sofitel Philippine Plaza Manila, Pasay City, November 30, 2007.

Radiographic analysis through high resolution computed tomography (CT) has been considered the gold standard in the preoperative evaluation of the paranasal sinuses (PNS).¹ The PNS CT scan provides the endoscopic sinus surgeon a “road map” to the anatomy of the ethmoid roof. The ethmoid roof is formed by the *fovea ethmoidalis*, an extension of the orbital plate of the frontal bone. The *fovea* articulates medially with the bone of the lateral lamella of the cribriform plate.² The lateral lamella is the thinnest bone in the entire anterior skull base. The study focused on the length of the lateral lamella of the cribriform plate and classified the measurement according to Keros classification.

Keros first described the differences in the level of the lateral lamella of the ethmoid.³ This classification depends on the length of the lateral lamella of the cribriform plate. In Keros I, the olfactory fossa is 1 to 3 mm deep, the lateral lamella is short, and the ethmoid roof is almost in the same plane as the cribriform plate. In Keros II, the olfactory fossa is from 4 to 7 mm deep, and the lateral lamella is longer. In Keros III, the olfactory fossa is 8 to 16 mm deep, and the ethmoid roof lies significantly above the cribriform plate. (Figure 1).

Figure 1. Keros Classification



Stammberger and Kennedy⁴ as cited by Gauba *et al*⁵ reported that the anatomical associations of the Keros classification suggest that longer lateral lamellae pose greater risks of intracranial entry during surgery. The change in angulation along with the length of the lateral lamella also contributes to increased risk.⁵ The Keros III classification presents the highest risk for intracranial entry during endoscopic sinus surgery (ESS) which can result in cerebrospinal fluid (CSF) leakage and consequently increased risk of meningitis. Hence, a more cautious approach is needed in operating on patients classified as such. Conversely, Keros I patients carry the least risk of entry into the cranium.

The percentage distribution of the Keros classification based on CT studies has been described in Caucasian populations. Floreani *et al*⁶ reported a distribution of 23% Keros I pattern, 50% Keros II and 27% Keros III in their study of 22 cadaver heads with PNS CT scans, and the mean heights of the lateral lamellae were 5.4 mm on the right and 4.7 mm on the left. Gauba *et al* in their study of coronal CT scans from 32 consecutive patients reported

11 (34.4%) patients classified as Keros I, 9 (28.1%) classified as Keros II, and 12 (37.5%) classified as Keros III.⁵ At least one study described the Keros classification in an Asian population. In 176 Thai patients, 11.9% presented with Keros I, 68.8% with Keros II, and 19.3% with Keros III.⁷

Data from a German study of 272 pediatric patients showed that the classification into the three types of positions of the ethmoid roof and cribriform plate according to Keros is possible in children from the second year of life.⁸

Asymmetry of the ethmoid roof has been reported in different studies. Zacharek *et al*⁹ measured the height of the ethmoid roof bilaterally in the CT scans of 100 consecutive patients. Their findings revealed that the right ethmoid roof was significantly lower in the right than the left. The same study also stated that the embryologic basis for the observed difference in ethmoid roof height between the right and left is not known. In another study, CT reports of 200 cases were analyzed for asymmetry of the ethmoid roof. Forty-three percent of the cases in the study showed symmetry in the height and contour of the right and left *fovea*. Asymmetry of the ethmoid roof was seen in the rest of their cases (57%): 96 scans demonstrated asymmetry in contour of the *fovea ethmoidale* and the remainder had asymmetry in height. Among the patients with asymmetry in height, the right side was lower than the left.¹


There is a paucity of descriptive studies on the Keros classification among Filipinos. Determining the distribution of Keros classification among this population may be useful in determining the risk of inadvertent intracranial entry during ESS and consequently avoid post-operative complications.

This study aimed to describe the distribution of Keros classification of Filipinos according to total number of cases, age group and gender; and the distribution and difference of Keros classification of Filipinos according to laterality.

MATERIALS AND METHODS

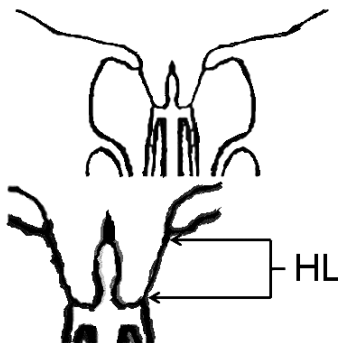
All available consecutive coronal CT scans of the paranasal sinuses of patients, performed at the Philippine General Hospital, with the Shimadzu 7000TX spiral CT scan (Shimadzu, Japan), between January 2006 and August 2007 were reviewed.

Patients with a history of trauma and/or nasopharyngeal masses having CT findings that showed disruption or invasion of the ethmoid roof were excluded from the study. Measurement of the ethmoid roof was not possible among these cases. Patients less than one year of age were likewise excluded.



The PNS CT scans used the bone algorithm, with a 3-mm interscan interval. Both the right and left lateral lamella in the CT scan were measured and coded separately. The measurements of the lateral lamella were simultaneously obtained by two authors (MSDC and JELBP) using a single caliper with smallest unit of measurement at 0.5mm. Interpretation was by consensus if there was disagreement while another author (JGH) made the decisive interpretation. Correction for scale of the obtained measurements was done. (Figure 2)

Figure 2. Showing landmark used in measurement



LEGEND: Height of lateral lamella

Data were encoded using Microsoft Excel worksheet (Microsoft Corp, USA). The lateral lamella measurements in this study were classified as follows:

- Keros I: the olfactory fossa is 1 to 3.99 mm deep
- Keros II: the olfactory fossa is 4 to 7.99 mm deep
- Keros III: the olfactory fossa is 8 to 16 mm deep

Statistical analyses were done using the Statistical Package for the Social Sciences version 15.0 for Windows (SPSS Inc., Chicago, IL, USA). All data were expressed as the mean +/- standard deviation as frequencies and proportion. All differences in means were analyzed using the student's t-test. Differences in the distribution of nominal variables were tested by Chi-square test or Fisher's Exact test, whichever was appropriate. P-values less than 0.05 were considered significant.

RESULTS

A total of 128 consecutive PNS CT scans done between January 2006 and August 2007 from patients of the Philippine

General Hospital were reviewed. Among these only 109 scans met the inclusion criteria and were included in the study.

The ages of the patients ranged between 5 and 78 years, with a mean age of 40 years. Fifty-eight (53%) were female patients and 51 (47%) were male patients. Each CT scan was counted as two cases (right and left) for a total of 218 cases. The clinical diagnoses of the patients were classified into four types: (1) nasal polyps/papillomas, 41%; (2) nasopharyngeal/maxillary masses (malignant and benign, not including nasal polyposis), 27%; (3) rhinitis/sinusitis/nasal congestion, 12%; and (4) others (normal CT findings, oral cavity cancer, orbital diseases) 20%.

The height of the lateral lamella (N=218) ranged from 0 to 10 mm with a mean 2.21 mm (SD 1.59). Among the cases, 178 (81.6%) were classified as Keros I; 39 (17.9%) were Keros II; and 1 (0.5%) was Keros III. (Table 1)

Table 1. Distribution of Keros Classification

Keros classification	Frequency	Percentage
I	165	81.6%
II	52	17.9%
III	1	0.5%
Total	218	100%

The cases were divided into two age groups. Among the cases, 20 (9.2%) were in Group 1 (1 to 14 years) and 198 (90.8%) were in Group 2 (over 14 years). The mean height of the lateral lamella for Group 1 was 2.11 mm (N=20, SD 1.65) and 2.21 mm (N=198, SD 1.58) for Group 2. There was no statistical difference in the mean of both groups using independent sample t-test analysis ($p=0.79$, CI 95%). (Table 2)

Table 2. Distribution of mean height of lateral lamella according to age group

Age Group	N	Mean	Std. Deviation
1 to 14	20	2.11	1.65
> 14	198	2.21	1.59

Independent samples t-test: $p=0.77$, mean difference -0.11, 95% CI (-0.84, 0.63)

In Group 1, 16 (80%) cases were classified as Keros I, 4 (20%) were Keros II. There was no case classified as Keros III in Group 1. In Group 2, 162 (81.8%) cases were classified as Keros I; 35 (17.7%) were Keros II; and 1 (0.5%) was Keros III. There was likewise no statistical difference in the distribution of Keros Type between the two age groups using Fisher's Exact Test ($p=0.78$). (Table 3)

Table 3. Distribution of Keros classification according to age group

Keros Type	1 to 14 year	Over 14 year
I	16 (80%)	162 (81.8%)
II	4 (20%)	35 (17.7%)
III	0	1 (0.5%)
Total	20 (100%)	198 (100%)

Fisher's Exact Test: p=0.78

The mean height of the lateral lamella of females was 2.01 (N=116, SD 1.37) and 2.43 (N=102, SD 1.78) for males. Independent t-test analysis showed a significant difference in the value of the means between females and males (p=0.05, CI 95%). (Table 4)

Table 4. Distribution of mean height of lateral lamella vs. gender

Gender	N	Mean	Std. Deviation
F	116	2.01	1.37
M	102	2.43	1.78

Independent samples t-test: p=0.05, mean difference -0.42, 95% CI (-0.85, 0.01)

One hundred two (87.9%) females were classified as Keros I and 14 (12.1%) were classified as Keros II. No female case was classified as Keros III. Seventy six males (74.5%) were classified as Keros I, 25 (24.5%) were Keros II, and 1 (1.0%) was classified as Keros III. Fisher's Exact Test also showed significant difference in the distribution of Keros type between females and males (p = 0.01). (Table 5)

Table 5. Distribution of Keros classification according to gender

Keros Type	Females	Males
I	102 (87.9%)	76 (74.5%)
II	14 (12.1%)	25 (24.5%)
III	0	1 (1.0%)
Total	116 (100%)	102 (100%)

Fisher's Exact Test: p=0.01

The height of the right lateral lamella (N=109) ranged from 0 to 6 mm with a mean of 2.25 mm. The height of the left lateral lamellae (N=109) ranged from 0 to 10 with a mean of 2.16 mm (SD 1.66). Paired t-test to determine the difference in paired means showed no significant difference (Paired t-test: p=0.51, mean difference 0.08, 95% CI [-0.17, 0.34])

Ninety-one patients (83.5%) were Keros I, 17 (15.6%) Keros II, and 1 (0.9%) Keros III for the left lateral lamella (N=109). Eighty-seven (79.8%) and 22 (20.2%) were classified as Keros I and II, respectively, for the right lateral lamella. No patient had Keros III classification for the right lateral lamella. (Table 6)

Table 6. Distribution of Keros classification according to laterality

Keros Type	Left	Right
I	91 (83.5%)	87 (79.8%)
II	17 (15.6%)	22 (20.2%)
III	1 (0.9%)	0
Total	109 (100%)	109 (100%)

Fisher's Exact Test: p=0.48

Comparison of the distribution of Keros type between the left and right lateral lamella showed no significant difference using Fisher's Exact Test (p=0.48).

DISCUSSION


Most of the CT scans included in the study had a clinical diagnosis of nasal polyps and/or papilloma (41%). Only 12% had a diagnosis of rhinitis/sinusitis/nasal congestion. These findings differed from the reports of Nitinavakarn *et al*⁷ where 2% of PNS CT scans had clinical diagnoses of nasal polyps and almost 60% of PNS CT had diagnoses of rhinosinusitis and chronic rhinitis. This difference in the clinical diagnosis of patients with rhinologic diseases may be due to the difference in the practice of Filipino doctors in requesting PNS CT. Other possible contributing factors may be the variation in the patients' socio-economic status, geographic location and the health care system in the Philippines.

The percentage distribution of Keros classification among Filipinos differed from the results presented by Floreani *et al*⁶ and Nitinavakarn *et al*.⁷ Both studies had majority of cases belonging to Keros II as opposed to the present study where majority of the cases were classified as Keros I. Gauba⁵ however reported a comparable distribution between Keros I and III; with the least percentage of patients classified into Keros II. (Table 7)

Table 7. Distribution of Keros classification: comparison with other studies

Keros type	Paber <i>et al</i> (n=218)	Floreani <i>et al</i> (n=22)	Nitinavakarn <i>et al</i> (n=176)	Gauba <i>et al</i> (n=32)
I	81.6%	23%	11.9%	34.4%
II	17.9%	50%	68.8%	28.1%
III	0.5%	27%	19.3%	37.5%

The observed difference in the distribution of Keros type of the cases in the studies mentioned earlier may be attributed to differences in the sample sizes of the study. Differences in ethnicity of the cases may also contribute to the variance in the distribution. To our knowledge, there is still no literature



correlating ethnicity with the structures of the ethmoid roof, particularly the lateral lamella of the cribriform plate.

The majority of the Filipino patients included in the study had Keros I classification. This suggests that there is less risk of inadvertent intracranial entry through the lateral lamella among Filipinos should they undergo ESS as opposed to patients with Keros II or III. The chances of CSF rhinorrhea due to unintentional intracranial entry and consequently the possibility of life threatening meningitis after ESS should also be less likely among Filipinos.

In the Philippine setting, the data may be valuable for endoscopic surgeons performing sinus surgery who don't have access to CT scans. The sinus surgeon can perform relatively safe surgery particularly in the ethmoid roof with the knowledge that in over 80% of Filipinos the lateral lamella of the cribriform plate is less than 4 mm.

The results of the study also revealed that there is no statistical difference in the distribution of Keros type according to age group. The distribution according to age group likewise mirrored the distribution of all cases included in the study. Keros I had the majority of cases and Keros 3 the least in both age groups. The risk of intracranial entry through the lateral lamella during ESS is similar for the younger and the older age group. Hence, the same degree of caution should be practiced when performing ESS in both age groups.

The means of the height of the lateral lamella between Filipino females and males were significantly different. The distribution of Keros classification between males and females likewise differed significantly. The authors were not able to retrieve any data from literature describing and comparing Keros classification according to gender. Data may be useful for further studies in the analysis of variations of the ethmoid roof.

There was no significant difference between the means of measurements of the height of the lateral lamella of the cribriform plate on the right from that of the left. There was also no significant difference in the Keros classification of the right and left lateral lamellae. Therefore the risk of intracranial entry through the lateral lamella during ESS is the same regardless of laterality.

There was no significant difference in the height of the bilateral lateral lamellae per patient. In addition there was also no difference in the distribution of Keros classification between the right and left lateral lamella of the cases. This suggests that there is symmetry in the height of the right and left lateral lamella among Filipinos. The presence of asymmetry of the ethmoid roof

has been reported consistently in literature. Zacharek *et al*⁹ and Lebowitz *et al*⁷ both agreed that the ethmoid roof is significantly lower in the right compared to the left. Data from the present study suggests that the bilaterally symmetric height in the lateral lamella does not contribute to asymmetry of the ethmoid roof.

Filipinos can be classified as Keros I in over 80% of the time. Although there may be a lower risk of inadvertent intracranial entry in this population, the same degree of caution should always be applied during endoscopic sinus surgery regardless of age or laterality as far as the lateral lamella is concerned. Other radiologic landmarks of the ethmoid roof are also important, and further studies on ethmoid roof anatomy among Filipinos should be conducted.

ACKNOWLEDGEMENTS

The authors would like to acknowledge Regielyn P. Santos-Cortez, MD, PhD for providing assistance in statistical analysis and Nadia M. Mariñas, MD for providing writing assistance.

REFERENCES

1. Lebowitz RA, Terk A, Jacobs JB, Holliday RA. Asymmetry of the ethmoid roof: analysis using coronal computed tomography. *Laryngoscope* 2001; 111:2122-2124.
2. Terrier FW, Ruefenacht W, Porcellini DB. Anatomy of the ethmoid: CT, endoscopic, and macroscopic. *Am J Rhinol* 1985; 144:493-500.
3. Keros P. [On the practical value of differences in the level of the lamina cribrosa of the ethmoid.] *Z Laryngologie, Rhinologie, Otologie Ihre Grenzgeb* 1962; 41:808-813.
4. Stammberger HR, Kennedy DW. Paranasal sinuses: anatomic terminology and nomenclature. The Anatomic Terminology Group. *Ann Otol, Rhinol Laryngol* 1995; 167:7-16.
5. Gauba V, Saleh GM. Radiological classification of anterior skull base anatomy prior to performing medial orbital wall decompression. *Orbit* 2006; 25:93-96.
6. Floreani SR, Nair SB, Switajewski MC, Wormald PJ. Endoscopic anterior ethmoidal artery ligation: a cadaver study. *Laryngoscope* 2006; 116(7):1263-1267.
7. Nitinavakarn B, Thanaviratananich S, Sangsilp N. Anatomical variations of the lateral nasal wall and paranasal sinuses: a CT study for endoscopic sinus surgery (ESS) in Thai patients. *J Med Assoc Thai* 2005; 88:763-768.
8. Anderhuber W, Walch C, Fock C. [Configuration of ethmoid roof in children 0-14 years of age]. *Laryngorhinootologie*. 2001;80(9):509-11.
9. Zacharek MA, Han JK, Allen R, Weissman JL, Hwang PH. Sagittal and coronal dimensions of the ethmoid roof: a radioanatomic study. *Am J Rhinol* 2005; 19(4):348-52.