



Erik A. Tongol, MD  
Alfredo Q.Y. Pontejos, Jr., MD  
Phillip B. Fullante, MD  
Arsenio Claro A. Cabungcal, MD  
Kimberly Mae C. Ong, MD

Department of Otorhinolaryngology  
Philippine General Hospital  
University of the Philippines Manila

# Intraosseus Arteriovenous Malformation of the Mandible: Extracorporeal Curettage and Immediate Replantation

## ABSTRACT

**Objective:** To describe a surgical technique in the treatment of arteriovenous malformations of the mandible

**Methods:**

- Design:** Case Report
- Setting:** Tertiary National University Hospital
- Participants:** One

**Result:** A 16-year-old boy underwent resection, extracorporeal curettage and immediate replantation of the hemimandible for intraosseous arteriovenous malformation. Postoperative follow up and imaging at one- and six-months showed no signs of recurrence, new bone formation and consolidation of the replanted right mandible with good symmetry and function.

**Conclusion:** Extracorporeal curettage followed by immediate replantation of the resected mandible seems to have yielded good early results in our case and may be a viable alternative especially when access to highly specialized microvascular surgical services is limited.

**Keywords:** arteriovenous malformation; mandible, abnormalities; extracorporeal curettage

**Intraosseus arteriovenous (AV)** malformations of the mandible are extremely rare and can cause significant morbidity and even mortality. Arriving at the correct diagnosis is oftentimes difficult due to the nonspecific signs and symptoms and absence of pathognomonic radiographic features. We present the case of a boy with a chronic history of on-and-off bleeding from and a unilateral swelling of the mandible that was misdiagnosed, causing morbidity and delay in treatment.

## CASE REPORT

A 16-year-old boy presented in our emergency room for intraoral bleeding and an expanding mass at the angle of the right mandible. The condition started 6 years prior to consult when the then 10-year-old patient developed spontaneous intraoral bleeding of the right mandible around the area of the second molar. He was brought to a hospital where tranexamic acid stopped the bleeding. A dentist extracted the tooth with profuse bleeding that was again controlled by tranexamic acid. Over the next 4 years progressive swelling was noted on the right angle of the

Correspondence: Dr. Alfredo Q.Y. Pontejos, Jr.  
Department of Otorhinolaryngology  
Ward 10, Philippine General Hospital  
University of the Philippines Manila  
Taft Avenue, Ermita, Manila 1000  
Philippines  
Phone: (632) 554 8400 local 2152  
Email: orl.up.pgh@gmail.com

The authors declare that this represents original material, that the manuscript has been read and approved by all the authors, that the requirements for authorship have been met by each author, and that each author believes that the manuscript represents honest work.

Disclosures: The authors signed disclosures that there are no financial or other (including personal) relationships, intellectual passion, political or religious beliefs, and institutional affiliations that might lead to a conflict of interest.

Presented at the Philippine Society of Otolaryngology Head and Neck Surgery Interesting Case Contest (3rd Place). May 12, 2018. Citystate Asturias Hotel, Puerto Princesa, Palawan.



Creative Commons (CC BY-NC-ND 4.0)  
Attribution - NonCommercial - NoDerivatives 4.0 International

mandible with intermittent bleeding that resolved spontaneously. The patient eventually developed a depressed mood and suicidal ideations which affected his schooling and social relationships.

Two years prior to consult, the mandibular mass was assessed to be an odontogenic cyst at another hospital but an attempted biopsy was deferred due to profuse bleeding. He underwent emergency tracheostomy due to the bleeding and impending respiratory failure and was subsequently sent home. Except for the mandibular mass and tracheostomy, he remained apparently well and asymptomatic until a day prior to consult when intraoral bleeding finally brought them to our institution.

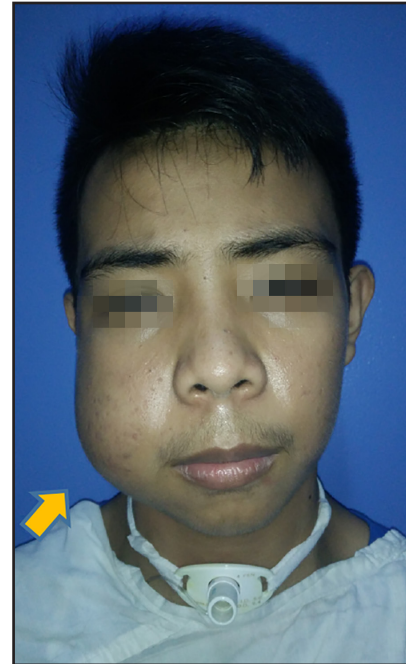
On examination, there was a soft, pulsating, movable non-tender 6 x 6 x 5cm mass over the angle of the right mandible with audible bruits. (Figure 1) The overlying skin was normal in color and there was no paresthesia.

Contrast-enhanced computed tomography (CT) scans showed an expansile lytic lesion with cortical thinning involving the right mandibular angle and ramus. Axial and coronal CT images showed tortuous arterial vessels arising from the right external carotid artery supplying the enhancing mandibular AV malformation with extension to the right masseter. (Figures 2A, B and 3A) Angiography showed feeding arteries arising from the right external carotid artery (facial and maxillary branches) with draining tributaries from the anterior and internal jugular veins (common facial vein). The nidus was measured to be 7 x 5 x 6 cm. (Figure 3B)

The patient was diagnosed with AV malformation of the mandible and underwent preoperative embolization and surgical treatment under general anesthesia the following day.

### Surgical Technique

Through a submandibular incision with lip split, the aberrant branch of the right internal jugular vein and the right external carotid artery were ligated. The soft tissue component of the arteriovenous malformation was excised before exposing the mandible. The proximal and distal extent of the intraosseous component of the right mandible was identified, followed by pre-bending of the reconstruction plate to conform to the mandible. Segmental mandibulectomy using a Gigli wire was done at the ascending ramus and at the junction of the right canine and first premolar. Using an extracorporeal technique, the teeth in the involved segment were extracted followed by curettage and hollowing of the mandible. (Figures 4A and 4B) Replantation of the cortical shell was achieved with a 17-hole titanium reconstruction plate and 7 screws. (Figure 4C) Maxillo-mandibular fixation was applied with Erlich arch bars on the contralateral side. The postoperative course



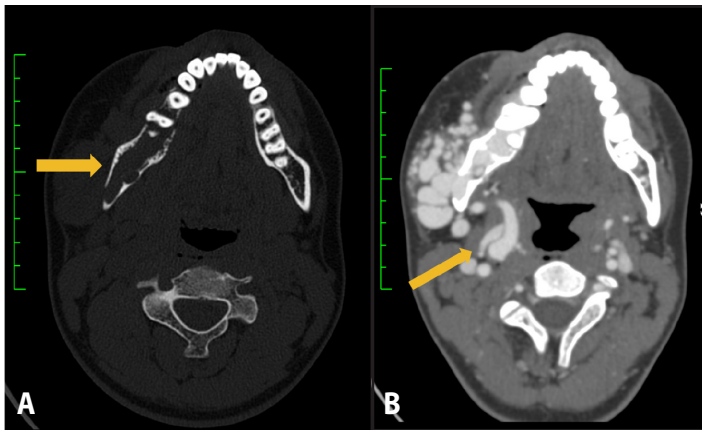
**Figure 1.** Preoperative facial photograph of patient. Note the mass on the right mandible (solid arrow). (Photo published with permission).

was uneventful and the patient was decannulated and subsequently sent home. On follow up after three weeks, there was still soft tissue swelling but no more episodes of oral bleeding, allowing him to return to school and slowly readjust to his normal daily activities. (Figure 5A) A panoramic radiograph at one- and 6-months post operation showed no signs of recurrence, new bone formation and consolidation of the replanted right mandible with good symmetry and function. (Figures 5B and 5C)

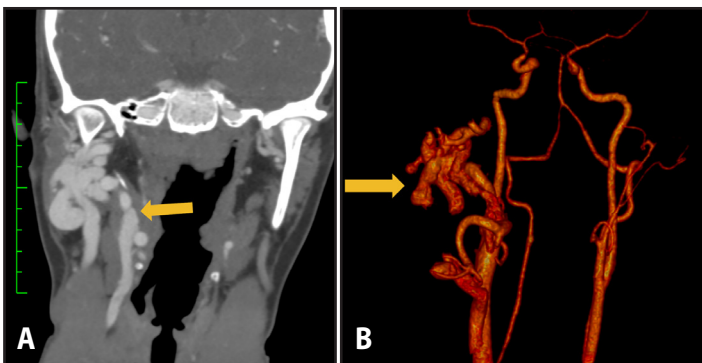
### DISCUSSION

Vascular malformations of the mandible have been referred to as “great radiologic imitators” and can look like any lesion, ranging from a cyst to a malignancy, with no pathognomonic radiographic features of its own.<sup>7</sup> It can be mistaken for odontogenic cysts or ameloblastoma because it most commonly appears as a poorly defined, multilocular radiolucent image, often with the appearance of honeycomb or soap bubbles.<sup>8</sup> This case was initially mistaken to be an odontogenic cyst and a biopsy was attempted leading to significant morbidity. Physician awareness of this clinical entity as a differential diagnosis may lessen such morbidities.

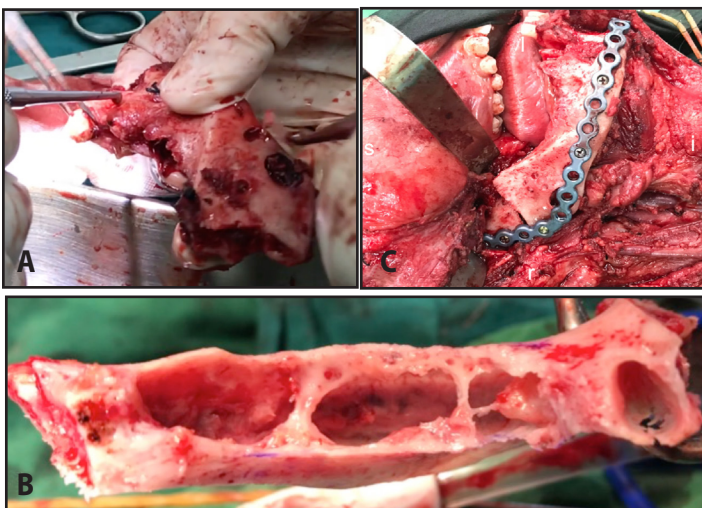
CT angiography remains the gold standard to delineate the location and number of feeding vessels and the pattern of drainage. In this case, with the help of the patient’s CT angiography the feeding arteries from



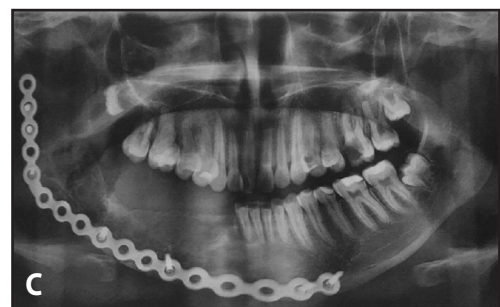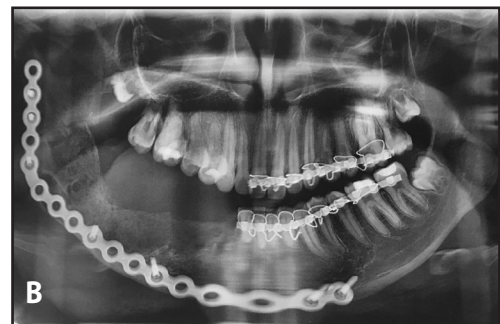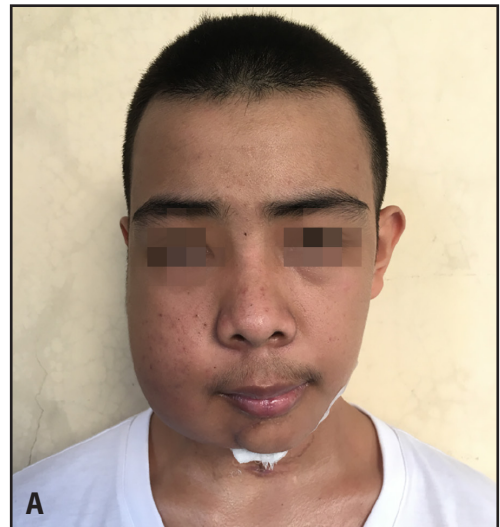**Figure 2.** CT images **A.** Axial bone window and **B.** Axial soft tissue window, showing cortical thinning (arrow) and arterial feeders from the right external carotid artery (arrow).



**Figure 3.** CT images **A.** Coronal soft tissue window **B.** Angiogram of the right external carotid artery showing feeding arteries from right external carotid artery (arrow) and a nidus measuring 7x5x6cm (arrow)



**Figure 4.** Intraoperative photos **A.** showing extraction of teeth and curettage of lesion from resected mandibular segment **B.** resected right mandibular cortical shell after extracorporeal tumor resection of the malformation **C.** showing replantation of mandibular segment and fixation with 17-hole reconstruction plate. (s, superior; i, inferior; r, right; l, left)



**Figure 5.** Postoperative photos **A.** 3 weeks, showing swelling of the right mandibular area, with good alignment of lower mandibular border **B.** Panoramic radiograph of patient at 1-month showing good symmetry **C.** Panoramic radiograph of patient at 6-months showing good symmetry and take of graft. (Photo published with permission).

the right external carotid artery were identified. This is helpful to the surgeons as the goal of treatment is to identify and remove the nidus of the AV malformation which represents the core of the pathological process of these malformations.<sup>2</sup>

The current recommended treatment for such large field defects with extensive collateral circulation is hemimandibulectomy, resulting in a major cosmetic and functional deformity which only can be repaired by immediate primary or secondary reconstruction. The conventional



surgical option of resection, reconstruction and bone grafting entails prolonged operative time, more blood loss, donor site disfigurement, possible disruption of growth and dependence on highly specialized microvascular surgeons. A surgical option that addresses the morbidities associated with the conventional method is radical tumor resection, extracorporeal curettage with immediate replantation of the resected mandibular segment after removal of the pathologic tissue.<sup>9-13</sup> This method was first described by Schneider, *et al.* in 1996 where they reported that this technique does not adversely affect anatomical morphology, mandibular growth nor neuromuscular function.<sup>12</sup> They claimed that this method maintained the continuity of the mandible and return to normal mandibular function was possible sooner.<sup>12</sup> This method is appropriate in this case because of the patient's very young age and its potential of not significantly disrupting mandibular growth and function. The use of immediate reconstruction with the patient's own free mandibular segment preserved facial symmetry and avoided the additional morbidity associated with a second operation for reconstruction of the resection site and at the donor site for the bone graft.<sup>13</sup> Further, this method enabled removal of all abnormal vascular tissue, thereby minimizing the problem of postoperative recurrence.<sup>10</sup> Theoretically, the hollowed cortical shell acts as an autogenous osteoinductive and osteoconductive medium, providing a structural graft which acts as a scaffold for bony ingrowth, at the same time, inducing local growth factors to stimulate bone healing.<sup>9</sup> Should the replanted segment succeed in the long term, maintaining mandibular form and masticatory function provide the best physiological matrix for favorable growth and development.<sup>14</sup>

This technique of resection, extracorporeal curettage and immediate replantation may be a viable option for treating such lesions without need for free tissue or bone transfers. It seems to have yielded good early results in our case and may be a viable alternative when access to highly specialized microvascular surgical services is limited.

#### REFERENCES

- Kohout MP, Hansen M, Pribaz JJ, Mulliken JB. Arteriovenous malformations of the head and neck: natural history and management. *Plast Reconstr Surg.* 1998 Sep; 102(3): 643-654. PMID: 9727427.
- Kaderbhai J, Breik O, Heggie AA, Penington AJ. High-flow paediatric mandibular arteriovenous malformations: case reports and a review of current management. *Int J Oral Maxillofac Surg.* 2017 Dec; 46(12): 1650-1655. DOI: 10.1016/j.ijom.2017.06.011; PMID: 28705626.
- Theologie-Lygidakis, N., Schoinohoriti, O., Tzerpos, F., Christopoulos, P., Iatrou, I., & Petersson, A. (2015). Management of Intraosseous Vascular Malformations of the Jaws in Children and Adolescents: Report of 6 Cases and Literature Review. *J Oral Maxillofac Res.* 2015 Jun 30; 6(2): e5. DOI: 10.5037/jomr.2015.6205; PMID: 26229584 PMID: PMC4516857.
- Fowell C, Jones R, Nishikawa H, Monaghan A. Arteriovenous malformations of the head and neck: current concepts in management. *Br J Oral Maxillofac Surg.* 2016 Jun; 54(5): 482-7. DOI: 10.1016/j.bjoms.2016.01.034; PMID: 27020371.
- Fahrni JO, Cho EY, Engelberger RP, Baumgartner I, von Kanel R. Quality of life in patients with congenital vascular malformations [Abstract]. *J Vasc Surg Venous Lymphat Disord.* 2014 Jan; 2(1): 46-51. DOI: 10.1016/j.jvsv.2013.09.001; PMID: 26992968.
- Shum JW, Clayman L. Resection and immediate reconstruction of a pediatric vascular malformation in the mandible: Case report. *Oral Surg Oral Med Oral Pathol Oral Radiol Endod.* 2010 Apr; 109(4): 517-524. DOI: 10.1016/j.tripleo.2009.10.020; PMID: 20097586.
- Dwivedi AN, Pandey A, Kumar I, Agarwal A. Mandibular arteriovenous malformation: A rare life-threatening condition depicted on multidetector CT angiography. *J Oral Maxillofac Pathol.* 2014 Jan; 18(1): 111-3. DOI: 10.4103/0973-029X.131930; PMID: 24959049 PMID: PMC4065426.
- Noreau G, Landry P, Morais D. Arteriovenous malformation of the mandible: review of literature and case history. *J Can Dent Assoc.* 2001 Dec; 67(11): 646-651. PMID: 11841745.
- Behnia H, Motamedi MH. Treatment of central arteriovenous malformation of the mandible via resection and immediate replantation of the segment: a case report. *J Oral Maxillofac Surg.* 1997 Jan; 55(1): 79-84. doi:10.1016/s0278-2391(97)90453-5; PMID: 8994473.
- Behnia H, Ghodoosi I, Motamedi, MH, Khojasteh A, Masjedi A. Treatment of arteriovenous malformations: assessment of 2 techniques—transmandibular curettage versus resection and immediate replantation. *J Oral Maxillofac Surg.* 2008 Dec; 66(12): 2557-2565. DOI: 10.1016/j.joms.2008.06.056; PMID: 19022136.
- Singh V, Bhardwaj P. Arteriovenous malformation of mandible: Extracorporeal curettage with immediate replantation technique. *Natl J Maxillofac Surg.* 2010 Jan; 1(1), 45-49. DOI: 10.4103/0975-5950.69168; PMID: 22442550 PMID: PMC3304184.
- Schneider C, Wagner A, Hollmann K. Treatment of intraosseous high flow arteriovenous malformation of the mandible by temporary segmental osteotomy for extracorporeal tumour resection: a case report. *J Craniomaxillofac Surg.* 1996 Oct; 24(5): 271-275. DOI:10.1016/s1010-5182(96)80057-6; PMID: 8938507
- Shum JW, Clayman L. Resection and immediate reconstruction of a pediatric vascular malformation in the mandible: Case report. *Oral Surg Oral Med Oral Pathol Oral Radiol Endod.* 2010 Apr; 109(4): 517-524. DOI: 10.1016/j.tripleo.2009.10.020; PMID: 20097586.
- Gallagher DM, Hillel D, Epker BN. Surgical treatment of an arteriovenous malformation of the mandible in a child. *J Maxillofac Surg.* 1983 Dec; 11(6): 279-283. DOI:10.1016/s0301-0503(83)80066-6; PMID: 658.