

Article

Postrumatic pneumorrhachis: report of three cases and classification proposal

Huber S. Padilla-Zambrano, Jessica Amaya-Quintero, Ramos-Villegas Yancarlos, Luis Rafael Moscote-Salazar, Willem Guillermo Calderon-Miranda, Joulen Mo-Carrascal, Johanna Maraby, Amit Agrawal
COLOMBIA, MEXICO, INDIA



DE GRUYTER
OPEN

Postrumatic pneumorrhachis: report of three cases and classification proposal

Huber S. Padilla-Zambrano¹, Jessica Amaya-Quintero¹, Ramos-Villegas Yancarlos¹, Luis Rafael Moscote-Salazar², Willem Guillermo Calderon-Miranda³, Joulén Mo-Carrascal¹, Johanna Maraby¹, Amit Agrawal⁴

¹University of Cartagena, Cartagena, COLOMBIA

²Neurosurgery, Universidad de Cartagena, COLOMBIA

³Resident of Radiology, National Autonomous University of Mexico, Mexico City, MEXICO

⁴Department of Neurosurgery, Narayna Medical College Hospital, Chinthareddypalem Nellore, Andhra Pradesh, INDIA

Abstract: The Pneumorrhachis is the presence of air at the level of the spinal canal. It can have several causes among which are: traumatic, iatrogenic among others. Clinical Cases: We present three cases of male patients handled by our neurosurgery service with traumatic pneumorrhachis patients, which were managed in a conservative manner, with control images. Conclusions: pneumorrhachis has traditionally been classified as internal if air is present in the subdural or subarachnoid space and external if the air is located at the epidural level. We propose a classification in degrees (Moscote-Agrawal-Padilla) which is more practical from the clinical and radiological point of view.

Key words: Pneumorrhachis, spinal neurotrauma, spinal cord

Introduction

The term Pneumorrhachis (PR) refers to the presence of air in the spinal canal, is a rare phenomenon with a varied etiology, being the posttraumatic PR the least frequent. (1) In most cases, it is asymptomatic, but may have symptoms that are related to its cause. (2) They are usually diagnosed incidentally in imaging studies such as computed tomography and magnetic resonance imaging. (3) PR has been

described in various pathologies. Knowledge of this is critical for the emergency physician and neurosurgeon. We present three cases and make a proposal of tomographic classification.

Illustrative cases

Case Report 1

A 30-year-old male patient, with no relevant history, received a gunshot wound in the cervical region. A cervical CT scan revealed

the presence of C4 fracture and cervical pneumorrhach. The patient presented complete spinal cord injury. It was handled conservatively, did not present cerebrospinal fluid fistula or neuroinfection (Figure 1).

Case report 2

A 28-year-old male patient, who presented during a fight, trauma with sharp object at the dorsal level. Presenting neurological deficit at the T6 sensitive level, with loss of sphincters and paraplegia that is interjected as a complete medullary section. CT scan of the cervical, dorsal and lumbar spine is evidenced by p Pneumorrhachis at T5 level (Figure 2). The patient did not improve clinically. Handled conservatively, without cerebrospinal fluid fistula. He was sent home at 20 days, continues to receive intensive rehabilitation.

Case report 3

A 40-year-old male patient with no morbid history. Presenting trauma in the lumbar region with forceful object, evaluated by neurosurgery, is performed lumbar CT scan that as a pathological finding was observed Lumbar spine CT scan showing evidence of Pneumorrhachis at the level of L3 (Figure 3). The patient was managed conservatively. He was sent home at 48 hours.

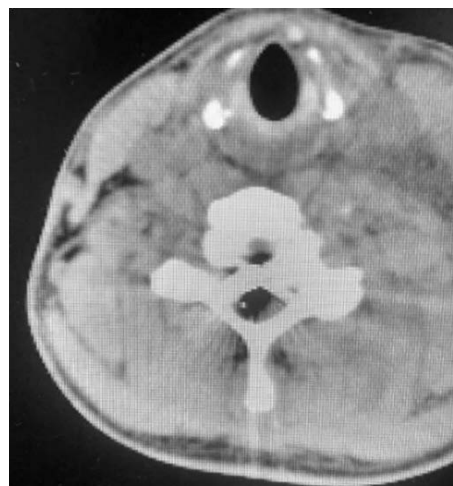

Figure 1 - Cervical spine CT scan showing Pneumorrhachis at the height of C7

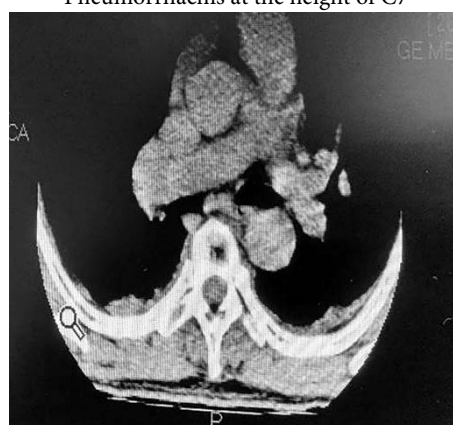

Figure 2 - Dorsal spine CT scan showing evidence of Pneumorrhachis at T5

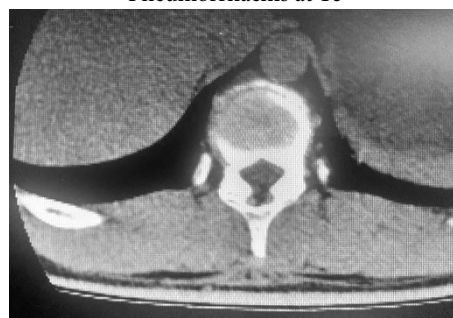

Figure 3 - Lumbar spine CT scan showing Pneumorrhachis at the height of L3

Discussion

The Pneumorrhachis - PR is a condition characterized by the presence of air in the spinal canal, either in the epidural, subdural or subarachnoid space. (3, 4) Initially it was described in 1977 by Gordon et al. Under various terms such as: intraspinal pneumocele, spinal, subdural or subarachnoid pneumatosis; Spinal and epidural emphysema, air myelogram, among others. (4, 5) But the term "Pneumorrhachis" was coined by Newbold et al. In 1987. (2, 6) This is classified as intradural and extradural considering the anatomical location of the air within the spinal canal. (2, 3, 5) Extradural PR is generally harmless, whereas intradural PR is associated with major trauma, and is considered a marker of serious injury. (3, 7)

Various conditions may directly or indirectly produce PR, including trauma, respiratory complications, factors that produce high intrathoracic pressure and barotraumas, or may occur spontaneously. In some cases, the conditions and lesions caused by PR are not detectable. (5, 8) Accordingly, PR can be etiologically classified as iatrogenic, non-traumatic, and traumatic. Among the causes for iatrogenic lesion are: surgical interventions, anesthetic and diagnostic techniques; Non-traumatic causes may include: violent coughing due to bronchial asthma or acute bronchitis, cardiopulmonary resuscitation, foreign body airway obstruction, physical exertion, or drug abuse by inhalation. (7) PR secondary to trauma is uncommon in the literature, and may occur due to causes such as: traumatic brain injury, cervical, thoracic, abdominal, and pelvic injuries and

may result from penetrating spinal cord injuries by a firearm or sharpener. (3, 7, 9)

Air can enter the spinal canal directly or indirectly, the first mainly of traumatic or penetrating origin; And the second by dissection of the soft paraspinals by a unidirectional valve mechanism until reaching the spinal canal. (4) Generally, this air within the cord does not migrate and is spontaneously reabsorbed into the bloodstream for several days without relapse. (3, 7) There have been reports of air bubbles isolated in the spinal canal, whose locations according to their frequencies are organized as follows: thoracic, cervical, lumbosacral, cervico-thoracic, cervico-lumbar and thoracolumbar regions. In the internal PR, this distribution may depend on the site of dissection, velocity, and air volume; On the other hand, in external PR, air is generally concentrated in the posterior epidural space. (5, 10) PR can be of primary or secondary origin, being associated with the presence of air distributed in other cavities such as: thorax, mediastinum, pericardium, subcutaneous tissue and intracranial cavity. (5, 7) In addition, for this classification, it is necessary to consider whether intraspinal air is the cause and the origin or result of the associated appearance of air in the body. (5)

Generally, PR is usually asymptomatic but rarely presents associated symptoms such as discomfort, pain and neurological deficiencies; In addition it can also produce meningism and alteration of consciousness (4, 5), which is why the diagnosis is mainly radiographic and not clinical. Among the most used tools we find: simple radiographic that is useful for the early detection of associated lesions and the

detection of large amounts of intraspinal air; Computed tomography (CT) is the tool of choice, but it is difficult to differentiate between intradural and extradural PR, which is why it is necessary to use magnetic resonance imaging. (4, 5) Adequate differentiation of the intraspinal air and spinal gases caused by degenerative, malignant, inflammatory and infectious diseases must be performed, since CT does not allow this differentiation to be made clearly, which is why this similarity must be considered in the differential diagnosis. (2, 5, 10) There is no specific treatment for the management of PR, this usually focuses on the associated lesions. Air as such is not usually dangerous, but its presence is fundamental to identify underlying pathologies. (4, 6, 11)

Classification proposal

Based on a literature review of available cases, we propose to classify PTSD in grades depending on their size on CT scans, in grades I, II and III. Grade I would be the PR which is located towards the periphery in the spinal canal and occupies no more than 30%, grade II occupying up to 60% and grade III occupying more than 60% (Figure 4). On the other hand, the PR will later be assigned to the anatomical region where it is identified.

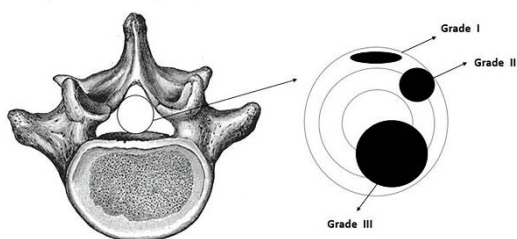


Figure 4 - Scheme of the proposal Classification
Moscote-Agrawal-Padilla

Conclusions

Post-traumatic PR is a rare condition but its timely diagnosis is important. Although RP is usually self-limited and without other therapeutic consequences, it is essential to define the cause and extent of the injury. In view of this, the treating specialist should thoroughly evaluate the pathologies that may cause the presence of air in the spinal canal to determine a suitable treatment for the patient.

Correspondence

Dr. Luis Rafael Moscote-Salazar
Universidad de Cartagena, Cartagena de Indias,
Colombia
E-mail: mineurocirujano@aol.com

References

- Gill M, Sreenivas M, Beniwal RS. Post-traumatic cervical pneumorrhachis - A rare entity. *British Journal of Neurosurgery*. 2011;251:134-5.
- El-Halabi D, Alkandari T, Yaktien MM. Traumatic air in spinal canal pneumorrhachis. *Anaesthesiology intensive therapy*. 2012;44:25-7.
- Kim KY, Kang JH, Lee MH, Han Y, Choi DW. Atypical traumatic pneumorrhachis accompanied by paraparesis. *Ann Rehabil Med*. 2014;383:410-4.
- Segura DS. Caso 3-2015: Masculino 19 años con neumorraquis post-traumático. *Revista Clínica de la Escuela de Medicina UCR - HSJD*. 2015;52:1-3.
- Oertel MF, Korinth MC, Reinges MHT, Krings T, Terbeck S, Gilsbach JM. Pathogenesis, diagnosis and management of pneumorrhachis. *Eur Spine J*. 2006;15Suppl 5:S636-43.
- Hadjigeorgiou GF, Singh R, Stefanopoulos P, Petsanas A, Hadjigeorgiou FG, Fountas K. Traumatic pneumorrhachis after isolated closed head injuries: An up-to-date review. *Journal of Clinical Neuroscience*. 2016;34:44-6.
- Gelalis ID, Karageorgos A, Arnaoutoglou C, Gartzonikas D, Politis A, Georgakopoulos N, et al. Traumatic pneumorrhachis: Etiology, pathomechanism, diagnosis, and treatment. *Spine Journal*. 2011;112:153-7.

8. Derner M, Drugová B, Hořejší L, Skvára D, Druga R. Massive pneumorrhachis, pneumocephalus and pneumoopticus following thoracic trauma and avulsion of the brachial plexus: case report and review of the literature. *Prague medical report*. 2011;1121:56–66.
9. Luh HT, Kuo MF, Lai DM, Chen CM, Xiao F, Yang SH. Traumatic pneumorrhachis associated with pulmonary herniation into spinal canal. *Spine Journal*. 2014;145:853–4.
10. Dwarakanath S, Banerji A, Chandramouli B. Posttraumatic intradural pneumorrhachis : A rare entity. *Indian Journal of Neurotrauma*. 2009;62:151–2.
11. McIntosh SE, Salcedo-Dovi H, Cortes V. Air in the spinal canal associated with trauma. *The Journal of Emergency Medicine*. 2006;311:33–5.