

Article

Broken lumbar pedicle screw – a short report

Ashish Kumar Dwivedi, Rashim Kataria, Virendra Deo Sinha
INDIA



DE GRUYTER
OPEN

Broken lumbar pedicle screw – a short report

Ashish Kumar Dwivedi¹, Rashim Kataria², Virendra Deo Sinha²

¹Department of Neurosurgery, K.E.M. Hospital Mumbai, Maharashtra, INDIA

²Department of Neurosurgery, S.M.S. Medical College and attached Hospital Jaipur, Rajasthan INDIA

Abstract: Spinal fixation is one of the common surgical procedure performed by spine surgeons. Among the various spinal fixation technique, pedicle screw fixation is of paramount importance especially when instability is in dorsolumbar and sacral region of spine. Like any surgical procedure, pedicle screw fixation is not devoid of complications. Broken pedicle screws are one of the rare complication of this procedure with a great challenge to deal with such situation. We are reporting one of the rare complication of pedicle screw fixation with literature review and our philosophy to deal such complication.

Introduction

Pedicle screw fixation is the recommended procedure with strong construct and higher rates of fusion. [1-6] Despite providing strong construct and higher rate of fusion, this procedure is not free of complications. [1-6] We are reporting a case of 38-year-old lady who underwent pedicle screw fixation for burst fracture of L2 vertebra two and half years back, now came to us with history of fall followed by implant breakage and wound dehiscence.

Case report

A 38-year-old female underwent pedicle screw fixation for L2 vertebral body fracture two and half year back. She was apparently well until 15 days back when she had fall from

height followed by wound dehiscence and severe pain over the operated site. On further examination broken implant was visible from wound dehiscence. There was no neurological deficit on examination. Removal of broken implant was planned. We have removed both the rod and few of the screws but some of screw were stuck in the body and could not be removed by any means, thus left as such. [Figures 1A and 1B]. Patient was free of operated site pain with no neurological deficit at 6-month follow-up.

Discussion

Of all the patient underwent pedicle screw fixation, 0.4-24.5% patient present with breakage of pedicle screws. [1,4] Incidence of breakage of pedicle screw is 1-11.2% of all the

inserted screws. [1,4]. Pseudo arthrosis may be possible cause of implant failure. [1] caudal screws are subjected to greater axial stress than those of cephalic one. [2] Fatigue striation and ductile fracture around the edges are the additional explanation for breakage of pedicle screw. [2] Removal of the broken implant is the treatment of choice in such cases. Removal of broken rods and broken heads of pedicles are usually achieved easily but removal of the broken pedicle screw is not always easy.

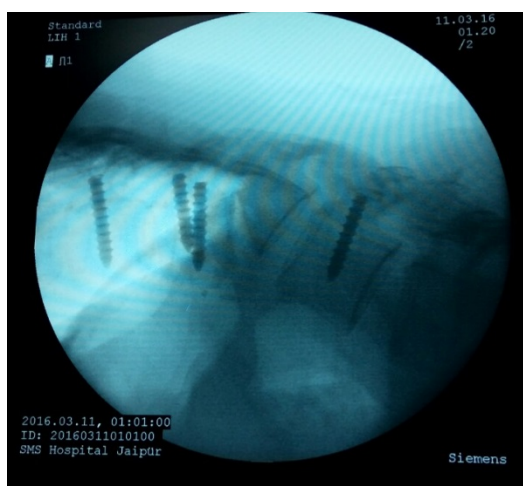


Figure 1A

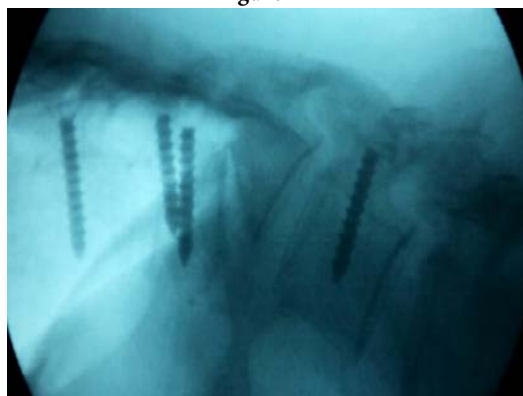


Figure 1B

Figure 1 - showing broken pedicle screws

Various techniques have been described to remove broken pedicle screws. Removal of pedicle screw by creating a deep pilot hole in the centre of the fractured screw and engaging the screw driver to reverse and rotate the screw counter-clockwise is described in literature. [7] Removal of broken pedicle screw is also possible by using a high-speed drill with a long bit and making a slot over the top surface of the broken screw to accommodate screwdriver. [4]

Drilling inside the broken screw is not an easy task and any additional effort can add to the possibility of moving the broken screw further deeper, which may result in devastating complication. [5] Although after removal of broken pedicle screw, larger diameter screw can be inserted but whether reinsertion is really needed if breakage of pedicle screws takes place years after the primary procedure, is the controversial. In our opinion spinal fusion is already complete by this prolonged duration and spine is stabilized, impacted broken pedicle screws can be left as such without any untoward sequelae.

Conclusion

Although there are various techniques which describe the method of removal of impacted broken pedicle screws, it is not always possible to remove the deeply impacted broken pedicle screws. In such condition, broken pedicle screws can be left in situ with no further complication if the fusion is adequate.

Correspondence

Dr Ashish Kumar Dwivedi

Senior Registrar, Department of Neurosurgery

K.E.M. Hospital Mumbai, Maharashtra, India

Email address- drashishkumardwivedi@gmail.com

Mobile number- 9610510564

References

1. Lonstein JE, Denis F, Perra JH, Pinto MR, Smith MD, Winter RB. Complications associated with pedicle screws. *J Bone Joint Surg (A)* 1999; 81:1519–1528. [PubMed]
2. Chen CS, Chen WJ, Cheng CK, Jao SH, Chueh SC, Wang CC. Failure analysis of broken pedicle screws on spinal instrumentation. *Medical engineering & physics*. 2005; 27:487–496. [PubMed]
3. Di Lorenzo N, Conti R, Romoli S. Retrieval of broken pedicle screws by "friction" technique. Technical note. *J Neurosurg*. 2000; 92:114–116. [PubMed]
4. Duncan JD, MacDonald JD. Extraction of broken pedicle screws: technical note. *Neurosurg*. 1998; 42:1399–1400. [PubMed]
5. Kaya AH, Dagcinar A, Celik F, Senel A. Simple technique for removing broken pedicular screw with plain and serviceable screwdriver. *Eur Spine J*. 2008;17:1116–1118. [PMC free article] [PubMed]
6. Agrawal A. Simple technique for removing broken pedicular screws. *Malays Orthop J*. 2014 Mar; 8(1):66-67.
7. McGuire RA Jr. A method for removal of broken vertebral screws. *Orthop review*. 1992; 21:775–776. [PubMed]