



Current applications of 3d printing in neurosurgery

A. Chiriac¹, A. Iencean¹, Georgiana Ion¹, G. Stan²,
S. Munteanu³, I. Poeata¹

¹ "Gr. T. Popa" University of Medicine and Pharmacy, Iasi, ROMANIA

² National Institute of Materials Physics, Bucharest-Magurele, ROMANIA

³ Transilvania University of Brasov, ROMANIA

ABSTRACT

Medical implications of 3-dimensional (3D) printing technology have progressed with increasingly used especially in surgical fields. 3D printing techniques are practical and anatomically accurate methods of producing patient specific models for medical education, surgical planning, training and simulation, and implants production for the assessment and treatment of neurosurgical diseases. This article presents the main directions of 3D printing models application in neurosurgery.

INTRODUCTION

Since its initial appearance in the 1980s, three-dimensional (3D) printing has revolutionized the practice of rapid prototyping in many areas, such as design, engineering and medicine. This technique consists in the manufacture of 3D physical models, based on computer models, by depositing successive layers of material in the underlying structure to build 3D objects. [1,3,5] Modelling by 3D printing uses either a thermoplastic material that hardens after it has been heated during extrusion, or uses a low power ultraviolet (UV) laser to solidify a liquid photosensitive polymer in the case of stereolithography. The development of this technique has allowed the elimination of intermediate stages of product development allowing a cheap and rapid transition of concepts into prototypes or finished products.

The numerous innovations in the field of technology and materials of the last decade have allowed improving the precision level of the printed objects and have increased the range of printable materials. Thus, the applications of 3D printing technology have expanded greatly in the medical and biomedical fields. Applications in clinical medicine appear especially in maxillofacial reconstructions, neurosurgery and spinal surgery. The ability of 3D printing to produce individualized models, devices and implants has greatly contributed to the development of so-called "personalized medicine". In addition, the proven utility in surgical planning and simulation, assisting in the consent process and use as an educational tool have significantly marked the role of 3D printing in medicine [2,4,6].

Keywords

3D printing,
neurosurgery,
3D models



Corresponding author:
A. Chiriac

"Gr. T. Popa" University of Medicine
and Pharmacy, Iasi, Romania

chiriac_a@hotmail.com

Copyright and usage. This is an Open Access article, distributed under the terms of the Creative Commons Attribution Non-Commercial No Derivatives License (<https://creativecommons.org/licenses/by-nc-nd/4.0/>) which permits non-commercial re-use, distribution, and reproduction in any medium, provided the original work is unaltered and is properly cited.

The written permission of the Romanian Society of Neurosurgery must be obtained for commercial re-use or in order to create a derivative work.

ISSN online 2344-4959
© Romanian Society of
Neurosurgery



First published
December 2019 by
London Academic Publishing
www.lapub.co.uk

3D PRINTING EVOLUTION IN NEUROSURGERY

In the field of neurosurgery, the 3D printing technique has made substantial progress since 2007 as a result of the development of cranioplasty techniques that required the implementation of implants with increasingly complex anatomical configurations. Initially, the evolution of this technique was limited as the commercially available printers were still in the beginning and allowed printing only in one material and density. Subsequently, 3D printing has progressed, following the success of making models with as accurate spatial representations of the patient's anatomy. Thus, with the development in 2012 of printers with the possibility of printing in several materials and densities (Shore value), the technique of 3D printing in neurosurgery has developed in several main directions: - development of anatomical models specific to the patient for surgical planning; - vocational training and education; - design of neurosurgical devices for the evaluation and treatment of neurosurgical diseases; - and not least, the development of biological tissue implants. In this article, we will review the achievements of 3D printing in every direction in the neurosurgery field to evaluate the usefulness of final products, the challenges encountered and the progress of the field [1,5,7].

CRANIOPLASTY (RECONSTRUCTION OF SKULL DEFECTS)

Cranioplasty is one of the oldest neurosurgical procedures, practiced since 3000 BC. The most common defects of the skull can appear after trauma, neurosurgical procedures such as decompressive craniotomy, tumor resections with bone invasion, infections and congenital defects. The purpose of the cranial repair is to protect the underlying brain tissue, to reduce the local pain, to restore the patient's psychological balance by improving the cranial aesthetics.

The materials used initially in the cranioplasty procedure were pieces of autologous bone, polymeric, ceramic and metallic biomaterials. These autologous bones represented by the autologous calvarial bone removed from the patient during the initial operation had long-term problems, including subsidence, disintegration and infection. Thus, in a large number of patients, these plates disintegrated following their re-implantation, creating large defects, often accompanied by pain at the edges of

the disintegrated defect. Subsequently, autologous bones were excluded and various acrylic or metal-based materials became increasingly used in cranial reconstructions. One of the disadvantages of these materials is the need to model them *in situ* during the operation, usually manually or with minimal equipment. These had to be cut and bent to fit, often reaching with sharp edges that represented a risk to both the surgeon and the patient's overlapping skin. All of these resulted in an extension of the intervention time and also created a number of problems, including poor match and unsatisfactory cosmetic result.

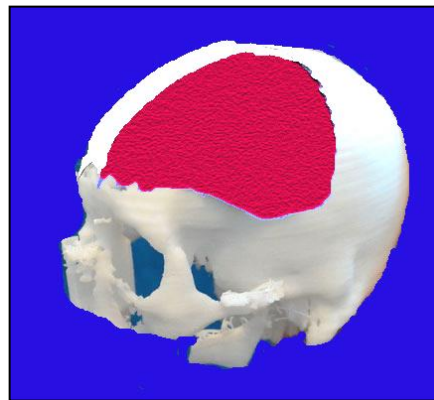


Figure 1: PMMA reconstruction on 3D printed model

With the advent of 3D printing, most of the problems mentioned above have managed to be overcome. Initially the 3D printing method was used to create a mould model on which the reconstruction joints are prefabricated. Also, another approach consisted in the initial creation of some models in the corrected form, and the titanium plates were subsequently modelled to suit the defect based on reconstruction. Implants thus reconstructed were then tested on the 3D printed model of the defect before sterilization and surgery. In addition to titanium, other materials such as acrylic (PMMA) and PEEK (polyether ether ketone) have also been used to create implants using similar techniques (figure 1). The use of these materials allowed the creation of a personalized prosthesis using 3D printing moulds characterized by an excellent cranial contour. Using the standard printing method described above, it was possible to avoid the possibility of deterioration of adjacent tissues due to the exothermic reaction during the polymerization process. Thus, intraoperative

modelling of the final implant can be performed in just a few minutes [1,6,7,8,9].

The introduction of the 3D printing technique by the continuous multilayer deposition method in obtaining the cranioplasty implants determined the elimination of the intraoperative manipulation through cutting and modeling.

As the geometry of the facial bones and skull is extremely complex and most of these defects primarily involve underlying bone structures, the application of this more advanced 3D printing technology has proven ideal.

NEUROSURGICAL TRAINING

Surgical training is usually a multi-step process by which the trainee acquires knowledge and skills of practicing surgical procedures. Thus, as the trainee gains skills, he will be able to progress to more complex steps and be given more autonomy. The effectiveness of this learning model can be influenced by the existence of the teaching material (most often represented by the availability of corpses), the number of cases and the interval of pathology related to a certain surgical unit. 3D printing offers solutions to bypass some of these problems and improve the internship experience. The trainees can practice and master the individual operative steps on the models before practicing with a real patient. This can improve learner confidence (especially in cases involving a difficult or unusual anatomy) and can help speed up the training timeline, as skill acquisition is achieved concomitantly with the actual operating experience of the patient. Also, the use of 3D printed models in vocational training helps surgical educators standardize the acquisition of operator skills among trainees. 3D printing thus offers a number of advantages, which allow it to be a useful adjunct to existing surgical simulation methods, such as cadaveric dissection and virtual reality techniques [1,2,4,7,9].

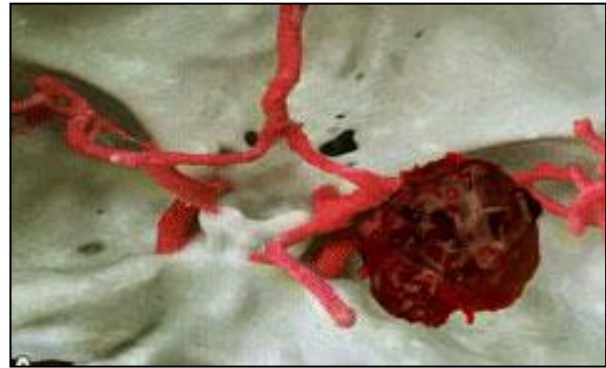



Figure 2: 3D printed models for vascular aneurysm and sphenoid wings tumour intervention training.

The main directions of neurosurgical pathology that have benefited from the advantages of 3D printing have been the provocative anatomy lesions, such as cerebral vascular malformations of the aneurysm or MAV, brain tumors, and techniques such as ventricular or transnasal endoscopy, which involve visualization constraints. One area where learning has generally been limited in the operating room is aneurysmal clipping. With the large-scale introduction of the treatment of aneurysms by coil embolization and the lack of cadaveric tissue, simulation-based training has become an absolute must in the strategy of vascular neurosurgery training. Mashiko et al. using hollow elastic replicas of the different aneurysms from their vascular networks in a 3D printed model, they offered young neurosurgeons the opportunity to gain experience in selecting the appropriate clip, understanding the shape of the aneurysm and the direction of the clip [1,3,10].

Similar to the field of vascular neurosurgery, the surgical training for excision of brain tumors has included the use of simulators based on anatomical models obtained by 3D printing (Figure 2). Thus, the use of 3D printers has allowed the development of simulators created from a multitude of materials with different consistencies and densities. This achievement contributed to the improvement of the simulation by replicating the handling characteristics of the different types of tissues [1,2,3,4].

It is very well known the absolute necessity of the surgical training in the case of spinal pathology, especially due to the multitude of types of implants proposed at present by the specialized companies. The continuous evolution of the spinal implants correlated with the development of the

instrumentation specific to each type made the introduction of 3D printed models inevitable in this area. Thus, the need for training for specialists in spinal neurosurgery aimed at acquiring the skills of use for various types of implants and instrumentation has greatly increased the use of these 3D printed models and due to the impossibility of access to such a large number of anatomical biological structures.

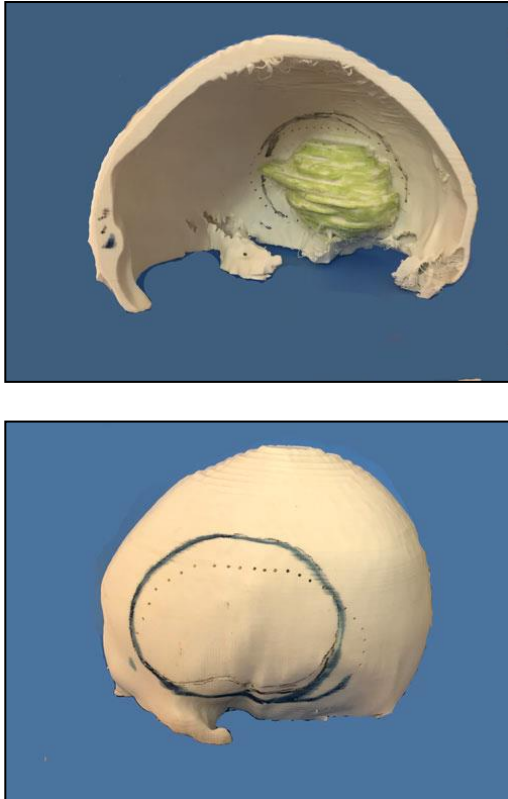


Figure 3: 3D printed models for a meningioma approach training.

PLANNING IN NEUROSURGICAL PATHOLOGY

Surgical intervention for intracranial aneurysm requires a complete and clear understanding of the complex 3D structure of the aneurysms and individual relationships with the carrier vessels and adjacent branches, in addition to accurate knowledge of the surrounding anatomical structures. Despite the evolution of 3D imaging acquisitions and processing (3D-CTA or 3D-DSA), the visualization and analysis of aneurysmal and MAV lesions by neurosurgeons are paradoxically deprived of a flat-screen 2D computer, making depth interpretations difficult. With the advent of 3D printing, this approach has become a feasible option,

which has allowed faithful 3D physical reproduction of the vascular networks of an individual patient [Figure 1]. Thus, these physical models that can be viewed from any angle and correctly appreciated dimensionally represent a potentially more advantageous method. Studies in the literature comprising both qualitative and quantitative evaluations did not show significant dimensional differences between the imaging acquisitions and the printed model, proving the usefulness of using this printing technique. Most of the discrepancies reported were the result of the residual support material from the lumen of the vessels. Namba et al. reported for the first time the possibility of using these 3D printed models for endovascular planning (choosing the shape of the microcatheter and the coils occlusion).



Figure 4: 3D printed models for a calvarial tumour planning approach.

Surgical planning in the resection of brain tumours mainly involves the use of MRI imaging. Even with the advantages offered by this imaging technique, the relationships between the tumour formation and the

adjacent anatomical elements are difficult to appreciate especially in the case of infiltrative ones. 3D printing technology has allowed the translation of MRI imaging data into patient-specific models that show the associations between tumour, skull, vascularisation and non-pathologic brain tissue [Figure 4]. [5] Moreover, the use of functional MRI imaging allowed a much more precise surgical planning through a clear demarcation of the areas of eloquent cortex that needed to be avoided in microsurgical resection manoeuvres. Large complex models of skull and brain tissue based on MRI could also be used for surgical planning in the case of transnational or transventricular endoscopic approaches. In addition, these models can be used in the planning and development of new treatments for brain tumours such as noninvasive thermocoagulation [1,10].

The identification and understanding of the anatomy in the case of spinal fractures is a fundamental component for the surgical treatment.

CT and MRI imaging techniques, although, allow a good visualization of the anatomical elements or proved insufficient as regards the spinal interventional planning. This is reinforced by the development of intraoperative referral procedures used in spinal neurosurgery. Numerous specialized studies have shown that 3D printed representations of these pathological situations at the spine level are extremely efficient in choosing fixation and prosthesis systems, but also in exercise in implanting them especially in the case of minimally invasive percutaneous interventions. Thus, the detailed visual analysis of these 3D printed models allows a much clearer and more accurate dimensional and conformational assessment of the anatomical situation. This technique will allow neurosurgeons to establish some more precise dimensional parameters of the surgical implant insertion trajectory that can be transferred to the intraoperative guidance systems (Figure 5).

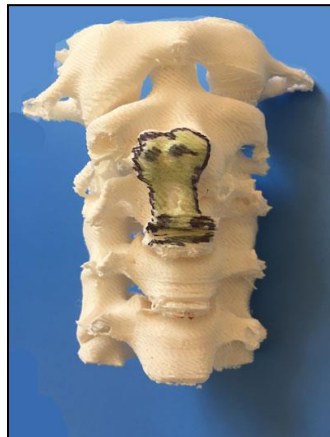
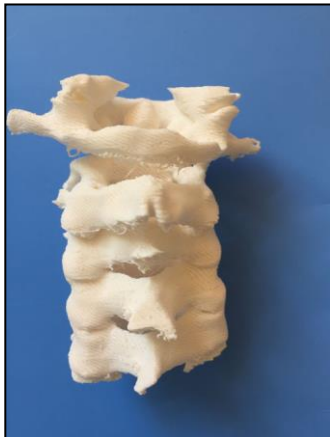
Figure 5: 3D printed models for cervical spine planning approach.

ASSISTING IN THE CONSENT PROCESS

Any medical procedure requires informed consent that involves a direct communication between the doctor, the patient and his family regarding the patient's condition, the treatment possibilities, along with its advantages and disadvantages, the consequences of the non-treatment, as well as the risks and complications of each form of therapy. [1,7]. Statistical studies have shown that each step of informed consent can be better explained and understood through the use of a tangible object, in other words by materializing an abstract concept.



Figure 6: Spine 3D printed model for assisting in the consent process.

The use of 3D printed models proved to be very useful in the patient's consent procedure by considerably improving the discussions with them, due to the much clearer explanations of the proposed pathology and interventions. Thus, physicians can use customized physical models with *in situ* pathology for each individual patient. The stages of the surgery as well as the possible specific complications are much better explained to the nonmedical staff through physical models. Also, these 3D printed models help to better understand the disease and the results of the treatment, thus reducing the patient's uncertainty about the medical act, preventing complaints, discontents and accusations of malpractice (Figure 6) [7,8].

MEDICAL EDUCATION

The use of 3D printed models has proven to be an extremely useful teaching tool for both students in the anatomy discipline, and surgical disciplines as well as for residents in the neurosurgery specialty. 3D printing techniques offer significant advantages in the process of medical education within the university and postgraduate programs, compared to the existing methods of anatomical modelling, which include cadaveric dissection, plastic models and plastinated corpus specimens. Although traditionally medical education in the field of anatomy and surgery was provided primarily by cadaveric dissection, this learning mode was associated with difficulties related to the costs of setting up and maintaining an anatomical dissection laboratory, the existence of a sufficient number of bodies for educational programs, safety issues for students and staff, and last but not least ethical issues with the use of cadaveric material.

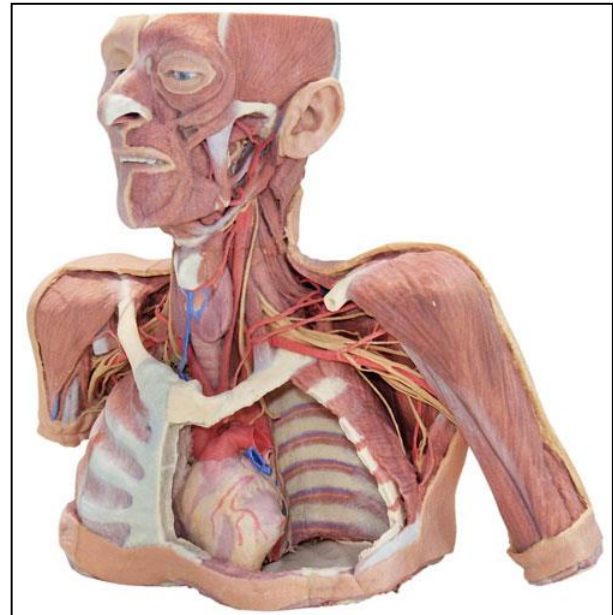



Figure 7: 3D printed models for student medical education [10].

The use of plastic models as an adjunct to cadaveric dissection to demonstrate certain organs or skeletal anatomy is limited by their lack of anatomical realism and the lack of representation of the variation or pathology specific to the patient. In contrast, 3D printing techniques allow the production of precise models characterized by a great variability and particular anatomical normality, but also pathological. Unlike plastination, which presents the major disadvantage of the resources required to create anatomical models, 3D printing does not limit the amount of 3D printed models produced, depending on the number of original copies (Figure 7).

Studies published in the literature have already shown improvements in the scores of anatomy tests of medical students after using 3D printing in the learning process. Thus, 3D printed models offer viable solutions for the vast majority of the difficulties faced by educators using more traditional training methods [1,5,10].

CONCLUSIONS

The technique of 3D printing has undergone a remarkable development and use in the field of neurosurgery in the last decade. The possibility offered by this rapid prototyping technology provides a practical and anatomically precise means of producing patient-specific and disease-specific

models. Besides applications already known in the fields of education and anatomical modelling, surgical planning, simulation and training, the creation of personalized implants for the treatment of various neurosurgical pathologies represents the real challenge of these technologies. Thus, extending this technology in neurosurgery will serve both medical students and interventionist, but especially to patients.

This study about 3D printing applications in neurosurgery is the subject of the grant: "New diagnostic and treatment methodologies: current challenges and technological solutions based on nanoparticles and biomaterials", that won the 2017 complex projects completed in consortia CDI, grant number: PN-III-P1-1.2-PCCDI-2017-0062, funded by CNCS – UEFISCDI Romania.

REFERENCES

1. Baskaran, V., Štrkalj, G., Štrkalj, M., & Di Ieva, A. (2016). Current applications and future perspectives of the use of 3D printing in anatomical training and neurosurgery. *Frontiers in neuroanatomy*, 10, 69.
2. Klein, G. T., Lu, Y., & Wang, M. Y. (2013). 3D printing and neurosurgery--ready for prime time?. *World neurosurgery*, 80(3-4), 233-235.
3. Ploch, C. C., Mansi, C. S., Jayamohan, J., & Kuhl, E. (2016). Using 3D printing to create personalized brain models for neurosurgical training and preoperative planning. *World neurosurgery*, 90, 668-674.
4. Pucci, J. U., Christophe, B. R., Sisti, J. A., & Connolly Jr, E. S. (2017). Three-dimensional printing: technologies, applications, and limitations in neurosurgery. *Biotechnology Advances*, 35(5), 521-529.
5. Randazzo, M., Pisapia, J. M., Singh, N., & Thawani, J. P. (2016). 3D printing in neurosurgery: a systematic review. *Surgical Neurology International*, 7(Suppl 33), S801.
6. Rybicki, F. J., & Grant, G. T. (2017). *3D Printing in Medicine*. Cham: Springer International Publishing.
7. Tevanov, L., Liciu, E., Chirila, M. O., Dusca, A., & Ulici, A. (2017). The use of 3D printing in improving patient-doctor relationship and malpractice prevention. *Rom J Leg Med*, 25(3).
8. Tomasello, F., Conti, A., & La Torre, D. (2016). 3D printing in Neurosurgery.
9. Vakharia, V. N., Vakharia, N. N., & Hill, C. S. (2016). Review of 3-dimensional printing on cranial neurosurgery simulation training. *World neurosurgery*, 88, 188-198.
10. Waran, V., Narayanan, V., Karrupiah, R., & Cham, C. Y. (2017). 3D Printing in Neurosurgery. In *3D Printing in Medicine* (pp. 51-58). Springer, Cham.
11. <https://anatomywarehouse.com/3d-printed-head-neck-and-shoulder-with-angiosomes-a-105328>.