

ROMANIAN  
NEUROSURGERY

Vol. XXXIV | No. 1      March 2020

Surgical challenges and outcome of  
endoscopic endonasal approaches in the  
management of recurrent pituitary  
adenomas

Ahmed Nageeb Mohamed Taha,  
Hosam Shata Mohamed,  
Mahmoud Saad Mohamed



# Surgical challenges and outcome of endoscopic endonasal approaches in the management of recurrent pituitary adenomas

Ahmed Nageeb Mohamed Taha, Hosam Shata Mohamed, Mahmoud Saad Mohamed

Neurosurgery Department, Mansoura College of Medicine, Mansoura University, EGYPT

## ABSTRACT

**Background:** Various surgical approaches for the management of midline anterior skull base meningiomas exist in the literature. The main surgeon target is proper selection the appropriate approach that achieves total removal of the lesion without causing morbidity or mortality and facilitates safe effective removal of the tumor.

**Objectives:** To evaluate the role of the extended pterional approach for excision of midline anterior skull base meningiomas as regard the effectiveness, extent of resection and surgical outcome.

**Patients and methods:** This retrospective study involved 23 cases with midline anterior skull base meningiomas resected through the extended pterional approach. Patients' clinical data, operative notes, imaging studies and clinical follow-up data were analyzed and evaluated.

**Results:** Tumors studied were 9 olfactory groove meningiomas, 8 tuberculum Sellae meningiomas, 4 planum sphenoidale meningiomas and 2 diaphragma sellae meningiomas. Gross total resection tumor excision in 15 cases (64.5%), subtotal excision in 5 cases (21.5%) and partial excision in 3 cases (14%). Complications were diabetes insipidus (2 cases 8.6%), CSF rhinorrhea (3 cases 12.9%) and visual deterioration (3 cases 12.9%). We had two cases of mortality.

**Conclusion:** The extended pterional approach allows safe and effective removal of midline anterior skull base meningiomas. It expands the exposure offered by the classic pterional approach and minimizing the necessity for applying fixed brain retraction with good cosmetic outcome and less approach related morbidities in comparison with the extensive skull base approaches.

## INTRODUCTION

Pituitary adenomas are relatively common brain tumor with benign features, and, in fact, they are found in 10%-17% of the general population. Surgical resection continues to be the preferred treatment except for prolactin-secreting tumors. The nature of the pituitary adenoma itself suggests the possibility of tumor recurrence, regardless of its endocrinological characteristics. Recurrence rate

## Keywords

extended pterional,  
meningioma,  
skull base,  
extent of resection



Corresponding author:  
Mahmoud Saad Mohamed

Neurosurgery Department,  
Mansoura Collage of Medicine,  
Mansoura University, Egypt

dr\_mhmodsaad@yahoo.com

**Copyright and usage.** This is an Open Access article, distributed under the terms of the Creative Commons Attribution Non-Commercial No Derivatives License (<https://creativecommons.org/licenses/by-nc-nd/4.0/>) which permits non-commercial re-use, distribution, and reproduction in any medium, provided the original work is unaltered and is properly cited.

The written permission of the Romanian Society of Neurosurgery must be obtained for commercial re-use or in order to create a derivative work.

ISSN online 2344-4959  
© Romanian Society of  
Neurosurgery



First published  
March 2020 by  
London Academic Publishing  
[www.lapub.co.uk](http://www.lapub.co.uk)

of pituitary adenoma after surgical resection has been reported up to 30%, and regrowth after incomplete tumor removal was reported in up to 75% of cases (2,5,10,12,16).

Recurrent tumors can be managed with observation, medical therapy, radiotherapy, radiosurgery, or revision surgery. Additionally, the combined treatment paradigm is essential in some cases because all treatment modalities have advantages and disadvantages. Surgery for a recurrent lesion is burdened by increased risk of mortality and morbidity, and it often results in incomplete resection compared with initial surgery. Radiosurgery and stereotactic radiotherapy can be recommended as adjuvant treatments to obtain long-term control with low procedure-related morbidity in selective cases. However, the repeated surgical resection is crucial in cases of sizable adenomas compressing the optic apparatus, or hormone-secreting adenomas (1,2,3,4,7,9,14).

Nearly a century ago, Harvey Cushing realized the limitations of microsurgical approaches for treating pituitary adenomas. Cushing and his colleagues used a radium bomb to deliver a single-session, focused radiation to treat pituitary adenomas. Henceforth, neurosurgeons and radiation oncologists have employed repeat resection or ionizing radiation to treat selected patients with recurrent or residual pituitary adenomas (1,6,22,24).

During the last century, pituitary surgery has been developed with various technical modifications and instrumental advances, and the outcome has been generally excellent, with high rates of clinical improvement and endocrinological remission and minimal rates of morbidity and mortality. The introduction of endoscopy in the transsphenoidal approach (TSA) has tremendously advanced the midline skull base surgery. In the literatures, the efficacy and safety of endoscopic TSA in the management of pituitary adenomas have been proven and the complication rates of endoscopic TSA are at least comparable with those of microscopic series. However, the reports on endoscopic TSA as a revision surgery have been less commonly published (6,8,11,13,15,19,26,28).

We retrospectively evaluated the efficacy and safety of the endoscopic TSA for recurrent pituitary adenomas as regard extent of resection, ICA injury and CSF leakage and related reconstruction obstacles.

## MATERIAL AND METHODS

A retrospective study is conducted on 30 patients with recurrent pituitary adenomas that were re-operated up on via endoscopic endonasal transsphenoidal approach at the Neurosurgery Department, Mansoura University over the period from 2013 to 2019. Patients who did a previous transsphenoid either via microscopic or endoscopic technique are included in the study. The indications to do another endoscopic endonasal transsphenoidal approach were big residual or recurrent tumor compressing the chiasm, persistent endocrinological problem due to residual adenoma. Patient demographic and previous surgery data were collected and analyzed including any previous medical treatment, radiation treatment and any previous surgery related morbidities. Routine pre-operative complete ophthalmological assessment was done for all cases and was repeated after surgery to assess the outcome. Pre- and postoperative endocrinological assessment were done for all cases including serum prolactin, free cortisol, ACTH, free thyroxine, TSH, GH and insulin-like growth factor 1 (IGF-1). Serum electrolytes and fluid chart were done for all cases with diabetes insipidus that present either prior or after the surgery. Pre-operative contrast-enhanced MRI were done for all the patients and then 3 months after surgery and then yearly for follow up. The tumors were assessed regarding its size and extension. Tumor volumes were assessed by the ellipsoid model "(ABC)/2" equation. The degree of cavernous sinus invasion was evaluated based on Knosp criteria. The extent of tumor resection (EOR) was assessed based on a post-contrast MRI study done 3 months after surgery.

## SURGICAL TECHNIQUE

We utilize the standard endoscopic approach for pituitary adenoma surgery which is widely described in the literature, and we will stress on our steps in relation to surgery for recurrent cases. Lumbar drain was utilized for cases with history of previous CSF rhinorrhea with the initial surgery and for cases we have encountered intra-operative CSF leakage and was left for 1 to 3 postoperative days for postoperative drainage. The important steps to ensure efficient safe surgery for recurrent cases were binostrial four handed endoscopic technique with wide sphenoidotomy and obtaining adequate

sellar exposure to have the full panoramic view of the carotid prominences, medial and lateral optico-carotid recesses, planum and clivus. Our biggest challenge was the way to achieve adequate reconstruction after tumor resection. Options were reusing prior flap from the previous surgery, obtaining a contralateral nasoseptal flap but in many cases with extensive adhesions and disturbed normal anatomy especially those previously irradiated; abdominal fat graft or fascia lata graft was utilized to achieve sellar reconstruction.

## RESULTS

Thirty patients involved in this study were operated up on via endoscopic endonasal transsphenoidal surgery for recurrent or residual pituitary adenomas. 18 were females and 12 were males. Age ranged from 29 to 61 years (mean 50 years). Twenty-four patients (80%) had single prior endoscopic endonasal transsphenoidal surgery. The remaining 6 patients (20%) had 2 previous transsphenoidal surgeries. In 23 patients; the initial surgery was done at Neurosurgery Department, Mansoura University Hospitals while the remaining seven cases were previously operated up on in other hospitals. The initial surgery was done microscopically in 13 cases while the other 17 cases were operated up on via the endoscopic approach (table 1).

The mean interval between the previous surgery and the redo endoscopic endonasal surgery was 30 months (ranged from 19 months to 42 months). 19 patients (63.3%) presented with tumor growth on follow up MRI brain before the onset of clinical symptoms and were re-operated upon because of growth of the residual tumor or persistent symptoms related to a persistent hormone hypersecretion. In 11 patients (36.6%); the tumor recurred after previous total resection documented on postoperative MRI brain. 21 patients (70%) had macro-adenomas at recurrence while the remaining nine patients (30%) had giant adenomas.

The clinical presentation was visual affection in 9 patients (30%), headache in 3 patients (10%), amenorrhea galactorrhea in 5 patients (16.6%) and persistent acromegalic features in 8 patients (26.6%). Only 4 patients received adjuvant radiotherapy following first surgery (table 1). 17 patients (56.6%) had nonfunctional pituitary adenomas. 8 patients (26.6%) had GH adenomas and 5 patients (16.6%) had a prolactinoma. Tumor

locations varies at time of presentation and determined radiologically with contrast enhanced MRI brain and distributed into: confined to sella in 7 cases (23.3%), sellar with suprasellar extension in 12 cases (40%), sellar with parasellar extension in 6 cases (20%) and sellar, suprasellar and parasellar extension in 5 cases (16.6%) (table 2).

Overall Gross total resection was achieved in 17 patients (56.6%) while subtotal and partial resection in 13 patients (43.4%) confirmed by Gadolinium enhanced magnetic resonance imaging of the brain done 3 months after surgery (table 3). Total resection was achieved in 11 cases of non-functioning adenoma, 3 cases of growth hormone secreting adenomas and 3 cases of prolactinomas. Total resection was achieved in 9 (47.3%) residual adenomas and in 8 (72.7%) recurrent adenomas. According to the tumor extension; total resection was feasible in 5 out of 6 (83.3%) cases where the tumor is confined to sellae, in 10 out of 12 (83.3%) cases where is tumor is sellar and suprasellar extension and in 1 out of 11 (9.09%) of cases that had parasellar extension into the cavernous sinus. Subtotal resection was done in 6 cases of non-functioning adenoma, 5 cases of growth hormone secreting adenomas and 2 cases of prolactinomas. Subtotal resection was achieved in 10 (52.6%) residual adenomas and in 3 (27.2%) recurrent adenomas. According to the tumor extension; subtotal resection was done in 1 out of 6 (16.6%) cases where the tumor is confined to sellae, in 2 out of 12 (16.6%) cases where is tumor is sellar and suprasellar extension and in 10 out of 11 (90.9%) of cases that had parasellar extension into the cavernous sinus (table 3).

No further treatment was required for the 17 cases with total tumor resection. Among 6 cases of non-functioning adenoma with incomplete resection; 4 cases were done via microscopic transcranial approach and 2 of them offered 3-dimensional radiotherapy after the transcranial surgery while the other 2 cases were treated with gamma knife radiosurgery. We have 5 cases of acromegaly with incomplete resection; one was offered additional microscopic transcranial approach followed by conformal radiotherapy, 3 offered Gamma knife radiosurgery and one died from ruptured carotid pseudoaneurysm from intra-operative vascular injury. 2 cases of residual prolactin secreting adenomas were treated

medically with dopamine agonists and one of them received conformal radiotherapy after failed trail of medical treatment.

We have a case of mortality from carotid injury in a case of recurrent growth hormone secreting adenoma. 3 cases had post-operative CSF rhinorrhea; 2 passed conservatively and one required another endoscopic repair. 4 cases developed post-operative diabetes insipidus (2 required permanent treatments). 3 cases developed post-operative hypopituitarism requiring long term hormonal replacement therapy. Improvement of the visual manifestations occurred in 5 (55.5%) out of the 9 cases presented with visual affection regarding visual acuity and visual field disturbances (table 4). Regression of acromegalic features and normalization of growth hormone and insulin-like growth factor occurred in 3 (37.5%) out of 8 acromegalic cases while the other 5 (62.5%) cases failed to improve necessitating further treatment to control endocrinological problem. Restoration of normal menstrual cycle and cessation of galactorrhea occurred in 3 cases after total tumor removal while the other 2 cases with residual tumor were kept on medical treatment and one case received radiotherapy.

**Table 1.** Clinical and demographic distribution of recurrent adenoma patients

Feature	Number (%)
<b>Gender:</b>	
Male	12 (40%)
Female	18 (60%)
<b>Pathology:</b>	
Nonfunctioning	17 (56.6%)
GH producing	8(26.6%)
Prolactinoma	5 (16.6%)
<b>Number of previous surgeries:</b>	
1	24 (80%)
2	6 (20%)
<b>Previous resection:</b>	
Recurrent tumor	11 (36.6%)
Residual tumor	19 (63.3%)
<b>Clinical presentation:</b>	
Tumor regrowth (MRI)	14 (46.6%)
Visual	9(30%)
Acromegaly	8 (26.6%)
Headache	3 (10%)
Amenorrhea galactorhea	5 (16.6%)

## ILLUSTRATED CASES

**Case 1:** Forty-two years old male patient with recurrent non-functioning pituitary adenoma (fig. 1 a & b) with visual compression totally resected (fig. 1 c & d) with marvelous visual improvement.

**Case 2:** Fifty-four years old female patient with recurrent growth hormone secreting adenoma with visual compression (fig. 2 a & b); subtotal resection due to cavernous sinus invasion with good optic apparatus decompression (fig. 2 c & d) and followed by Gamma knife radiosurgery.

## DISCUSSION

Recurrent or residual pituitary adenomas after transsphenoid approach whether done microscopically or endoscopically represent a potential challenge in deciding the best appropriate treatment. Many options of treatment are available including just follow up, medical treatment for some functioning adenoma, radiotherapy including gamma knife, microscopic transcranial resection and repeat the transsphenoid approach. The decision is based up many factors including size of the residual or recurrent adenomas, pattern of the tumor extension, nature and function of the adenoma, clinical presentation and data regarding previous operation, surgery related morbidities and if any adjuvant treatment was given after the initial surgery (1,3,8,21,23,25,29).

Tumor extension	Total	Residual adenoma	Recurrent adenoma
Sellar	7	2	5
Sellar& suprasellar	12	6	6
Sellar&parasellar	6	6	0
Sellar&suprasellar& parasellar	5	5	0

**Table 2.** Pattern of tumor extension

Extent of previous resection	Number of cases	Gross total resection	Tumor extension
Residual tumor	19	9 (30%)	2 sellar, 6 sellar & supra sellar, 1 sellar & parasellar
Recurrent tumor	11	8 (26.6%)	4 sellar, 4 sellar & suprasellar

**Table 3.** Pattern of tumor extension Extent of tumor resection correlated to pattern of tumor extension

**Table 4.** Outcome of surgery of recurrent pituitary adenomas correlated to literature reports

series	No. of cases	EOR (No. of cases, %)		No. of cases, % of cases				Other complications
		GTR	STR	Complications	Hypopit.	DI	CSF leak	
Curent study	30	17, 56.6%	13, 43.4%	8, 26.6%	0	4, 13.3%	3, 10%	Mortality: 1 (carotid injury)
Negm et al. 2017	41	24, 55.5%	2, 4.9%	8, 19.5%	4, 9.7%	2, 4.9%	1, 2.4%	Hematoma: 1 (2.4%)
Wang et al. 2015	29	16, 55%	11, 38%	5, 17%	0	1, 3.4%	1, 3.4%	2 (6.9%) cases of deterioration of vision due to hemorrhage in tumor bed & intracranially; 6 <sup>th</sup> nerve palsy: 1 (3.4%)
Tajudeen et al. 2015	27	17, 63%	7, 26%	6, 22%	1, 3.7%	2, 7.4%	0	Abducent palsy: 1 (3.7%)
Cavallo et al. 2012	59	37, 63%	9, 15%	8, 13.5%	4, 6.7%	3 (5%)	1 (1.7%)†	Hematoma: 1 (1.7%)
Rudnik et al. 2006	20	8, 40%	0	4, 20%	3, 15%	0	1, 5%	
Hwang et al. 2013	30	15, 50%	7, 23%	5, 16%	1, 3.3%	4 (13.3%)	0	Meningitis: 2 (6.7%)
Yamada et al. 2010	53	31, 58.5%	0	5, 9%	1, 2%	1, 2%	1, 2%	Epistaxis: 1 (2%), pituitary abscess: 1 (2%)
Alahmadi et al. 2011	39	18, 46%	21, 54%	6, 13%	0	0	1 (2.6%)†	1 MI, 1 HCP, 1 sinusitis, 1 crushing

In this study we evaluated our results of endoscopic transsphenoid approach for recurrent and residual pituitary adenomas. Among the 30 cases involved in this study; 19 cases were residual tumors and 11 cases were recurrent after initial total resection. Among the 19 cases with residual tumors; 11 (57.9%) cases had tumor extension to the cavernous sinus and this reflects that the extent of tumor resection was more related to the pattern of tumor extension rather than the nature of the adenoma or the technique of surgery whether microscopic or endoscopic. In 8 patients with residual adenomas; the tumor was confined to sella in 2 cases and sellar with suprasellar extension in 6 cases and the reason for incomplete tumor removal was inadequate opening all the sphenoid septations with limited delineation of the sellar floor with less room for manipulating the endoscope and the instrument.



Mattozo et al. 2006	30	17, 57%	0	5, 17%	Hypoth: 1, 3.3%	1, 3.3%	1, 3.3%	Sinusitis: 1 (3.3%), hyponatremia: 1 (3.3%)
Benveniste et al. 2005	96	0	0	29, 30%	15, 15.6%	5, 5.2%	1, 1%	CN palsy: 1, graft site infection: 1, sinusitis: 5, epistaxis: 1

CN = cranial nerve; HCP = hydrocephalus; Hypopit = hypopituitarism; Hypoth = hypothyroidism; MI = myocardial infarction; PE = pulmonary embolism.

\* Represents a case of hypocortisolemia.

† Patient also had meningitis.

The important surgical step to facilitate efficient tumor resection was the use of binostril four handed endoscopic technique with wide sphenoidotomy and obtaining adequate sellar exposure to have the full panoramic view of the carotid prominences, medial and lateral optico-carotid recesses, planum and clivus. With this technique we achieved total resection of the all 8 cases with residual adenomas and 8 out of 11 recurrent cases involving the sellar and suprasellar area (2, 4, 9, 18, 20, 24, 27, 29).

Extensive tumor extension into the cavernous sinus is a barrier against total resection of pituitary adenoma disregarding the nature of the adenoma and whether it is de novo or recurrent. Some pituitary adenomas like growth hormone secreting adenomas had aggressive inherent biology enabling them to more easily invade surrounding dural and/or bony structures with early parasellar extension into cavernous sinus. The challenge of surgery inside the cavernous sinus increase markedly in recurrent cases particularly if the tumor is fibrous or if the patient was given radiation after the initial surgery. Aggressive attempts of tumor resection inside the cavernous sinus is hazardous and increase the potential surgical risks of vascular injuries and ocular cranial nerves palsy. Among the 19 cases with residual tumors; 11 (57.9%) cases had tumor extension to the cavernous sinus and from the 11 cases with residual tumor in the cavernous sinus; we were able to achieve total tumor resection in one case at the 2<sup>nd</sup> surgery and in 10 cases; a residual tumor was left in the cavernous sinus for further adjuvant treatment and the reason for doing the redo surgery was that the tumor growth after the initial surgery and reduction of the tumor size has the advantage of reducing the mass effect to improve the visual manifestation, better achieving hormonal control in functioning adenomas and would improve the response and reduce the associated morbidities of subsequent adjuvant

treatment (1, 2, 4, 5, 7, 8, 17, 21, 28).

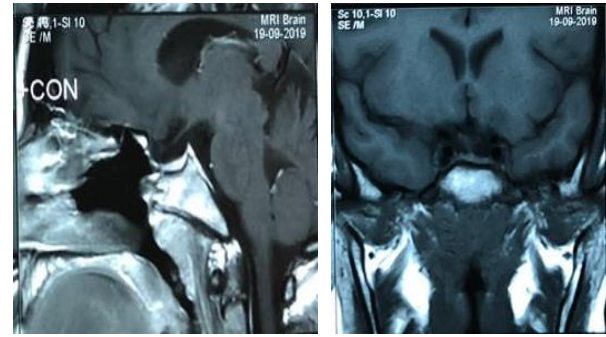
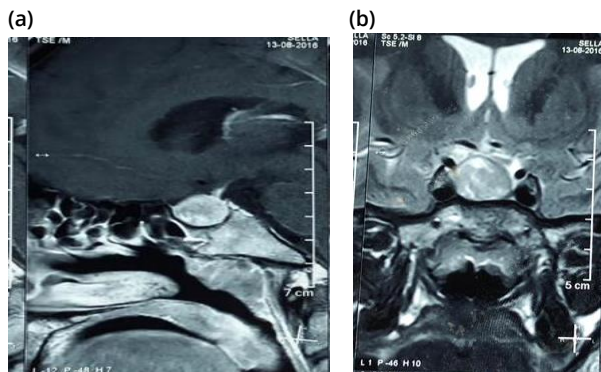
The extent of tumor resection for recurrent adenomas is addressed in many studies in the literature and the growth total resection could be achieved endoscopically in 40% to 63%. The studies of microscopic resection of recurrent pituitary adenomas had similar results with chance of total adenoma resection up to 60%. Although the similarity of the results in the literature; we did all the recurrent cases endoscopically as the we had 19 cases (63.3%) of residual tumor that kept growing after the initial surgery and in 11 of them (57.9%); the residual tumor was in the parasellar region which is a hidden location for the microscopic view. Moreover, the extended endoscopic trans-sphenoidal approach allowed better visualization and hence removal of the sellar and suprasellar component of the tumor than what could be done microscopically. Regardless of the better visualization and tumor manipulation, cavernous sinus invasion remained our greatest limiting factor. The overall Gross total resection in our study was achieved in 17 patients (56.6%) while subtotal and partial resection in 13 patients (43.4%) which is similar to what achieved in other reports in the literature (3, 4, 6, 11, 13, 14, 15, 18, 20, 22, 26, 27).

Reoperations on any recurrent tumor had a higher incidence of complication in comparison for operating a newly developed tumor. Rates of complications for recurrent pituitary tumors in many studies the literature ranged from 9.4% to 31.3%. Presence of scars and adhesions interfere with natural dissection plans adding difficulties for surgery. The challenge is valid for reoperation on recurrent adenomas with higher incidence of morbidities. One critical complication is the occurrence of CSF rhinorrhea after surgery. Intraoperative CSF leakage could be encountered easily because of scaring of the initial surgery and easily injuring the arachnoid during tumor

dissection. Multilayer reconstruction is crucial and if vascularized flaps could be obtained during the redo surgery; it was the best to prevent post-operative CSF leakage. In cases we were not able to harvest vascularized flap; we obtained fascialata and fat graft with fibrin glue to do solid reconstruction when we faced intra-operative CSF leakage. Then lumbar drain was left up to 3 days after surgery. Despite our aggressive reconstruction plan; 3 cases had post-operative CSF rhinorrhea; 2 passed conservatively and one required another endoscopic repair. The incidence of post-operative pituitary hormonal insufficiency was slightly higher with surgery for recurrent adenomas. A meta-analysis of the result endoscopic surgery for recurrent adenomas reported transient DI in 7%, permanent DI in 2.5%, and anterior pituitary hormonal insufficiency in 1.5%. We had 2 cases (6.6%) of transient DI, 2 cases (6.6%) of permanent DI, 3 cases (10%) developed post-operative hypopituitarism requiring long term hormonal replacement therapy. We had a case of mortality from vascular injury during doing a case of recurrent growth hormone secreting adenomas (1,7,8,10,16,17,19,22,23,29).

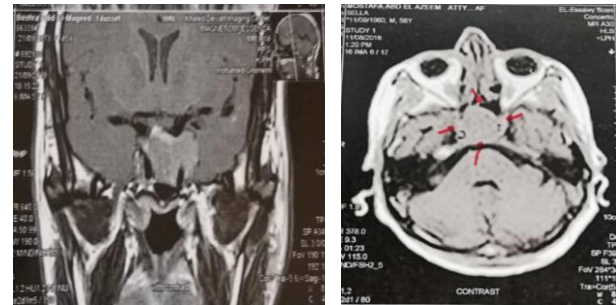
## CONCLUSIONS

Endoscopic endonasal approach for recurrent or residual pituitary adenomas allows optimum visualization and better delineation of all hidden corridors to achieve the safest maximum resection. Although cavernous sinus involvement still prevents total resection but aggressive safe tumor debulking is essential to reduce the compression manifestation, improve hormonal control and optimize the result of any further adjuvant treatment including radiotherapy or radiosurgery. Adequate endoscopic exposure is crucial to improve the extent of resection and minimize the potential morbidities. Solid reconstruction plan is very important to minimize post-operative CSF leakage.

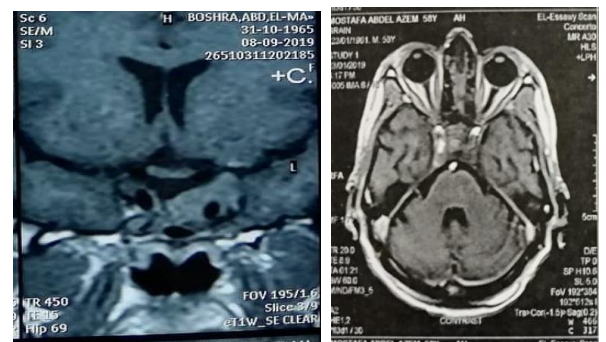


(c) (d)

**Figure 1.** Preoperative MRI image of recurrent nonfunctioning pituitary adenoma sagittal view (a), axial view (b), postoperative follow-up MRI images sagittal view (c), axial view (d).



(a) (b)  
(c) (d)



**Figure 2.** Preoperative MRI image of recurrent growth hormone secreting adenoma sagittal view (a), axial view (b), postoperative follow-up MRI images sagittal view (c), axial view (d).

## ABBREVIATIONS

EOR=extent of resection, COZ= crano-orbito-zygomatic, ICT= intracranial tension, CSF= cerebrospinal fluid, OGM= olfactory groove meningioma, GTR= gross total resection, STR= subtotal resection, TSM= tuberculum sellae meningioma, PSM= planum sphenoidale meningioma.

## REFERENCES

1. Yamada S, Fukuhara N, Oyama K et al. Repeat transsphenoidal surgery for the treatment of remaining



- or recurring pituitary tumors in acromegaly. *Neurosurgery* 67:949–956, 2010
2. Tajudeen BA, Mundi J, Suh JD, Bergsneider M et al. Endoscopic endonasal surgery for recurrent pituitary tumors: technical challenges to the surgical approach. *J NeurolSurg B Skull Base* 76:50–56, 2015
  3. Wang S, Xiao D, Wang R et al. Repeated transsphenoidal surgery for resection of pituitary adenoma. *J CraniofacSurg* 26:452–455, 2015
  4. McLaughlin N, Eisenberg AA, Cohan P et al. Value of endoscopy for maximizing tumor removal in endonasaltranssphenoidal pituitary adenoma surgery. *J Neurosurg* 118:613–620, 2013
  5. Krings JG, Kallogjeri D, Wineland A et al. Complications following primary and revision transsphenoidal surgeries for pituitary tumors. *Laryngoscope* 125:311–317, 2015
  6. Hwang JM, Kim YH, Kim JW et al. Feasibility of endoscopic endonasal approach for recurrent pituitary adenomas after microscopic transsphenoidal approach. *J Korean NeurosurgSoc* 54:317–322, 2013
  7. Jahangiri A, Wagner J, Han SW et al. Morbidity of repeat transsphenoidal surgery assessed in more than 1000 operations. *J Neurosurg* 121:67– 74, 2014
  8. DhandapaniS, Singh H, Negm HMet al. Endonasal endoscopic reoperation for residual or recurrent craniopharyngiomas. *J Neurosurg*2016.
  9. Ferrelif, Turri-Zanoni M, CanevariFRet al. Endoscopic endonasal management of non-functioning pituitary adenomas with cavernous sinus invasion: a 10- year experience. *Rhinology* 53:308–316,2015
  10. HofstetterCP, Nanaszko MJ, Mubita LLet al.Volumetric classification of pituitary macroadenomas predicts outcome and morbidity following endoscopic endonasaltranssphenoidal surgery. *Pituitary* 15:450–463, 2012
  11. Cavallo LM, SolariD, TasiouAet al. Endoscopic endonasaltranssphenoidal removal of recurrent and regrowing pituitary adenomas: experience on a 59-patient series. *World Neurosurg* 80:342–350, 2013
  12. Dehdashti AR, Ganna A, Karabatsou K et al.Pureendoscopic endonasal approach for pituitary adenomas: early surgical results in 200 patients and comparison with previous microsurgical series. *Neurosurgery* 62:1006–1017,2008
  13. Alahmadi H, Dehdashti AR, Gentilif: Endoscopic endonasal surgery in recurrent and residual pituitary adenomas after microscopic resection. *World Neurosurg* 77:540–547,2012
  14. CappabiancaPandSolari D: The endoscopic endonasal approach for the treatment of recurrent or residual pituitary adenomas: widening what to see expands what to do? *World Neurosurg* 77:455–456,2012
  15. Rudnik A, Zawadzki T, Galuszka-Ignasiak B et al. Endoscopic transsphenoidal treatment in recurrent and residual pituitary adenomas-first experience. *Minim InvasNeurosurg* 49:10-14, 2006
  16. Santoro A, Minniti G, Ruggeri A et al. Biochemical remission and recurrence rate of secreting pituitary adenomas after transsphenoidaladenomectomy: long-term endocrinologic follow-up results. *SurgNeuro* 68:513- 518, 2007
  17. Karabatsou K, O’Kelly C, Ganna A et al. Outcomes and quality of life assessment in patients undergoing endoscopic surgery for pituitary adenomas. *Br J Neurosurg* 22:630-635, 2008.
  18. Kelley RT, Smith JL, Rodzewicz GM.Transnasal endoscopic surgery of the pituitary: modifications and results over 10 years. *Laryngoscope* 16:1573-1576, 2006.
  19. Kitano M, Taneda M, Shimono T et al. Extended transsphenoidal approach for surgical management of pituitary adenomas invading the cavernous sinus. *J Neurosurg* 108:26-36, 2008.
  20. Knosp E, Steiner E, Kitz K et al. Pituitary adenomas with invasion of the cavernous sinus space: a magnetic resonance imaging classification compared with surgical findings. *Neurosurgery* 33:610- 617, 1993.
  21. Kurosaki M, Luedecke DK, Abe T: Effectiveness of secondary transnasal surgery in GH-secreting pituitary adenomas. *Nedcor J* 50:635-642, 2003.
  22. Laws ERJr, Foda NC, Redmond MJ: Transsphenoidal surgery following unsuccessful prior therapy. An assessment of benefits and risks in 158 patients. *J Neurosurg* 63:823-829, 1985.
  23. Losa M, Mortini P, Barzaghi R et al. Early results of surgery in patients with nonfunctioning pituitary adenoma and analysis of the risk of tumor recurrence. *J Neurosurg* 108:525-532, 2008.
  24. Mattozo CA, Dusick JR, Esposito F et al. Suboptimal sphenoid and sellar exposure: a consistent finding in patients treated with repeat transsphenoidal surgery for residual endocrine-inactive macroadenomas. *Neurosurgery* 58:857-865, 2006.
  25. Benveniste RJ, King WA, Walsh J et al. Repeated transsphenoidal surgery to treat recurrent or residual pituitary adenoma. *J Neurosurg* 102:1004-1012, 2005.
  26. Negm HM, Al-Mahfoudh R, Pai M et al. Reoperative endoscopic endonasal surgery for residual or recurrent pituitary adenomas. *J Neurosurg* 127:397–408, 2017
  27. Cappabianca P, Alfieri A, Colao A et al. Endoscopic endonasal transsphenoidal surgery in recurrent and residual pituitary adenomas: technical note. *Minim InvasNeurosurg* 43:38-43, 2000.
  28. Cappabianca P, Cavallo LM, Colao AM et al. Surgical complications associated with endoscopic endonasaltranssphenoidal approach for pituitary adenomas. *J Neurosurg* 97:293-298, 2002.
  29. Chang EF, Zada G, Kim S et al. Long-term recurrence and mortality after surgery and adjuvant radiotherapy for nonfunctional pituitary adenomas. *J Neurosurg* 108:736-745, 2008.