

Choroid Plexus Papilloma of the fourth ventricle – Case report and review of the literature

A.V. Ciurea, D. Talianu, C.L. Palade

University of Medicine and Pharmacy “Carol Davila” Bucharest
1-st Neurosurgery Clinic

Introduction

Choroid plexus tumors (CPT) are defined as papillary neoplasms originating from the epithelium of the choroid plexus within the ventricles. They are classified into mainly two types:

-benign choroid plexus papillomas (CPP) (World Health Organization - WHO grade I) and

-choroid plexus carcinomas (WHO grade III). [1,3]

An intermediate group lies between the two groups and is referred to as atypical choroid plexus tumors. However, it is very rare for benign papillomas to convert to carcinomas.[1]

Anatomically, the choroid plexus is the junction between the brain pia and the ventricular ependymal layer in all four ventricles [12,13]. Embryologically, it is derived from the specialization of ventricular neuroepithelium along certain neural tube segments. Interestingly, there is a common ontogeny between choroid epithelium and cells of glial origin. On occasion this may create a source of diagnostic confusion. Physiologically, the choroid plexus is specialized in cerebrospinal fluid production [9,10]

Choroid plexus tumors are seen in all age groups, with an overall incidence of 0.5% to 0.6% of all brain tumors (10% to 20% in infants). However, they are

primarily tumors of childhood with higher incidence rates ranging from 1.8% to 2.9% in the pediatric population. Haddad [16] et al and Galassi [17] et al have reported that choroid plexus tumors constitute 12.8% to 14% of all tumors in infants. Laurence reported that 45% of choroid plexus tumors occur in the first year of life and 74% in the first decade of life. He also concluded that 50% were in the lateral ventricles, 37% in fourth ventricle, 9% in the third ventricle, and the remainder in other locations. There has been no sex predilection shown in many of these studies. They are always solitary tumors. However, rare case reports have been published documenting multiple CPPs. Overall, choroid plexus carcinomas constitute 29% to 39% of all choroid neoplasms. Choroid plexus papillomas are more commonly found in the fourth ventricle in adults.

Keywords: Choroid plexus papillomas, microsurgical techniques

Case presentation

A 34 year old female noticed gait disturbance of gradual onset associated with progressive intracranial hypertension syndrome. Since 6 months previously, she had suffered from slowly progressive headache, nausea, irritability and malaise.

On non-contrast CT, the tumor was noted to be similar in density to brain

tissue, but there was dramatic enhancement with intravenous injection of a contrast agent (Figure 1).

On MRI, the tumor had a signal similar

to that of the surrounding brain, and following gadolinium infusion, a strong increase in the signal was noted (Figure 2, Figure 3, Figure 4).

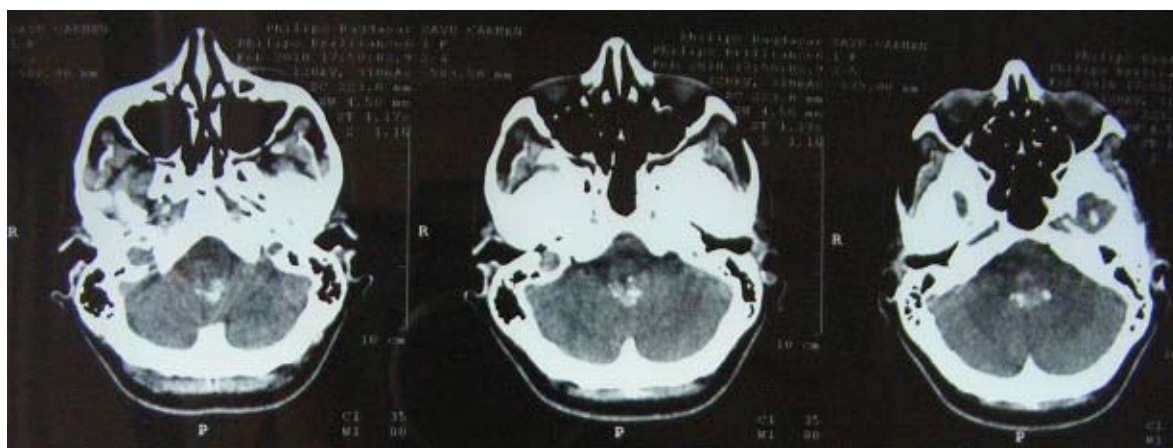


Figure 1 Preoperative CT-scan

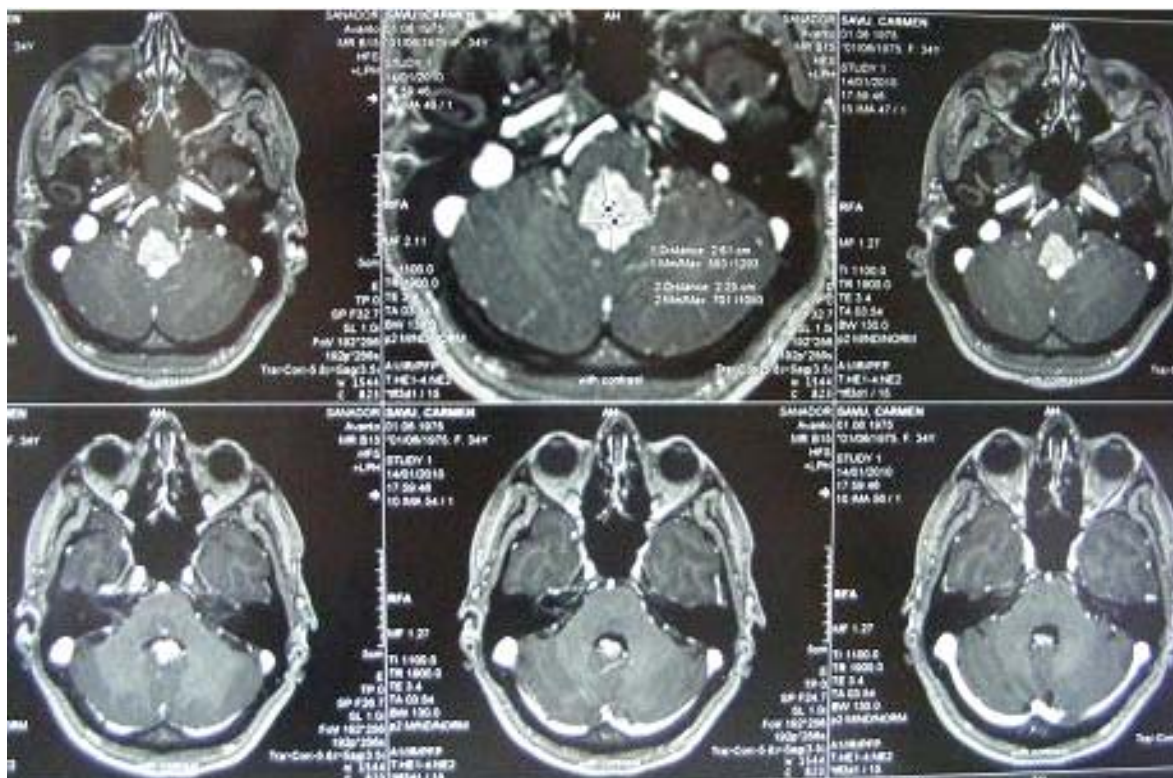


Figure 2 Preoperative MRI –scan (axial incidence)

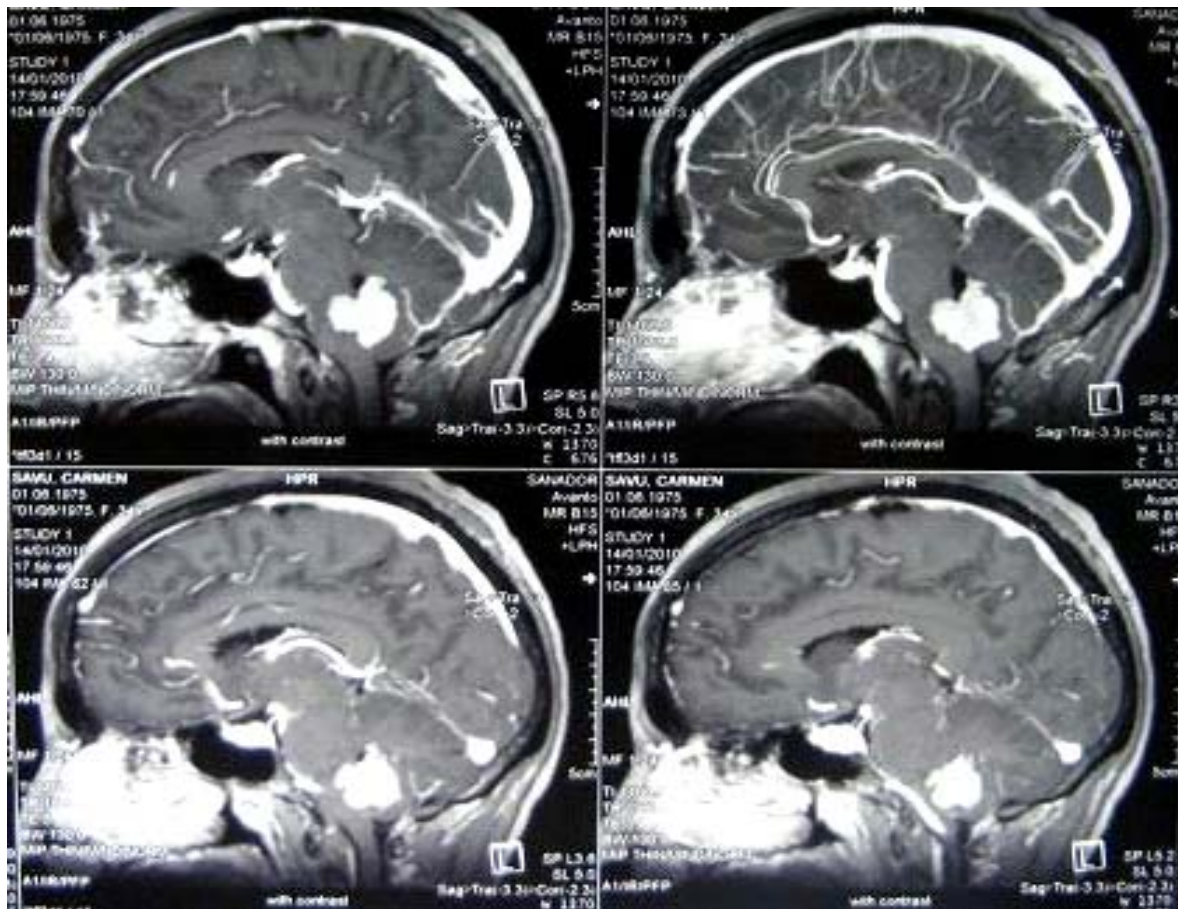


Figure 3 Preoperative MRI-scan (sagittal incidence)

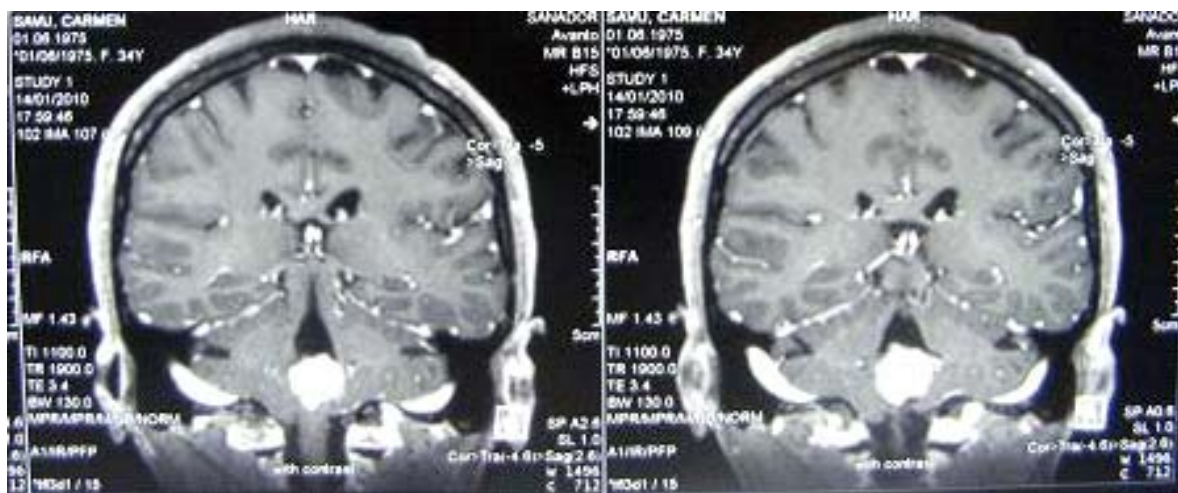

Figure 4 Preoperative MRI-scan (coronal incidence)

After completion of ancillary diagnostic tests and complete medical evaluation, the surgical indication was established and a full consent was documented.

Of the three possibilities for positioning (prone, lateral oblique and sitting) we chose the prone position [9,10]. There are many advantages to this position: the anatomy is clearly visualized, it is easy for two operators to work together and the multiple complications of the sitting position do not occur. The main disadvantage of the prone position is venous congestion that can lead to more significant blood loss, pooling of blood in the operative field and soft-tissue swelling of the face. The neck of the patient was placed in moderate flexion of the upper cervical spine to open up the space between the foramen magnum and the arch of the C1) and less flexion of the lower cervical spine (to bring the occiput parallel with the patient's back). The chin and chest were at least two fingers apart. The table was positioned so that the neck was parallel to the floor and the head was above the level of the heart.

A linear midline incision was outlined 1 to 2 cm above the external occipital protuberance down to the level of C4. The skin was then elevated with toothed forceps and a plane of dissection developed with monopolar coagulation, sparing the occipital artery and nerve. Retractors were then placed to maintain exposure.

Next, the fascia was incised in a linear direction, allowing the use of avascular plane between the splenius capitis and semispinalis capitis muscles. Muscle flaps were then developed with monopolar cautery and periosteal elevators, stripping the muscle from the bone as far as the mastoid emissary vein. The muscle

insertions are stripped off the spinous process and laminae of C2. Finally, the junction between the pericranium and dura at the foramen magnum was sharply dissected from the inner table of the occipital bone using a curet.

The suboccipital craniotomy was begun with burr holes on either side of midline just below the transverse sinuses, approximately 3 cm from midline. The dura near the burr hole was then stripped using a dissector and the bone was cut using the Aesculap craniotome. Inferiorly, the craniotomy included the posterior edge of the foramen magnum, to prevent laceration of the brain against the closed bony rim when cerebellar elements are retracted downward and minimize damage from herniation if hematoma or swelling should occur postoperatively. To expose the posterior arch of C1, the soft tissues overlying it were reflected laterally using a small periosteal elevator, stripping the inferior arch first. The posterior arch of C1 was then removed, using a small angled curet to strip the deep surface of the bone and then using a Kerison punch. The wound was irrigated and the microscope prepared.

The dura was then incised in a „Y” shaped manner. The arachnoid was then opened next to the cisterna magna to allow drainage of the CSF.

Gentle separation of the cerebellar tonsils exposed the cerebellomedullary fissure through the opened vallecula, giving an unimpeded view of the inferior roof of the fourth ventricle. Narrow malleable autostatic retractors were then positioned to maintain separation of the tonsils. The

operating microscope was brought into the field.

The tumor was then removed in a „piece-meal” fashion. The real challenge in the surgical management of CPP was related to its „attachment” to the floor of the fourth ventricle. In this case, this attachment was broad and had the appearance of a „veil” covering much of the ependymal surface. In other cases is a more focal point of origin.

In this situation it was critical from a surgical perspective not to violate the posterior surface of the floor of the fourth ventricle. This is because these tumors are not extending anteriorly into the substance of the brainstem, but posteriorly into the ventricle. As a result of this, the neural structures of the fourth ventricle are in their anatomic position and any effort to remove the tumor, which is essentially „en plaque”, will disrupt functioning cranial nerve nuclei and pathways. Because disruption may involve a wide area, the optimal end-point of removal is to leave a very thin veil of tumor, making no effort to remove all of it. It is critical to recognize that this is impossible and that the operation must be terminated at this point.

After the completion of the tumor resection, the retractors were removed and the cerebellar hemispheres were allowed to fall back into place.

The dura was closed using interrupted 3.0 polypropylene sutures. The suture line was covered with Surgicel.

The bone flap was secured with sutures. The fascia was closed with interrupted sutures to approximate the muscle and fascia. The scalp was then closed in layers, ending with subcutaneous reapproximation

using interrupted sutures with inverted knots.

Perioperative antibiotic prophylaxis and dexamethasone administration were used to lessen the risk of postoperative infection and cerebrospinal fluid leakage [9,10]

The postoperative enhanced CT-scan (second day after the intervention) disclosed no tumoral remnants (Figure 5).

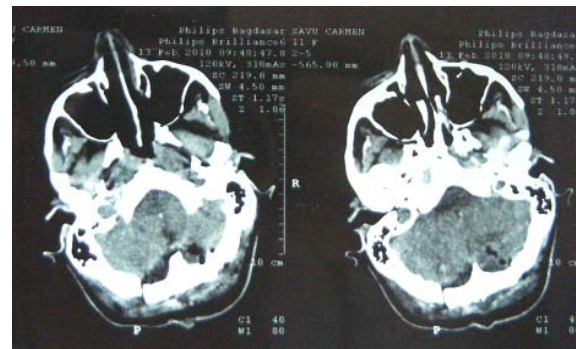
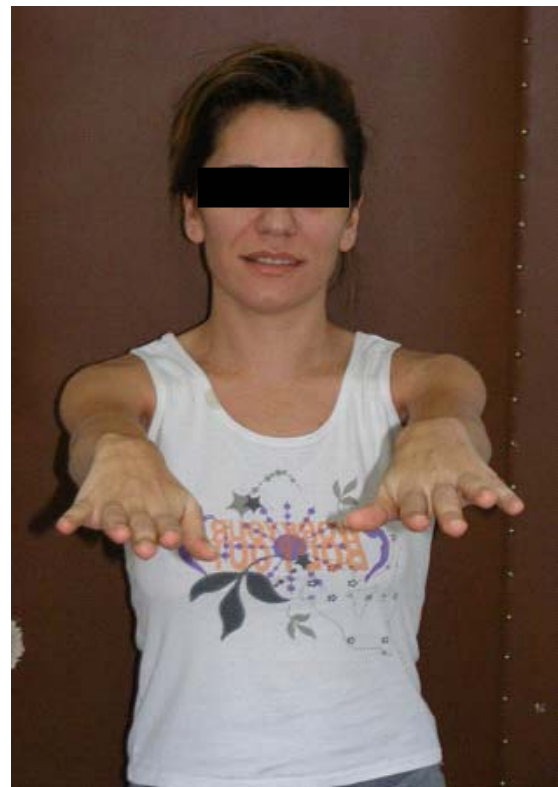

Figure 5 Postoperative enhanced CT-scan (second day after the intervention)



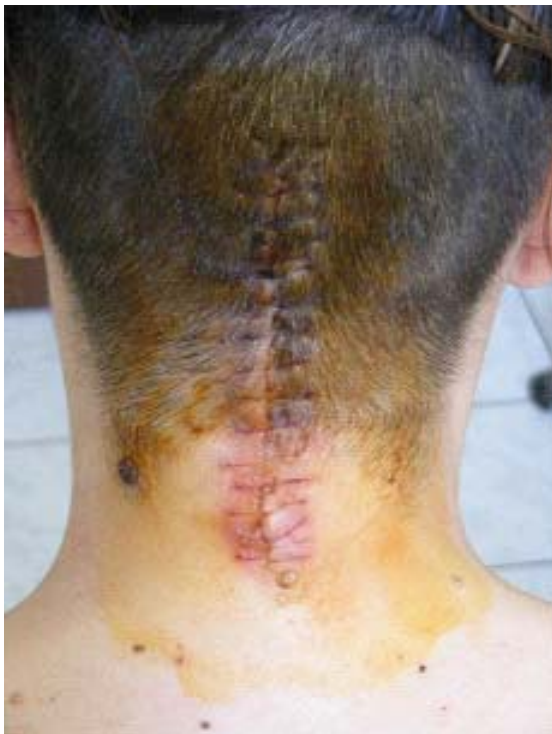

Figure 6 Postoperative aspects of the patient

Discussion

Clinical Findings

The clinical features depend on the age of the patient and location of the tumor. In infants, an enlarging head related to associated hydrocephalus may be the only sign. In children, symptoms of increased intracranial pressure, such as nausea, vomiting, irritability, and headache, secondary to hydrocephalus may be seen [14,21]. Other findings include papilledema, hemiparesis, hyperreflexia, abducens nerve palsy, stupor, and coma. Those with posterior fossa lesions are more likely to have brainstem and cerebellar findings, including cranial nerve abnormalities, pyramidal tract signs, and ataxia. The duration of symptoms before diagnosis varies from 1 day to 4 years (median 4 weeks), with earlier symptom onset in younger patients and patients with CPC. Hydrocephalus is a near ubiquitous finding in those with CPTs, and several reasons for its development have been suggested, including obstruction of CSF pathways by the tumor, hypersecretion of CSF by the tumor, and blockage of CSF absorption from repeated tumor microhemorrhage or elevated CSF protein concentrations [29]. Of these, CSF overproduction is considered the principle mechanism with one series identifying a patient with CSF production almost doubling the norm.

Diagnostic Studies

The diagnosis of CPTs relies on modern imaging modalities such as computed tomography (CT), magnetic resonance imaging (MRI), and magnetic resonance angiography (MRA) [27,31]

Laboratory studies have limited sensitivity and specificity in detecting or predicting this type of tumor. Studies

examining CSF are of low diagnostic yield. On radiological modalities, their unilaterality and peripheral lobulations can help distinguish CPTs from other tumors, including meningiomas, ependymomas, and metastasis. CPP and CPC are generally isodense or hyperdense intraventricular masses on unenhanced CT scans. They show intense enhancement on contrast-enhanced CT images. CT is superior to MRI in detecting associated intratumoral calcifications. However, MRI is the imaging modality of choice because of its inherent superb anatomic detail, tissue contrast, ability to directly image in multiple planes, and increased sensitivity in determining tumor extent [30,31,33]. The uncalcified portions of CPPs appear isointense or hypointense to normal brain parenchyma on T1-weighted images and hyperintense on T2-weighted images. If doubt remains about the imaging diagnosis with MRI, a simple noncontrast CT may improve diagnostic because, in general, adult fourth ventricular CPPs will appear markedly calcified, whereas ependymomas will not. Contrast enhancement on MRI tends to be uniform and intense, and flow voids are common. MRA or conventional angiograph are not routinely necessary but may demonstrate enlarged choroidal arteries supplying the tumor [27]. The distinction between CPP and CPC is not always possible on imaging studies. Differentiation of the two is based on histology, not radiology. CPTs with a benign imaging appearance may be carcinomas histologically, and those with an aggressive imaging appearance may turn out to be papillomas. Nonetheless, proper imaging characterization of CPTs preoperatively may affect surgical approach to the tumor. CPCs tend to have more

heterogeneous T1- and T2-weighted imaging and enhancement characteristics. This reflects the presence of more tumor necrosis due to the tumor's rapid growth rate. Extraventricular extension into brain parenchyma and presence of associated vasogenic edema favor CPC over CPP [22].

CSF dissemination can occur with CPP or CPC but is much more common with the latter. The degree of hydrocephalus in CPC has been noted to be less than that seen with CPPs. Functional imaging with positron-emission tomography (PET) may demonstrate increased metabolic activity in CPC. Seeding of the cerebrospinal fluid has been reported in both CPPs and CPCs. However, clinically significant seeding is much more common in patients with a CPC. Therefore imaging of the spinal neural axis may be helpful in detecting CSF dissemination [20,22].

Histopathology

In the current World Health Organization (WHO) classification, CPP is a WHO grade I neoplasm, whereas CPC corresponds to a WHO grade III neoplasm.

Macroscopic Features

CPTs are often soft to rubbery, having a cauliflower-like form, and may have a gritty texture due to calcifications. The tumors are often orange-brown, and an attachment to the normal choroid plexus or the ventricular wall may be present. Some CPCs, and rare CPPs, bleed profusely [1,3,11,18]

Surgical treatment

Surgery is the mainstay of treatment for CPPs and a necessary first step in diagnosis and treatment of CPCs. As noted

previously, the younger the patient, the more likely it is that CPPs are found within the lateral or third ventricle, and as the patient approaches adulthood tumors in the fourth ventricle or cerebellopontine angle are more common. Also, the younger the patient, the more likely it is that the tumor will be associated with hydrocephalus. Therefore the goals in the management of these patients are relieving hydrocephalus, establishing a tissue diagnosis, and complete tumor removal. Complete tumor removal is the goal with CPPs and can be achieved in most cases even if this requires more than one operation. However, with CPCs subtotal resection is more common. The treatment of associated hydrocephalus and the surgical approaches to each of the ventricular sites are unique and beyond the scope of this text, but some general comments can be made [6,9,10].

Hydrocephalus associated with these tumors can usually be managed with an external ventricular drain as necessary before or at the time of definitive tumor removal. We avoid a permanent shunt system before tumor removal, because in many patients tumor removal can solve the problem, and intraventricular surgery is associated with postoperative blood products that need to be cleared from the ventricle over several days and may obstruct permanent systems. Ellenbogen et al found that after tumor removal in children, 63% did not require a permanent shunt. In some patients, despite tumor removal, ventriculoperitoneal shunting may be necessary for communicating hydrocephalus, and some will require subdural to peritoneal shunting for subdural fluid collections that persist after transcortical approaches to tumors of the lateral ventricles [10,13,14].

Intra-axial Tumors

Surgery for these tumors is complicated by their extreme vascularity and an inability to preoperatively embolize the arteries supplying the tumor. The tumors are quite friable, and blood loss can be a limiting factor in achieving gross-total tumor removal in neonates and infants.⁴⁸ Staged surgery for CPPs is always an option. The blood supply to these tumors comes from the named choroidal arteries that normally supply the plexus, and these small vessels (anterior choroidal, posterior medial choroidal, posterior lateral choroidal, choroidal branch of the posterior inferior cerebellar artery) cannot be cannulated or embolized by interventional neuroradiologists for technical reasons (small caliber, distal arterial tree location) of risks of interference with blood supply to normal brain by the same artery (anterior choroidal, posterior inferior cerebellar) [9,13].

Ideally, once the tumor is exposed, interruption of the feeding artery before tumor resection is begun is recommended. Some authors have described en bloc removal of smaller tumors after doing just that. In adults, fourth ventricular tumors may be heavily calcified at diagnosis and may be relatively avascular. Tumors of the lateral ventricles (frontal horn, temporal horn, body) are approached either by an interhemispheric transcallosal approach (anterior to midbody of lateral ventricle; third ventricle) or a transcortical-transventricular route (temporal horn, posterior body to atrium). Transcortical incisions may be associated with ventriculo-subdural connections that account for the fluid collections requiring subdural to peritoneal shunting postoperatively. Most surgeons will attempt a sulcal splitting

approach to limit the amount of subcortical white matter cut and to reduce the chance of fluid collections developing. For tumors of the fourth ventricle a midline suboccipital craniotomy is used, and planes of dissection between the cerebellum and brainstem can be developed that allow for adequate exposure without the need for splitting of cerebellar tissue.

Tumors of the cerebellopontine angle are approached by a retrosigmoid (more lateral) suboccipital craniotomy. In both cases, because of proximity to cranial nerves within the subarachnoid space, neurophysiologic monitoring of these nerves is routine to reduce the chance of nerve injury with exophytic or large tumors. In general, complete removal of CPPs is possible in the majority of cases even if more than one operation is required. Complete removal holds the best chance for long-term tumor control or cure. For CPCs, which are often disseminated at diagnosis and more often invading brain, subtotal removal is the norm [10,14].

Conclusions

The optimum treatment of patients with CPTs requires logical decision making and surgical skills of the neurosurgeon who plays a pivotal role in caring for these patients.

Recent developments in neurosurgical technology have reduced the morbidity and mortality of patients undergoing CPT surgery.

The use of the operating microscope allows the surgeon to observe in detail the operative field and perform an almost totally safe tumor resection.

Correspondence to:
claudiu_palade@yahoo.com,
rsneurosurgery@gmail.com

References

1. Aguzzi A, Brandner S, Paulus W: Choroid plexus tumours. In Kleihues P, Cavane W(eds): Pathology and Genetics of Tumours of the Nervous System. Lyon, France, IARC, 2000.
2. Allen J, Wisoff J, Helson L, et al: Choroid plexus carcinoma— responses to chemotherapy alone in newly diagnosed young children. *J Neurooncol* 12:69–74, 1992.
3. Ang LC, Taylor AR, Bergin D, Kaufmann JC: An immunohistochemical study of papillary tumors in the central nervous system. *Cancer* 65:2712–2719, 1990.
4. Berger C, Thiesse P, Lellouch-Tubiana A, et al: Choroid plexus carcinomas in childhood: clinical features and prognostic factors. *Neurosurgery* 42:470–475, 1998.
5. Bielschowsky M, Unger E: Kenntinis der primären Epithelgeschwultse der Adergeflechte des Gehirns. *Arch Klin Chir* 81:61–82, 1906.
6. Boyd MC, Steinbok P: Choroid plexus tumors: problems in diagnosis and management. *J Neurosurg* 66:800–805, 1987.
7. Cardozo J, Cepeda F, Quintero M, et al: Choroid plexus papilloma containing bone. *Acta Neuropathol (Berl)* 68:83–85, 1985.
8. Chow E, Jenkins JJ, Burger PC, et al: Malignant evolution of choroid plexus papilloma. *Pediatr Neurosurg* 31:127–130, 1999.
9. Ciurea AV (2007) Tumorile Intracraniene. In: Ciurea AV *Tratat de Chirurgie, Editura Academiei, Bucuresti*, p 172
10. Ciurea AV, Constantinovici A (1998) Papilomul de plex coroid. In: Ciurea AV, Constantinovici A *Ghid practic de neurochirurgie, Editura Medicala, Bucuresti*, p 341
11. Coates TL, Hinshaw DB, Jr., Peckman N, et al: Pediatric choroid plexus neoplasms: MR, CT, and pathologic correlation. *Radiology* 173:81–88, 1989.
12. Cushing H: *Intracranial Tumors*, Springfield, Charles C. Thomas, 1932.
13. Dandy W: Diagnosis, localization and removal of tumours of the third ventricle. *Bull Johns Hopkins Hosp* 33:188, 1922.
14. Ellenbogen RG, Winston KR, Kupsy WJ: Tumors of the choroid plexus in children. *Neurosurgery* 25:327–335, 1989.
15. Enomoto H, Mizuno M, Katsumata T, Doi T: Intracranial metastasis of a choroid plexus papilloma originating in the cerebellopontine angle region: a case report. *Surg Neurol* 36:54–58, 1991.
16. Galassi E, Godano U, Cavallo M, et al: Intracranial tumors during the 1st year of life. *Childs Nerv Syst* 5:288, 1989.
17. Haddad SF, Menezes AH, Bell WF, et al: Brain tumors occurring before 1 year of age: a retrospective

- review of 22 cases in an 11- year period (1977–1987). *Neurosurgery* 29:8, 1991.
18. Itoh Y, Kowada M, Mineura K: Choroid plexus carcinoma. Report of a case with positron emission tomographic study. *Neuroradiology* 28:374, 1986.
19. Kato T, Fujita M, Sawamura Y, et al: Clinicopathological study of choroid plexus tumors: immunohistochemical features and evaluation of proliferative potential by PCNA and Ki-67 immunostaining. *Noshuyo Byori* 13:99–105, 1996.
20. Ken JG, Sobel DF, Copeland BF, et al: Choroid plexus papillomas of the foramen of Luschka. MR appearance. *AJNR AmJNeuroradiol* 12:1201–1203, 1991.
21. Kepes JJ: “Xanthomatous” changes in a papilloma of the choroid plexus. *Acta Neuropathol (Berl)* 16:367–369, 1970.
22. Koeller KK, Sandberg GD: From the archives of the AFIP. Cerebral intraventricular neoplasms: radiologic-pathologic correlation. *Radiographics* 22:1473–1505, 2002.
23. Levy ML, Goldfarb A, Hyder DJ, et al: Choroid plexus tumors in children: significance of stromal invasion. *Neurosurgery* 48:303–309, 2001.
24. McEvoy AW, Harding BN, Phipps KP, et al: Management of choroid plexus tumors in children- 20 years experience at a single neurosurgical centre. *Pediatr Neurosurg* 32:192–199, 2000.
25. McGirr SJ, Ebersold MJ, Scheithauer BW, et al: Choroid plexus papillomas: Long-term follow-up results in a surgically treated series. *J Neurosurg* 69:843–849, 1988.
26. Niikawa S, Ito T, Murakawa T, et al: Recurrence of choroid plexus papilloma with malignant transformation—case report and lectin histochemistry study. *Neurol Med Chir (Tokyo)* 33:32–35, 1993.
27. Packer RJ, Perilongo G, Johnson D, et al: Choroid plexus carcinoma of childhood. *Cancer* 69:580–585, 1992.
28. Paulus W, Janisch W: Clinicopathologic correlations in epithelial choroid plexus neoplasms: a study of 52 cases. *Acta Neuropathol (Berl)* 80:635–641, 1990.
29. Pensalet P, Sainte-Rose C, Lellouch-Tubiana A, et al: Papillomas and carcinomas of the choroid plexus in children. *J Neurosurg* 88:521–528, 1998.
30. Shin JH, Lee HK, Jeong AK, et al: Choroid plexus papilloma in the posterior cranial fossa MR, CT, and angiographic findings. *Clin Imaging* 25:154–162, 2001.
31. Vazquez E, Ball WS, Jr, Prenger EC, et al: Magnetic resonance imaging of fourth ventricular choroid plexus neoplasms in childhood. A report of two cases. *Pediatr Neurosurg* 17:48–52, 1991.
32. Wolff JE, Sajedi M, Brant R, et al: Choroid plexus tumours. *Br J Cancer* 87:1086–1091, 2002.
33. Yap WM, Chuah KL, Tan PH: Choroid plexus papilloma with chondroid metaplasia. *Histopathology* 31:386–387, 1997.