

## Intracranial arahnoid cysts in children (ACs)

A.V. Ciurea<sup>1</sup>, A. Tascu<sup>1</sup>, A. Iliescu<sup>1</sup>, C. Mihalache<sup>2</sup>, F. Brehar<sup>1</sup>, C. Palade<sup>1</sup>,  
A. Spatariu<sup>1</sup>

<sup>1</sup>I-st Neurosurgical Clinic, Clinic Hospital “Bagdasar-Arseni”

<sup>2</sup>Sf. Andrei Emergency County Hosp. Galati Neurosurg Departament, Galati

### Abstract

Intracranial arahnoid cysts (ACs) represent an extremely common condition in pediatric pathology. With the development of CT Scan and especially MRI these cysts could be find more constantly.

ACs are congenital lesions with maximum frequency in middle cranial fossa, followed by suprasellar aria , ponto-cerebelar angle and cranial posterior fossa.

These cysts are often incidentally uncovered during a routine neuroimaging investigations for cranio-cerebral trauma or other diseases.

The authors present a series of 317 cases in children with ACs over a period of 10 years.

The authors avocate over the MRI evaluation of Acs and referring to therapeutic approach it is recomanded only in compresive forms with focal neurological sings or seizures.

Are rewiewed therapeutical procedures as: microsurgical fenestration with cystwall excision, endoscopic approach, stereotaxic suction, cyst shunting by cysto-peritoneal procedures. A number of cases remain under observation the surgical treatment beeing unnecessary. The surgical treatment must be carfully chosen, there is non therapeutical priority. It remains that improved neuroendoscopic methods to

improve operator prognosis in Acs.

**Keywords:** Intracranial arahnoid cyst, MRI, microsurgical fenestration, endoscopic approach, cyst shunting, increased intracranial pressure, seizures

### Introduction

Intracranial arahnoid cysts(ACs) also known as leptomenigeal cysts, are congenital, benign, nonneoplastic, extraxial lesions. ACs arise during development from splitting of arahnoid membrane, and are distinct from posttraumatic cysts and unrelated to infection.

Bright (1831) describe the intraarahnoidian origin of these lesion as “serous cysts forming in connection with the arahnoid and apparently lying between its layers.”, Starkman et all (1958) proposed that the asociated temporal hypoplasia is secondary to cyst expansion and pressure on the temporal operculum. Also Robinson (1961) the primary source of the problem lay in a congenital failure of temporal lobe development.

Acording to Di Rocco et all(2010), Acs are developmental defect, that occurs within the first three months of gestational life, in the duplication or splitting of the arahnoid layers, and are related to abnormalities of CSF flow. This theory cover the whole development of intracranial arahnoidian cysts. Acs are

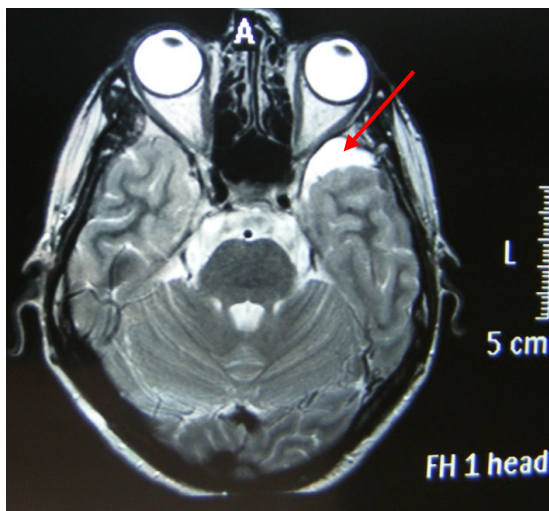
associated with other developmental abnormalities of the brain, such as heterotopias. Incidence of Acs in 5 per 1000 in autopsy series and represent 1% of all intracranial masses. The male: female rate is 4:1, Di Rocco et all.( 2010). Multiple or bilateral arachnoid cysts are unusual, and familial occurrence has been reported in only a few cases.

**Location**

In 50% intracranial arachnoid cyst involve the Sylvian fissure/middle cerebral fossa . Rengachary&Watanabe (1980) (Table I). According to Gallasi et all. (1980) Sylvian Acs can be classified into three subgroups in connection with cysts dimensions and extensions.

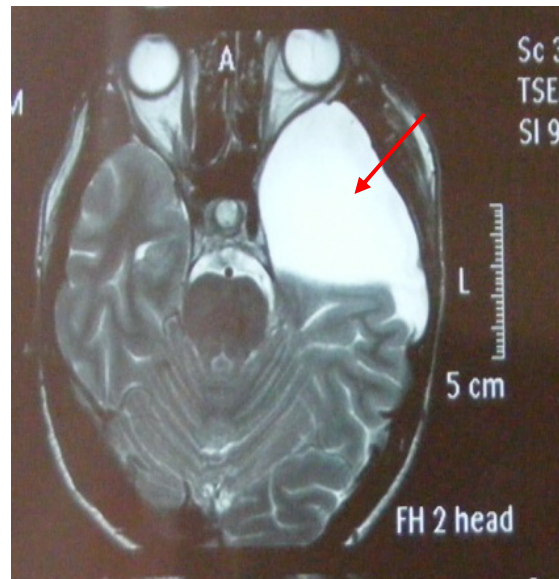
Gallasi type I: small, biconvex, located in anterior temporal tip, no mass effect, communicates with subarachnoid space.(Figure 1).

In Gallasi type II: involves proximal and intermediate segments of Sylvian fissure, completely open insula gives rectangular shape,partial communication with subarachnoidian space (Figure 2).

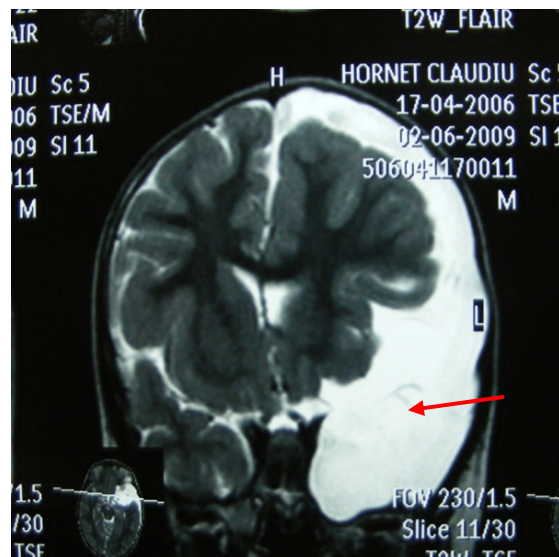


**Figure 1** MRI-aspect of Gallasi I left temporal arachnoid cyst

In Gallasi type III: involves entire Sylvian fissure, midline shift, bony expansion, minimal communication with the subarachnoidian space and surgical treatment usually does not result in efficient expansion of brain (Figure 3).



**Figure 2** MRI – aspect of Gallasi II left temporo-insular arachnoid cyst



**Figure 3** MRI- aspect of Gallasi III left cerebral hemisfere arachnoid cyst with middle line shift

Other common locations are: CP angle, the quadrigeminal cistern, the retrocerebellar area and the sellar/suprasellar region. Less commonly ACs can develop within the interhemispheric fissure and cerebral convexity (Tabel I).

### Clinical findings

ACs become symptomatic mainly during childhood and adolescence, depending on the location of the cyst not to its dimension. Asymmetrical macrocranium or a focal bulging of the skull in the temporal region is the most common symptom, headaches, focal neurological symptoms, epilepsy and signs of increased intracranial pressure.

In suprasellar ACs endocrine disfunctions (60% of cases), hydrocephalus (40% of cases - probably due to compression of the third ventricle) and visual impairment are the most common presenting symptoms.

Natural evolution occurring without signs of: inflammation, trauma or hemorrhage. May be associated with other congenital anomalies (agenesis of the corpus callosum). Often do not expand and rarely may spontaneously regress or disappear

### Therapeutical options

Observation - Many authors recommend not treating arachnoid cysts that do not cause mass effect or symptoms, regardless of their size and location. Fatih E, Burkan B, Pinar O (2003)

Multimodal surgical treatment consisting of shunting the cyst into peritoneum, craniotomy (microsurgery) with fenestration and cystwall excision, endoscopic fenestration or stereotactic suction. Ciurea et al. (2010)

Nowadays endoscopic fenestration represent the main therapeutical option in arachnoid cyst for decompression and restoration of CSF circulation.

Each procedure has advantages and disadvantages as described in table II.

**TABEL I**  
**Localization of**  
**ACs (Rengachary & Watanabe 1981)**

Location	%
Sylvian fissure	49%
CPA	11%
Supracollicular	10%
Pineal area	9%
Sellar & suprasellar	9%
Interhemispheric	5%
Cerebral convexity	4%
Clival	3%

**TABEL II**  
**Surgical treatment options for arachnoid cysts (Keyvan Abtin and Marion L 2010)**

PROCEDURE	ADVANTAGES	DISADVANTAGES
Drainage by needle aspiration or bur hole evacuation	<ul style="list-style-type: none"> <li>• simple</li> <li>• quick</li> </ul>	<ul style="list-style-type: none"> <li>• high rate of recurrence of cyst and neurologic deficit</li> </ul>
Craniotomy, excising cyst wall and fenestrating into basal cistern	<ul style="list-style-type: none"> <li>• permits direct inspection of cyst</li> <li>• loculated cysts treated more effectively</li> <li>• avoid permanent shunt</li> <li>• allows visualization of bridging vessels</li> </ul>	<ul style="list-style-type: none"> <li>• subsequent scarring may block fenestration allowing reaccumulation</li> <li>• significant morbidity and mortality</li> </ul>

Endoscopic cyst fenestration	<ul style="list-style-type: none"> <li>• minimal invasive</li> <li>• avoid permanent shunt</li> </ul>	<ul style="list-style-type: none"> <li>• no visualization of bridging vessels- hemoragic risk</li> <li>• fenestration may close</li> </ul>
Shunting of cyst into peritoneum	<ul style="list-style-type: none"> <li>• low morbidity/mortality</li> <li>• low rate of recurrence</li> </ul>	<ul style="list-style-type: none"> <li>• patient “shunt dependent”- risk of shunt infection</li> </ul>

**Patients and methods**

The authors study 317 cases of arachnoid cysts, admitted in 1st neurosurgical clinic, pediatric neurosurgical department Bagdasar-Arseni Hospital between January 2002-January 2010 (8 years). Admission criteria was: age between 0 to 16 years old and patients diagnosed, treated and followed in 1st Neurosurgical clinic.

There were excluded all patients over 16 years old or treated in other neurosurgical services.

**Results**

Localisation of ACs: Sylvian fissure 172 cases(54%), CP angle 38 cases(12%), sellar and suprasellar region 32 cases(10%), pineal area 28 cases(9%), retrocerebellar 28 cases (9%) and interhemispheric 19 cases(6%). (table III)

**TABLE III**

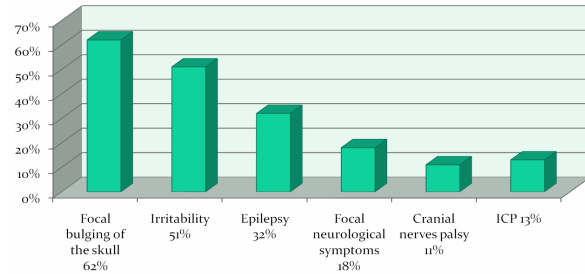
**Location of intracranial Acs current study**

Location	Number of cases	Percentage %
Sylvian fissure	172	54
CPA	38	12
Sellar & suprasellar area	32	10
Pineal area	28	9
Retrocerebellar	28	9
Interhemispheric	19	6
<b>Total</b>	<b>317</b>	<b>100</b>

The most common clinical finding was the focal bulging of the skull 62% (196 cases), irritability 51%(162 cases), epilepsy 32%(101 cases) minor focal neurological symptoms 18%(57 cases), cranial nerves palsy 11%(35 cases) and increased intracranial pressure syndrome in 13% (41cases) (tabel IV).

**TABLE IV**

**Clinical findings in current study**



Elected treatment was: (table V)

**TABLE V**

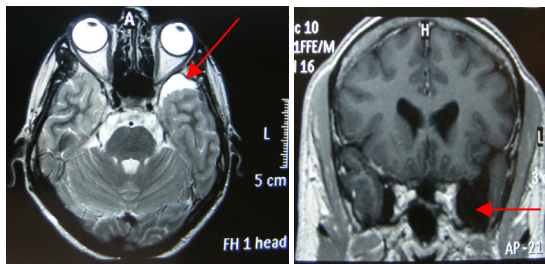
**Elected treatment in current study**

Type of intervention	Number of cases	Percentage %
Observation	40	12,6
Unishunt cysto-peritoneal dr.	162	51,4
Low pressure valv CPS	20	6,3
Endoscopic procedure	31	9,7
Mycrosurgery	64	20,1
<b>Total</b>	<b>317</b>	<b>100</b>

- observation in 40 de cases(12,6%)

### Case presentation I

A 16 years old girl presenting with migrenal syndrome . The MRI investigation show a Gallasi tip I cyst of the left middle fossa. The elected treatment was observation with MRI reevaluation annually.

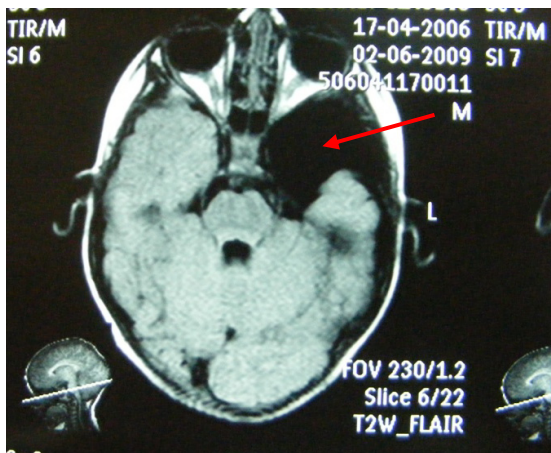


**Figure 4** MRI- Gallasi I left temporal pole ACs-observational treatment

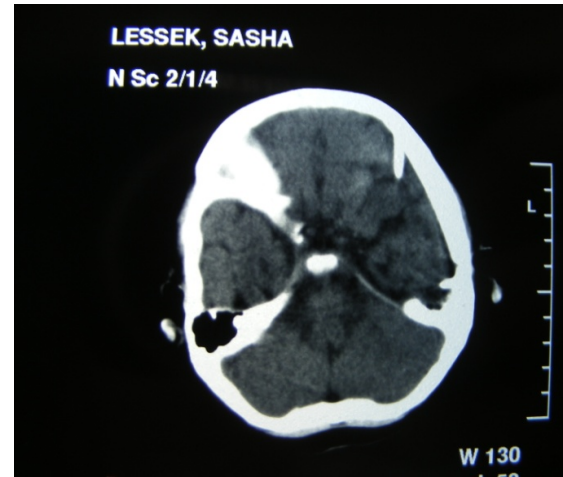
- unishunt cysto-peritoneal drainage 162 cases (51,4%) & low pressure valv cysto-peritoneal shunt in 20 cases (6,3%).

### Case presentation II

A 4 years old girl presenting with epileptic seizures. The preoperative investigation show a Gallasi tip II left middle fossa cyst. The elected treatment was a unishunt cysto-peritoneal shunt.



**Figure 5** MRI preoperative aspect of a Gallasi II left temporal ACs



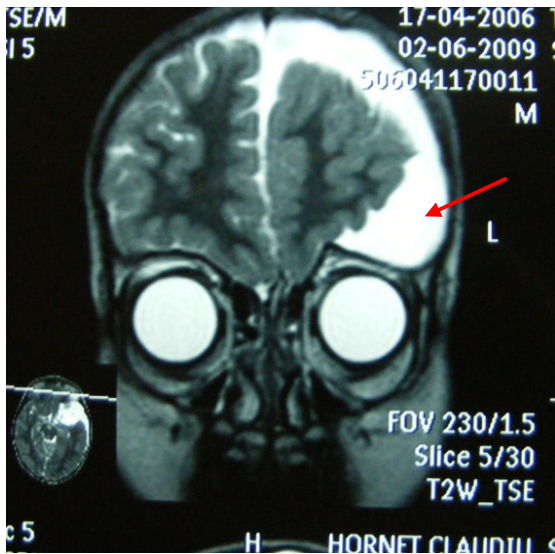
**Figure 6** CT scan postoperative aspect of the same cyst as figure 5 after cysto-peritoneal shunting, and the patient

- microsurgical approach with cystwall excision and fenestration in 64 cases (20,1%).

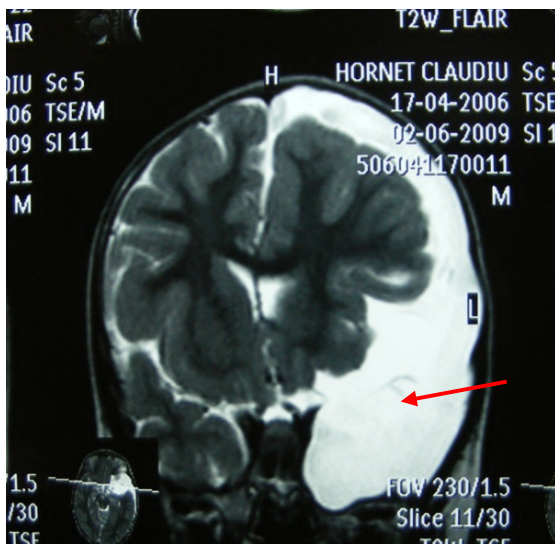
### Case presentation III

A 3 yrs old boy presenting with seizures unresponsive to medical treatment. The MRI evaluation show a Gallasi III arachnoidian cyst of left cerebral hemisphere. The elected treatment was microsurgical approach with cyst wall excision and fenestration. The outcome was a good recovery.

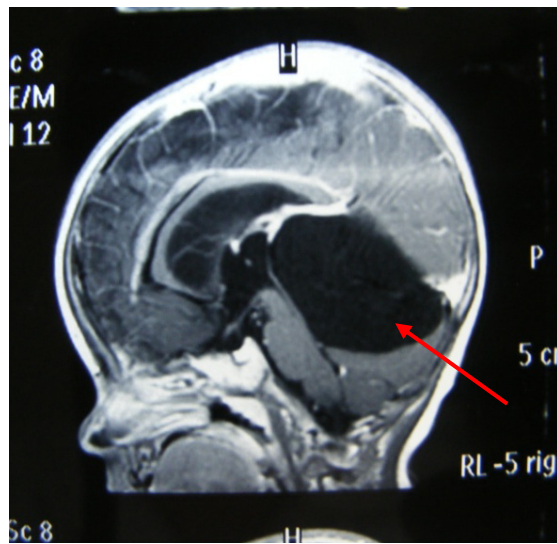




**Figure 7** preoperative MRI aspect of a Gallasi III left cerebral hemisphere ACs



**Figure 8** postoperative CT scan aspect of the same cyst as in figure7 after microneurosurgical treatment



**Figure 9** preoperative MRI aspect of a supracollicular giant ACs

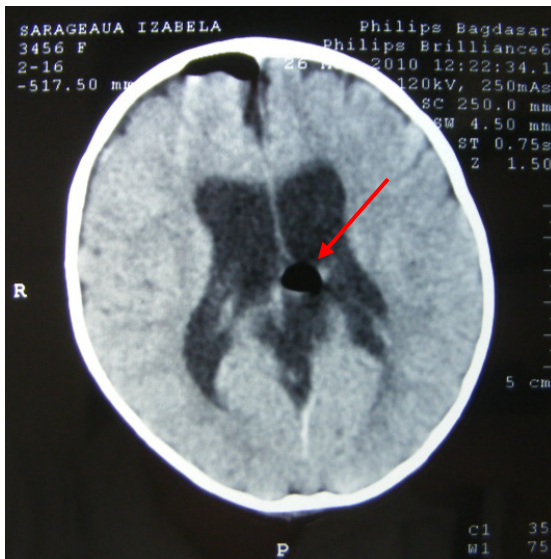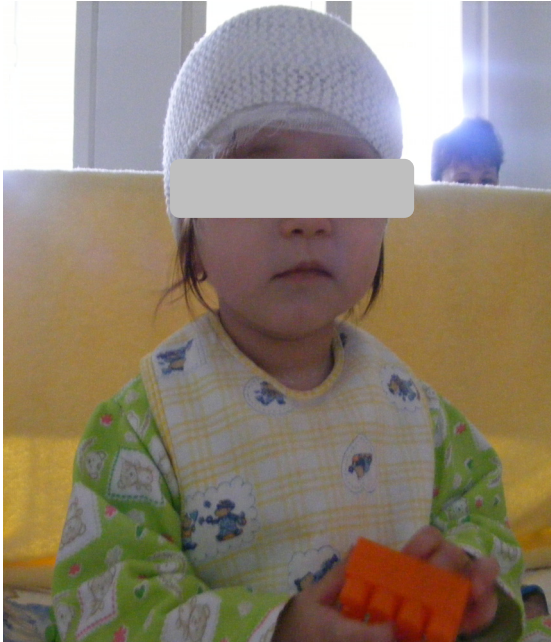Microsurgical approach with cystwall excision and fenestration is recommended as an initial approach to avoid shunting

Shunt independence an important surgical goal. Keyvan Abtin & Marion I. Walker (2007)

- endoscopic procedure in 31 cases (9,7%)

#### Case presentation IV

A 1 year old girl presenting with hypotonic syndrome and psymotor retardation. The MRI examination show a supracollicular giant ACs, The elected treatment was endoscopic fenestration.



**Figure 10** postoperative CT scan aspect of the same cyst as in figure 9, after endoscopic fenestration, and the patient

## Discussion

Intracranial arachnoid cysts are mentioned throughout the specialised literature. The discovery of such cysts in almost all cases is done when is made an CT scan or MRI exam of the brain for

other disease of nervous system. Once the intracranial arachnoidian cyst is found, one has to establish very carefully the clinical findings, neuroimaging evaluation and after that we may proceed to a possible surgical treatment.

There are 2 histological types of ACs:

1. "simple arachnoid cysts": arachnoid lining with cell that appear to be capable of active CSF secretion. Middle fossa cysts seem to be exclusively of this type.

2. cysts with more complex lining which may also contain neuroglia, ependyma and other tissue types. Mayr U, Aicher F, Bauer G et al (1982)

Many authors recommend observation and monitoring of these cysts on MRI. The rarity of expanding arachnoid cysts makes frequent serial neuroimaging unnecessary and cost ineffective. The recommended follow-up neuroimaging is at one year.

In case of a symptomatic cyst by neurological focal deficit, epilepsy or reised ICP the best surgical solution to release pressure on the cerebral structure has to be found.

For a long time shunting mettods were prefered. But with the apperence of shunt complication this mettods where abandoned. Microneurosurgical approach of fenestration are very effective but they require latge opening of basal cistern.

Nowadays as miminally invasive procedure the endoscopic procedures has become increasingly popular "the procedure of choice" and has been used to decrease the number of shunts. Hopf N J, Perneczky A (1998)

As effective and safe and less invasive but great care in needed to avoid bleeding -ACs are associated with large bridging veins. F. di Rocco et all (2010)

Intraoperative ultrasound or frameless

stereotaxy, especially with intravenous contrast enhanced CT or MR imaging guidance, is helpful in choosing the trajectory of the bridging veins. Main limitation is anatomical: due to the relation of the cyst with the basal cisterns and the temporal lobe displacement. C di Rocco et al (2010)

### Conclusions

ACs are very frequent congenital intracranial malformation.

More than 80% of ACs are incidental findings being completely asymptomatic.

Treatment is recommended only in symptomatic ACs by focal neurological deficits, skull deformities, signs/symptoms related to increased ICP and seizures not responsive to medical treatment.

Current series of 317 cases constitute a uniform cohort because cases are diagnosed, treated and followed in a single pediatric neurosurgical service. Choice of treatment was performed very carefully to obtain the best clinical outcome and imaging properly, reducing the size of the cyst. Ciurea et al (2010)

All cases requiring follow predominantly by MRI to monitor the possible expansion of the cerebrale structures. In a significant number of cases the expected expansion did not occur because of the cyst membranes were not enough fenestrated into basal cisterns and CSF circulation not restored properly. In these cases depending on clinical aspects the therapeutical process can be repeated, minimally invasive by endoscopy.

Basically we can say that there is no "Best Treatment" in ACs, and each case must be analyzed separately. Ciurea et al (2010)

### Abbreviations:

ACs - intracranial arachnoid cysts  
 CSF - cerebro spinal fluid  
 CPA - cerebro-pontine angle  
 CPD - cisto-peritoneal drainage  
 MRI - magnetic resonance imaging  
 CT - computer tomography  
 ICP - intracranial pressure

### References

1. Anne G. Osborn: Arachnoid Cyst, Primary Nonneoplastic Cysts. Osborn (2010) 7: 6-9
2. Barbara Spacca, Jothy Kandasamy et al : Endoscopic treatment of middle fossa arachnoid cysts: a series of 40 patient treated endoscopically in two centres. in Childs Nerv Syst(2010) 26: 163-172
3. Bright R: Serous cysts of the arachnoid. Report of Medical cases vol 2, part 1, London: Longmans (1831)
4. Catala M, Poirier J. Arachnoid cysts: histologic, embryologic and physiopathologic review. Rev Neurol Paris (1998) 154:489-501.
5. Ciurea A.V et al: Treatment options in intracranial arachnoid cysts: 7th National Congress of Romanian Society of Neurosurgery, October 2010 Cluj Napoca Romania pub in Romanian Neurosurgery (2010) 4
6. C. di Rocco, L. D'Angelo, L. Massimi -Arachnoid cysts in Essential practice of neurosurgery Access Publishing Co. Ltd (2010) 1235-1244
7. Concezio Di Rocco : Sylvian fissure arachnoid cysts: we do operate on them but should it be done? in Childs Nerv Syst (2010) 26: 163-172
8. Fatih Ersay Deniz, Burkan Bilginer, Pinar Ozirik: Araknoid Kist He Birlikte Eozinofilik Graniilom: Vaka Sunumu Turkish Neurosurgery (2003) 13: 118-121,
9. Federico Di Rocco, Cyril R. James, Thomas Roujeau, Stephanie Puget, Christian Sainte-Rose , Michel Zerah: Limits of endoscopic treatment of sylvian arachnoid cysts in children. Childs Nerv Syst (2010) 26: 155-162
10. Gallasi E, Tohnetti F, Gaist G. et al.:CT scan and metrizamide CT cisternography in arachnoid cysts of the middle fossa: classification and pathophysiological aspects. Suerg Neurol. (1982) 17:363-369
11. Hopf N J, Perneczky A: Endoscopic neurosurgery and endoscope assisted microneurosurgery for the treatment of intracranial cyst. Neurosurgery (1998) 43 1330-7.
12. Keyvan Abtin and Marion I. Walker: Congenital arachnoid cysts and Dandy Walker complex. In Albright Principles and Practice of Pediatric Neurosurgery (2007) 7:125- 141



13. Rengachary SS, Watanabe I. Ultrastructure and pathogenesis of intracranial arachnoid cysts. *J Neuropathol Exp Neurol.* (1981) 40:61-83.
14. Pierre-Kahn A, Capelle L, Brauner R, et al: Presentation and management of suprasellar arachnoid cysts: Review of 20 cases. *J Neurosurg* (1990) 73:355-9
15. Mayr U, Aicher F, Bauer G et al: Supratentorial extracerebral cyst of the middle cranial fossa: A report of 23 consecutive cases of so called temporal lobe agenesis syndrome. *Neurochirurgia*(1982) 25: 51-6.
16. Rao G. et al Expansion of arachnoid cysts in children Report of two cases and review of the literature. *J Neurosurg (Pediatrics 3)* (2005)102:314–317.
17. Robinson R.G: Congenital cysts of the brain: arachnoid malformations. *Prog Neurol Surg*( 1971) 4:133–174.
18. Robinson R. G: The temporal lobe agenesis syndrome. *Brain* (1964) 88:87–106.
19. Russon. et al: Spontaneous reduction of intracranial arachnoid cysts: a complete review *British Journal of Neurosurgery*, October (2008), 22(5): 626–629
20. Tamburrini G. et al: Sylvian fissure arachnoid cysts: a survey on their diagnostic workout and practical management; *Childs Nerv Syst* (2008) 24:593–604
21. W. N. Al-Halou, C.O. Maher et al. The natural history of pineal cysts in children and young adults. in *Jurnal Neurosurg Pediatrics*(2010) 5: 162-166