

Imaging of vestibular schwannomas following γ -Knife treatment – a series of 79 cases

Charalampos Seferis

Hygeia Hospital, Athens, Greece, PhD Student in Neurosurgery, University of Medicine and Pharmacy “Gr.T. Popa” Iasi

Abstract

Gamma-Knife became an established therapeutic alternative for selected cases of vestibular schwannomas (benign tumors rooting from Schwann cells of vestibular nerve). However, the long term results and effects on the tumor and surrounding brain are still a matter of research. We analyze the imaging findings in the patients with vestibular schwannomas treated with gamma-knife radiosurgery in the Gamma-Knife Department, Hygeia Hospital, Athens.

We performed radiosurgery on 79 cases of vestibular schwannomas. 23 of them were first operated with incomplete resection and had gamma-knife performed on residual tumor. Of all cases, one patient died 4 years after the treatment, while 4 cases didn't comply with the follow-up protocol and were excluded from the study. The other cases underwent a follow-up protocol with MRI studies at 6, 12, 18, and 24 months following the gamma-knife session. We looked at the tumoral volume, and the evolution of the tumor in relationship with the irradiation dose and isodose curve.

Our results confirm the landmark results of Karolinska and Pittsburgh studies. We show that small gamma-knife doses are suitable for a satisfactory control of tumoral volume. Stereotactic MRI imaging and multiple doses programs are the main

factors contributing to these results.

Keywords: vestibular schwannoma, radiosurgery, gamma-knife, MRI

Introduction

Histologically, vestibular schwannomas are benign tumors that grow from the Schwann cells of the 8th cranial nerve. Due to improved neuroimaging the incidence of vestibular schwannomas within the general population increased.

However, despite the advances in intraoperative techniques, surgery still carries a risk for morbidity and mortality. Depending on tumor characteristics vestibular schwannomas can be treated by different methods, other than neurosurgery. Radiosurgery is one of these non-invasive techniques that can be used to treat vestibular schwannomas. It uses gamma radiation (photons) and is known as “Gamma-Knife” or “ γ -Knife”.

We analyze the imaging findings in the patients with vestibular schwannomas treated with gamma-knife radiosurgery in the Gamma-Knife Department, Hygeia Hospital, Athens.

Our results point to the fact that using small doses of radiation (similar to those used in the reference series from Karolinska and Pittsburgh) can control the volume of the lesion as shown by the follow-up controls results. Stereotactic MRI and a

multiple dosage program seem to be the main factors in achieving this result. According to published results the method can fail if the doctor decides not to partially exclude the lesions localized at superior limit of the treated region.

Materials and method

In the last six years (February 2004 – September 2010) 79 cases of vestibular schwannomas have been treated with gamma-knife radiosurgery in our unit. 23 patients have undergone surgery prior to gamma-knife, and had radiosurgery as an adjuvant therapy on remnant tumor. One patient died 4 years after the gamma-knife treatment because of pre-existing cardiac co-morbidities. 4 patients failed to comply with the follow-up protocol and were excluded from our study. 2 patients declared that their quality of life deteriorated as a result of radiosurgery.

To study the effects of radiation therapy the patients had to comply with a follow-up protocol that included MRI studies at 6, 12, 18, and 24 months after the treatment. The goal of follow-up was to monitor the volume of the schwannoma and to analyze the imaging aspects as a result of gamma-knife therapy. The radiation dose (Gy) and radiation isodose curve have been measured in relationship with their effect in controlling the progress of the tumors.

The average age of the patients included in our study was 55 years (22-74). Out of 79 cases 9 presented intracanalicular tumors, 19 developed intracanalicular and cisternal tumors, while 51 presented with tumors occupying the cerebello-pontine cistern (table 1.). the main tumor volume (V_m) was 4.72 cm^3 ($0.2-19.3 \text{ cm}^3$). The female to male ration was 51:28.

TABLE 2
Characteristics of the 79 vestibular schwannoma patients that underwent gamma-knife surgery

Parameters	Values
Median age (interval)	55 (27 - 74)
Female to male ratio	51:28
Tumor localization	
intracanalicular	9
cerebello-pontine cistern	51
both cisternal and intracanalicular	19
Previously treated	23
Medium volume in cm^3 (interval)	4,72 (0,20-19,3)

Gamma-knife therapy particularities

Gamma-knife radiosurgery is based on four principles:

1. "Target" localization, using neuro-imaging techniques, a stereotactic frame, and computer software to record and alter imaging data.
2. Computing lesion volume
3. Determining the distribution of radiation dose
4. Radiotherapy

During a radiosurgery session the median of isodose curve was 48.25%, with an interval of 40-54%.

Target localization is extremely important and excluding important cranial structures from being exposed to the gamma radiation (such as cranial nerves, cerebellum, and of course brain stem).

During treatment average marginal dose was 12.09 Gy (11 – 14 Gy), and maximal average dose was 19.83 Gy (20.5 – 29.9 Gy). Average tumor volume of treated

schwannomas was 4.72 cm³ (0.2 – 19.3 cm³).

To protect the undefined segments of the facial and trigeminal nerves that are prone to be included in the designated lesion volume, we administered in these areas doses below 13 and 15 Gy respectively. In two cases where the tumor had an occupying effect involving the brainstem the same dose didn't reach more than 10 Gy. All patients responded well to the treatment and were released the next morning after treatment completion. None reported neurological problems during hospitalization (such as epileptic seizures). Headache was present in 12 cases, most likely due to the stereotactic frame. To address these headaches patients were given oral pain killers for a short period of time (2-3 days) in the period following their release.

Follow-up

All patients, with one exception, underwent MRI imaging 6 months after the treatment. Six of them didn't present for the next follow-up session, at 12 months. MRI evaluation criteria included:

- Changes in the volume of the vestibular schwannoma
- Neuro-imagistic findings like: loss of central enhance (necrosis), local swelling through the cerebral ventricular system.

Results

The average follow-up period was of 24 months (1 – 51). 84.2% of the patients performed at least one MRI exploration at 6 months.

MRI evaluation

The solid part of the tumor reacted satisfactory to gamma-knife irradiation. As documented by the MRI images in the first

six months this response takes the shape of a central region of necrosis (seen in T1). According to published data this phenomena is noticed from the first month (or later than 23 months) and can extend within the tumor in the next 10 months (or even later than 60 months) after the treatment. A small percentage of the patients (11,8%) showed a swelling of the lesion. MRI findings at first follow-up match those reported in the literature in 34 cases. Only 2 cases showed a significant change in lesion volume in the 24 months period following gamma-knife therapy (from 0.71 cm³ to 1.1 cm³, and from 19.3 cm³ to 23.1 cm³), while the maximum reduction in tumor volume recorded in our series was from 12.4 to 2.7 cm³.

Discussion

Optimal radiation dosage for tumor control

Optimal radiation dosage for vestibular schwannoma control is still a matter of debate. A review of the literature showed a tendency to decreasing prescription dosage from 25-100 Gy used in the initial studies to 13 Gy in the current protocols. N ren, et al. have prescribed dosages of 25-35 Gy to the tumor periphery to ensure stopping tumor growth. However, high dose radiation has led to high morbidity due to facial and trigeminal nerve damage. In addition, possible preservation of hearing may be compromised when using a high dosage. First of all, a reduced radiation dose lowers the probability of cranial nerve neuropathy. Second of all, small doses have a better chance, at least in theory, to preserve hearing close to preoperative levels. Third of all, a lower dose should theoretically reduce or minimize the degree of swelling of the tumor that may occur after treatment.

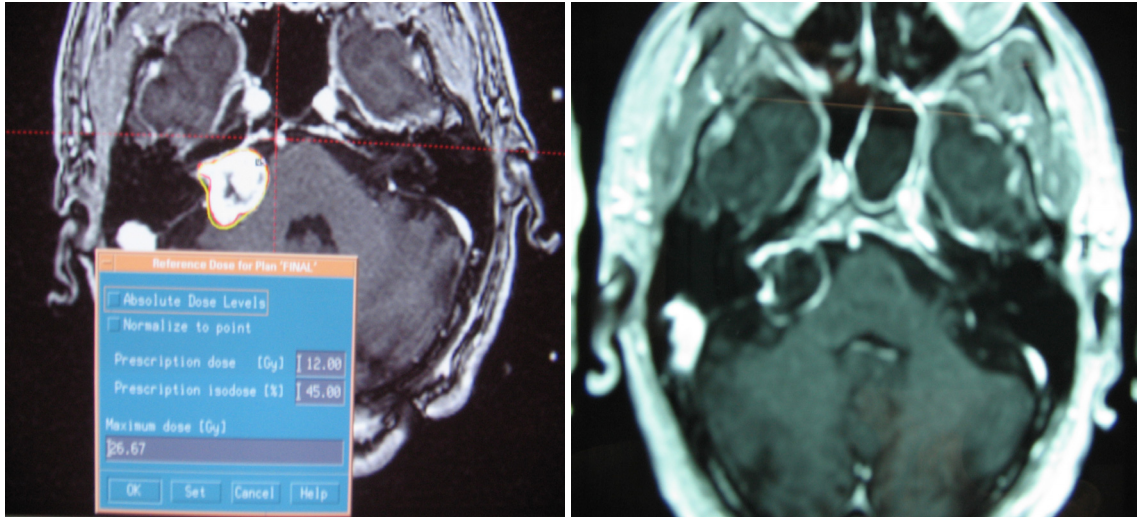


Figure 1 Left: Male, 62 yrs. Old, before therapy. Dose 12Gy (45%), volume 3,4 cm³.
Right: control at 6 months (central necrosis)

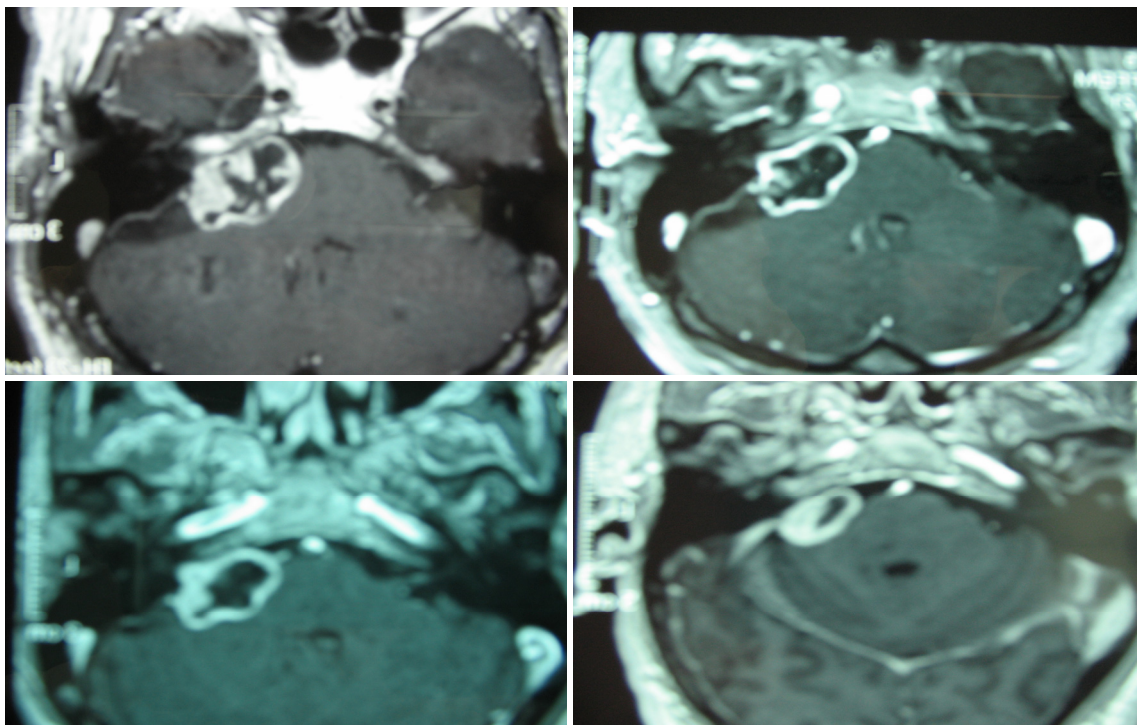


Figure 2 Upper left: Male, 73 yrs., before therapy. Dose 11 Gy, tumor volume 5.6 cm³.
At 24 months after gamma-knife tumor volume 3,1 cm³ (lower right). Dimensions before therapy:
3 cm x 2 cm, and after therapy: 2 cm x 1,4 cm.

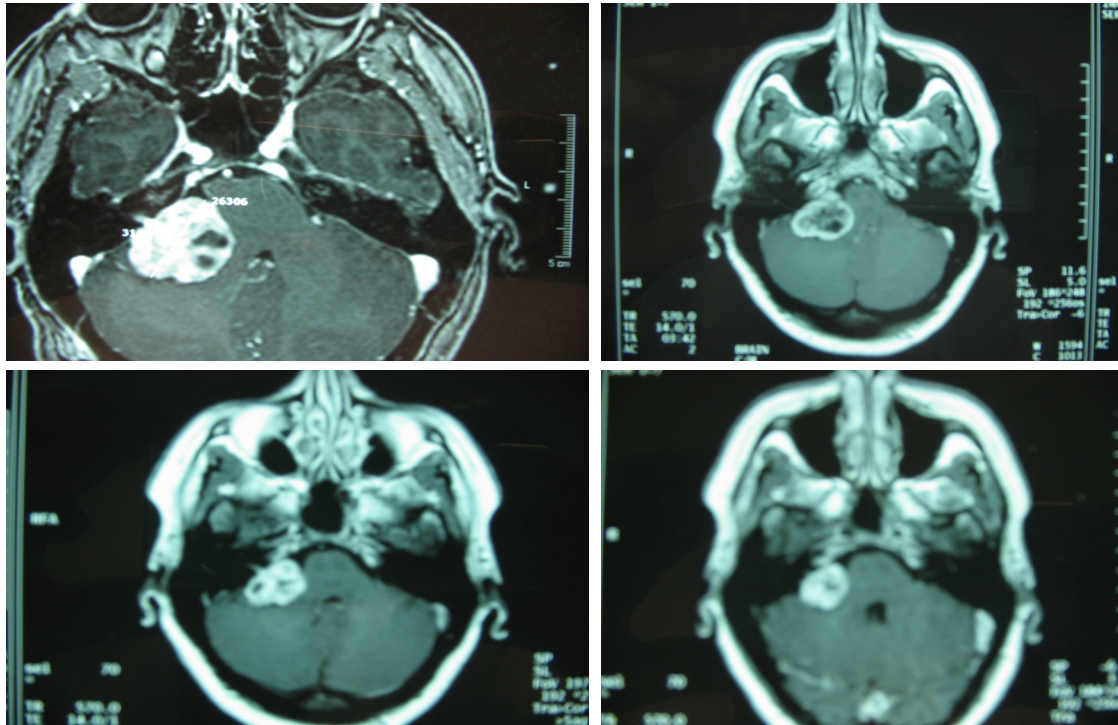


Figure 3 Female, 44 yrs., before therapy. Dose 11 Gy (50%). After 6, 12, and 24 months respectively. Tumor volume before therapy 12,4 cm³, 24 months after therapy 3cm³.

Larson et al. proposed the use of a single dose of 13.5 Gy, given the biological effect of delayed tissue response. Flickinger and ass. have questioned whether or not the tumor control rate could be reduced by a dose smaller than 13 Gy. In this study, we had satisfactory results in patients treated with a median marginal dose of 12.09 Gy (11-14 Gy). Thus, in our experience it is possible to obtain satisfactory long-term control of the tumor at a marginal dose less than 11 Gy. Tumor control rate was in no way worse than those reported in earlier series, where significantly higher doses were used.

Optimal dosage for preservation of cranial nerves

It has been suggested that the facial nerve tolerates marginal doses up to 15 Gy, but doses above 14 Gy have been shown to lead to a significant increase in neuropathy

incidence, particularly in the patients with large tumors. In the early days of radiosurgery, subjective numbness or hypoesthesia has been reported as major complication of trigeminal nerve radiation damage. The incidence was as high as 19% in both Karolinska and Pittsburgh series. The large tumoral volume and high radiation doses used corroborate to this undesirable consequence of radiation therapy. The incidence of trigeminal neuropathy was reduced to 4% transient neuropathy and 1.6% persistent neuropathy in Charlottesville experience, where the average marginal dose used was 13.2 Gy. In the present series, no patient developed any kind of sensory deficit. Preservation of hearing has become the main concern in advanced radiosurgery. In this study, 43 of 60 patients with good preoperative hearing, maintain a functional hearing during a

follow-up period of 21 months. Numerous studies have reported a total rate of 33-55% of hearing preservation in a 2-4 years period after treatment. A definite inverse correlation exists between the dimensions of the tumor and the probability of hearing preservation. Prasad and colleagues have reported a marginal inverse correlation between the dose used and the likelihood of hearing preservation, especially manifest at a dose higher than 13 Gy. In our series, neither the volume of the tumor nor the marginal dose appear to play a critical role in postoperative hearing preservation. In contrast, pure tone audiometry before Gamma Knife surgery seems to be a good possible measure for evaluating the results.

Loss of central contrast enhance

Loss of central enhancing on MRI imaging was observed in 54% of patients of Prasad et al., 70% of Nören, et al. and 63% of Flickinger, et al series. In this study, this phenomenon was observed in 63.3% of cases. This is a common observation after radiosurgery. More research is required to clarify the pathogenesis. Backlund reported that tumor necrosis was found in a histological study, which corresponds to the central region of enhanced MRI image. Seo, et al. showed using scanning with ⁹⁹Tc (human serum albumin - dietulenetriamin pentaacetic acid-photon) positron emission computed tomography reduced vascularization of vestibular schwannoma 1 to 2 years after radiosurgery,. Spiegelman and colleagues have suggested that ischemia was produced by tumor associated acute edema. Fukoka and colleagues suggested that apoptosis may be a possible mechanism. Based on these observations, it is acceptable to consider that the loss of radiological central enhancing is a reliable indicator of long-

term good control. This hypothesis, however, requires additional data from more patients and longer-term follow-up.

Failed treatment

In no case was there any evidence of active tumor growth. It has to be considered that labyrinth schwannomas can swell without regrowing after radiosurgery. It is suggested that the modest doses currently in use may reduce this tendency.

Conclusions

Using small doses of radiation (similar to those used in the reference series from Karolinska and Pittsburg, smaller than the usual doses used in other gamma-knife units) can control the volume of the lesion as shown by the follow-up controls results.

Stereotactic MRI and a multiple dosage program seem to be the main factors in achieving this result. According to published results the method can fail if the doctor decides not to partially exclude the lesions localized at superior limit of the treated region.

References

1. Andrews JC, Wackym PA, Canalis RF: Translabyrinthine approach to the cerebellopontine angle and internal auditory canal. In Samii M, Cheatham M, Becker DP (eds): Atlas of Cranial Base Surgery. Philadelphia, WB Saunders, 1995, pp 18-23.
2. Atkinson WJ: Anterior inferior cerebellar artery. J Neurol Neurosurg Psychiatry 12:137-151, 1949.
3. Backlund EO: Stereotactic radiosurgery in intracranial tumors and vascular malformations. Adv Tech Stand Neurosurg 6:3-37, 1979.
4. Burger PC, Scheithauer BW, Vogel FS: Surgical Pathology of the Nervous System and Its Coverings. New York, Churchill Livingstone, 1991.
5. Cairns H: Acoustic neurinoma of the right cerebellopontine angle: Complete removal. Spontaneous recovery from postoperative facial palsy. Proc R Soc Med 25:7-12, 1931.
6. Cerullo LJ, Grutsch JF, Heiferman K, Osterdock R: The preservation of hearing and facial nerve function in a consecutive series of unilateral vestibular nerve

- schwannoma surgical patients (acoustic neuroma). *Surg Neurol* 39:485-493, 1993.
7. Chung WY, Pan HC, Guo WY, et al: Protection of visual pathway in Gamma knife radiosurgery for craniopharyngiomas. *Stereotact Funct Neurosurg* 70 (Suppl 1):139-151, 1998.
8. Cross JP: Unilateral neurilemmomas of the VII-th cranial nerve: Then and now. *Am J Otol* 3:28-34, 1981.
9. Cushing H: Tumors of the Nervus Acusticus and the Syndrome of the Cerebellopontine Angle. Philadelphia, WB Saunders, 1917.
10. Dandy WE: An operation for the total removal of cerebellopontine (acoustic) tumors. *Surg Gynecol Obstet* 1:129-148, 1925. 38
11. Dandy WE: Removal of cerebellopontine (acoustic) tumors through a unilateral approach. *Arch Surg* 29:337-344, 1934.
12. Dandy WE: Results of removal of acoustic tumors by the unilateral approach. *Arch Surg* 42:1026-1033, 1941.
13. DituUio MV, Malkasian D, Rand RW: A critical comparison of neurosurgical and otolaryngological approaches to acoustic neuromas. *J Neurosurg* 48:1-12, 1978.
14. Ebersold MJ, Hamer SG, Beatty CW, et al: Current results of the retrosigmoid approach to acoustic neurinoma. *J Neurosurg* 76:901-909, 1992.
15. Fischer G, Fischer C, Remond J: Hearing preservation in acoustic neurinoma surgery. *J Neurosurg* 76:910-917, 1992.
16. Flickinger JC, Kondziolka D, Lunsford LD: Dose and diameter relationships for facial, trigeminal, and acoustic neuropathies following acoustic neuroma radiosurgery. *Radiother Oncol* 41: 215-219, 1996.
17. Flickinger JC, Kondziolka D, Niranjan A, et al: Results of acoustic neuroma radiosurgery: an analysis of 5 years, experience using current methods. *J Neurosurg* 94:1-6, 2001.
18. Foster DMC, Kemeny AA, Pathak, et al: Radiosurgery: a minimally interventional alternative to microsurgery in the management of acoustic neuroma. *Br J Neurosurg* 10:169-174, 1996.
19. Fukuoka S, Oka K, Seo Y, et al: Apoptosis following gamma knife radiosurgery in a case of acoustic schwannoma. *Stereotact Funct Neurosurg* 70 (Suppl 1):88-94, 1998.
20. Gantz BJ, Wackym PA: Facial nerve abnormalities. In Bumstead R, Smith J (eds): *Pediatric Facial Plastic and Reconstructive Surgery*. New York, Raven Press, 1993, pp 337-347.
21. Gardner G, Robertson JH: Hearing preservation in unilateral acoustic neuroma surgery. *Ann Otol Rhinol Laryngol* 97:55-66, 1988.
22. Glasscock ME, Poe DS, Johnson GD: Hearing preservation in surgery of cerebellopontine angle tumors. In Fisch U, Valavanis A, Yasargil M (eds): *Proceedings of the Sixth International Symposium of Neurological Surgery of the Ear and Skull Base*. Zurich, Kugler & Ghediru, 1988, pp 207-216.
23. Hardy RWJ, Kinney SE, Lueders H, Lesser RP: Preservation of cochlear nerve function with aid of brain stem auditory evoked Potentials. *Neurosurgery* 11:16-19, 1982.
24. Horrax G, Poppen JL: Experiences with the total and intracapsular extirpation of acoustic neuromata. *Ann Surg* 110:513-524, 1939.
25. Horrax G: A comparison of results after intracapsular enucleation and total extirpation of acoustic tumors. *J Neurol Neurosurg Psychiatry* 13:268-270, 1950.
26. House JW, Brackmann DE: Facial nerve grading system. *Otolaryngol Head Neck Surg* 93:146-147, 1985.
27. House WF, Hitselberger WE: *Fatalities in Acoustic Tumor Surgery*, vol 2. Baltimore, University Park Press, 1979, pp 235-264.
28. House WF: Case summaries. *Arch Otolaryngol* 88:586-591, 1968.
29. House WF: Monograph I: Transtemporal bone microsurgical removal of acoustic neuromas. *Arch Otolaryngol* 80:587-756, 1964.
30. House WF: Monograph II: Acoustic neuroma. *Arch Otolaryngol* 88:576-715, 1968.
31. House WF: *Transtemporal Approach*, vol 2. Baltimore, University Park Press, 1979, pp 43-87, 12:137-151, 1949.
32. Jackler RK, Brackmann DE (eds): *Neurotology*. St. Louis, Mosby-Year Book, 1994.
33. Jenkins HA: Hearing preservation in acoustic neuroma surgery. *Laryngoscope* 102:125-128, 1992.
34. Kanzaki I, Kunihiro T, O-Uchi T, et al: Preservation of facial I nerve function in acoustic neuroma surgery by extended middle fossa approach. *Acta Otolaryngol Suppl* 487:36-40, 1991.
35. Kanzaki J, Ouchi T, Shiobara R, Toya S: Hearing preservation in acoustic neuroma surgery by the extended middle fossa method. *Otolaryngol Suppl Acta* 487:22-29, 1991.
36. Kaplan EL, Meier P: Nonparametric estimation from incomplete observations. *J Am Stat Assoc* 53:457-481, 1958.
37. Kartush JM, Lundy LB: Facial nerve outcome in acoustic neuroma surgery. *Otolaryngol Clin North Am* 25:623-647, 1992.
38. Kondziolka D, Lunsford LD, McLaughlin MR, et al: Long-term outcomes after radiosurgery for acoustic neuromas. *N Engl J Med* 339:1426-1433, 1998.
39. Kwartler JA, Luxford WM, Atkins J, Shelton C: Facial nerve monitoring in acoustic neuroma surgery. *Otolaryngol Head Neck Surg* 104:814-517, 1991.
40. Lalvvani AK, Butt FY, Jackler RK, et al: Facial nerve outcome after acoustic neuroma surgery: A study from the era of cranial nerve monitoring. *Otolaryngol Head Neck Surg* 111:561-570, 1994.

41. LaRouere MJ, Niparko JK, Gebarski SS, Kemink JL: Three-dimensional x-ray computed tomography of the temporal bone as an aid to surgical planning. *Otolaryngol Head Neck Surg* 103:740-747, 1990.
42. Larson DA, Flickinger JC, Loeffler JS: The radiobiology of radiosurgery. *Int J Radiat Oncol Biol Phys* 25:557-561, 1993.
43. Linskey ME, Lunsford LD, Flickinger JC: Neuroimaging of acoustic nerve sheath tumors after stereotactic radiosurgery. *AJNR Am J Neuroradiol* 12:1165-1175, 1991.
44. Linskey ME, Lunsford LD, Flickinger JC: Neuroimaging of acoustic nerve sheath tumors after stereotactic radiosurgery. *AJNR Am J Neuroradiol* 12:1165-1175, 1991.
45. Linskey ME, Lunsford LD, Flickinger JC: Radiosurgery for acoustic neurinoma: early experience. *Neurosurgery* 26: 736-745, 1990.
46. List CF: Die operative behandlung die acoustic neurinoma mit drei ergebnisse. *Arch U Klin Chir* 171:282-325, 1932.
47. Lunsford LD, Kameron DB, Møller M: Gamma knife: an alternative treatment for acoustic neurinomas. *Ann Otol Rhinol Laryngol* 97:631-635, 1988.
48. Lye RH, Dutton J, Ramsden RT: Facial nerve preservation during surgery for removal of acoustic nerve tumors. *J Neurosurg* 57:739-743, 1982.
49. Mafee MF, Kumar A, Valvassori GE, et al: Diagnostic potential of CT in neurological disorders. *Laryngoscope* 95:505-514, 1985.
50. McKenzie KG, Alexander EJ: Acoustic neuroma. *Clin Neurosurg* 2:21-36, 1955.
51. Moller AR, Janetta PJ: Preservation of facial function during removal of acoustic neuromas. *J Neurosurg* 61:757-760, 1984.
52. Mrazek J, Fisur Z, Mazkora D: Diagnosis, size, and operation results in 41 acoustic neurinomas. *Neoplasma* 35:467-474, 1988.
53. Nedzelski JM, Tatar CH: Hearing preservation: A realistic goal in surgical removal of cerebellopontine angle tumors. *J Otolaryngol* 13:355-360, 1984.
54. Neely JG: Hearing conservation surgery for acoustic tumors: A clinical-pathologic correlative study. *Am J Otol* 6:143-146, 1985.
55. Neely JG: Is it possible to totally resect an acoustic tumor and conserve hearing? *Otolaryngol Head Neck Surg* 92:162-167, 1984.
56. Norén G, Arndt J, Hindmarsh T: Stereotactic radiosurgery in cases of acoustic neurinoma: further experiences. *Neurosurgery* 13: 12-22, 1983.
57. Norén G, Greitz D, Hirsh A, et al: Gamma knife radiosurgery in acoustic tumors. *Acta Neurochir Suppl* 58:104-107, 1993.
58. Norén G: Gamma knife radiosurgery in acoustic neuromas, in Haid C (ed): *Vestibular Diagnoses and Neurootological Management of the Skull Base*. Gräefelng: Demeter Verlag, pp 43-45, 1991.
59. Ogunrinde OK, Lunsford LD, Kondziolka, et al: Cranial nerve preservation after stereotactic radiosurgery of intracanalicular acoustic tumors. *Stereotact Funct Neurosurg* 64 (Suppl 1): 87-97, 1995.
60. Olivecrona H: Acoustic tumors. *J Neurosurg* 26:6-13, 1967.
61. Olivecrona H: Analysis of results of complete and partial removal of acoustic neuromas. *J Neurol Neurosurg Psychiatry* 13: 271-272, 1950.
62. Poole JL, Pava AA: *The Early Diagnosis and Treatment of Acoustic Nerve Tumors*. Springfield, IL, Charles C Thomas, 1957.
63. Poole JL: Suboccipital surgery for acoustic neurinomas: Advantages and disadvantages. *J Neurosurg* 24:483-492, 1966.
64. Post K, Eisenberg MB, Catalano PJ: Hearing preservation in vestibular schwannoma surgery: What factors influence outcome? *J Neurosurg* 83:191-196, 1995.
65. Prasad D, Steiner M, Steiner L: Gamma surgery for vestibular schwannoma. *J Neurosurg* 92:745-759, 2000.
66. Prasad S, Hirsch BE, Kameron DB, et al: Facial nerve function following cerebellopontine angle surgery: Prognostic value of intraoperative thresholds. *Am J Otol* 14:330-333, 1993.
67. Rand RW, Kurze T: Case reports and technical notes: Preservation of vestibular, cochlear and facial nerves during microsurgical removal of acoustic tumors—report of two cases. *J Neurosurg* 28:158-161, 1968.
68. Rand RW: *Microneurosurgery for acoustic tumors*. In *Microneurosurgery*. St. Louis, CV Mosby, 1969, pp 126-155.
69. Samii M, Matthies C: Management of 1000 vestibular schwannomas (acoustic neuromas): Hearing function in 1000 tumor resections. *Neurosurgery* 40:248-260, 1997.
70. Samii M, Matthies C: Management of 1000 vestibular schwannomas (acoustic neuromas): The facial nerve-preservation and restitution of function. *Neurosurgery* 40:684-694, 1997.
71. Samii M, Matthies C: Management of 1000 vestibular schwannomas (acoustic neuromas): Surgical management and results with emphasis on complications and how to avoid them. *Neurosurgery* 40:11-21, 1997.
72. Samii M, Matthies C: Management of 1000 vestibular schwannomas (acoustic neuromas): surgical management and results with an emphasis on complications and how to avoid them. *Neurosurgery* 40:11-23, 1997.
73. Sampath P, Holliday MJ, Brem H, et al: Facial nerve injury in acoustic neuroma (vestibular schwannoma) surgery: Etiology and prevention. *J Neurosurg* 87:60-66, 1997.

74. Sampath P, Holliday MJ, Brem H, et al: Facial nerve injury in acoustic neuroma (vestibular schwannomas) surgery: etiology and preservation. *J Neurosurg* 87:60–66, 1997.
75. Sampath P, Holliday MJ, Brem H, et al: Prevention of facial nerve injury in vestibular schwannoma surgery. *Neurosurg Focus* 5:4, 1998.
76. Sampath P, Rhines LD, Goel R, Long DM: Cranial nerve preservation in vestibular schwannoma (acoustic neuroma) surgery. *Crit Rev Neurosurg* 8:86–96, 1998.
77. Selesnick SH, Jacker RK: The changing clinical presentation of acoustic tumors in the MRI era. *Laryngoscope* 103:431–436, 1993.
78. Seo Y, Fukuoka S, Nakagawara J, et al: Effect of gamma knife radiosurgery on acoustic neurinomas. Assessment by ^{99m}Tc -DPTA-human serum albumin and ^{201}Tl -single photon emission computed tomography. *Stereotact Funct Neurosurg* 66 (Suppl 1): 93–102, 1997.
79. Spiegelmann R, Lidar Z, Gofman J, et al: Linear accelerator radiosurgery for vestibular schwannoma. *J Neurosurg* 94:7–13, 2001.
80. Sterkers JM, Morrison GA, Sterkers O, Badr El-Dine MMK: Preservation of facial, cochlear, and other nerve functions in acoustic neuroma treatment. *Otolaryngol Head Neck Surg* 110:146–155, 1995.
81. Sterkers JM, Morrison GA, Sterkers O, El-Dine MM: Preservation of facial, cochlear, and other nerve functions in acoustic neuroma treatment. *Otolaryngol Head Neck Surg* 110:146–155, 1994.
82. Tator CH, Nedzelski JM: Preservation of hearing in patients undergoing excision of acoustic tumors and other cerebellopontine angle tumors. *J Neurosurg* 63:168–174, 1985.
83. Tos M, Thomsen J: Ten years' experience with translabyrinthine acoustic neuroma surgery in Denmark. *Acta Otolaryngol Suppl* 449:2S–24, 1988.
84. Varlotto JM, Shrieve DS, Alexander E III, et al: Fractionated stereotactic radiotherapy for the treatment of acoustic neuromas: preliminary results. *Int J Radiat Oncol Biol Phys* 36:141–145, 1996.
85. Wackym PA, Andrews JC: Middle cranial fossa approach. In Samii M, Cheatham M, Becker DP (eds): *Atlas of Cranial Base Surgery*. Philadelphia, WB Saunders, 1995, pp 26–31.
86. Wackym PA, Linthicum FH Jr: Diabetes mellitus and hearing loss: Clinical and histopathological relationships. *Am J Otol* 7: 176–182, 1986.
87. Wackym PA, Rice DH, Schaefer SD (eds): *Minimally Invasive Surgery of the Head, Neck, and Cranial Base*. Philadelphia, Lippincott Williams & Wilkins, 2002, pp 1–559.
88. Whittaker CK, Luetje CM: Vestibular schwannomas. *J Neurosurg* 76:897–900, 1992.
89. Yasargil MG, Fox JL: The microsurgical approach to acoustic neurinomas. *Surg Neurol* 2:393–398, 1974.
90. Yasargil MG, Smith RD, Gasser JC: Microsurgical approach to acoustic neurinomas. *Adv Tech Stand Neurosurg* 4:93–197, 1977.
91. Yasargil MG: A legacy of microneurosurgery: Memoirs, lessons, and axioms. *Neurosurgery* 45:1025–1091, 1999.