



# Hydatid cyst of the quadrigeminal cistern. A case report for unusual location with literature review

Saif Saood Abdelrazaq<sup>1</sup>, Abdullah H. Al Ramadan<sup>2</sup>,  
Ali Adnan Dolachee<sup>3</sup>, Mohammed Maan  
AbdulAzeez<sup>4</sup>, Ali Saud Abdulrazzaq<sup>5</sup>, Amar Saeed  
Rashid<sup>6</sup>, Samer S. Hoz<sup>5</sup>

<sup>1</sup> Neurosurgery Department, Al Sadar Teaching Hospital, Najaf, IRAQ

<sup>2</sup> Department of Neurosurgery, King Faisal Specialist Hospital and Research Centre, Riyadh, SAUDI ARABIA

<sup>3</sup> Department of Neurosurgery, College of Medicine, Al Qadisiyah University, IRAQ

<sup>4</sup> College of Medicine, University of Baghdad, Baghdad, IRAQ

<sup>5</sup> Neurosurgery Department, Neurosurgery Teaching Hospital, Baghdad, IRAQ

<sup>6</sup> Department of Neurosurgery, College of Medicine, Kufa University, Baghdad, IRAQ

## ABSTRACT

Intracranial hydatid cyst involves supratentorial area and mainly affecting the middle cerebral artery territory with the predilection of the partial lobe. It can be single - which is the most common - or multiple up to 35 cysts. They tend to be huge at the time of symptomatic presentation especially when they are presented as a solitary lesion with a slow growth rate around 1.5 cm/year, however, it is variable and it can be up to 10 cm/year. Surgical treatment is mandatory for all patients once the correct diagnosis is made, except for patients with multiple organ involvement in poor general conditions and deep-located cysts. The existence of hydatidosis in the cisternal spaces must not be neglected given the capacity of *E. granulosus* larvae to disseminate via the CSF. In this case report; two and half years' male child presented with a history of 2 attacks of generalized seizure for the last 72 hours with the head circumference at the upper normal limit for his age. This paper presents the first case report demonstrating a primary single hydatid cyst located in the quadrigeminal cistern in a child. We concluded that in spite of the feasibility of the imaging and the high suspension of cerebral hydatid cyst, still, the reports show more locations which can be described as unusual although for a head to toe suspected distribution of hydatid disease is already understood. An eminent medical and surgical (if indicated) treatment of the primary cerebral hydatid cyst are always effective and recommended.

## INTRODUCTION

Choroid Echinococcosis could be characterized as a zoonotic infestation caused by cestode species of the genus *Echinococcus* (1).

---

**Keywords**  
neurosurgery,  
hydatid,  
quadrigeminal cistern,  
case report

---



Corresponding author:  
**Mohammed Maan AbdulAzeez**

College of Medicine, University of  
Baghdad,  
Baghdad University, Iraq

mohammed.wwt@gmail.com

**Copyright and usage.** This is an Open Access article, distributed under the terms of the Creative Commons Attribution Non-Commercial No Derivatives License (<https://creativecommons.org/licenses/by-nc-nd/4.0/>) which permits non-commercial re-use, distribution, and reproduction in any medium, provided the original work is unaltered and is properly cited.

The written permission of the Romanian Society of Neurosurgery must be obtained for commercial re-use or in order to create a derivative work.

ISSN online 2344-4959  
© Romanian Society of  
Neurosurgery



First published  
June 2019 by  
London Academic Publishing  
[www.lapub.co.uk](http://www.lapub.co.uk)

It is most commonly involving the liver then lungs. (2) Intracranial involvement occurs in 1-2% of Echinococcosis and 50-70% of these cases affect the paediatric age group. (3) It showed slightly male preference in most of the case series. (4,5,6,7,8) Geographically endemic area of hydatid disease includes some of South America countries like Argentina, Brazil, Chile, Peru and Uruguay, France, Italy and Greece in Europe, Turkey, Israel, Lebanon, Syria and Jordan in the Middle East, China, Iran, and India in Southeast Asia and Tunisia in Africa. (9)

Intracranial hydatid cyst involves supratentorial area and mainly affecting the middle cerebral artery territory with the predilection of the partial lobe. It can be single - which is the most common - or multiple up to 35 cysts. (10,11,12) They tend to be huge at the time of symptomatic presentation especially when they are presented as a solitary lesion with a slow growth rate around 1.5 cm/year, however, it is variable and it can be up to 10 cm/year. (13) Surgical treatment is mandatory for all patients once the correct diagnosis is made, except for

patients with multiple organ involvement in poor general conditions and deep-located cysts. (14) The existence of hydatidosis in the cisternal spaces must not be neglected given the capacity of *E. granulosus* larvae to disseminate via the CSF. (15)

This paper presents the first case report demonstrating a primary single hydatid cyst located in the quadrigeminal cistern in a child.

#### CASE SCENARIO

Two and half years' male child presented with history of 2 attacks of generalized seizure for the last 72 hours with head circumference at the upper normal limit for his age.

Initial lab workup was done to exclude metabolic derangements the patient was sent for neuroimaging. The general lab tests were within normal ranges and the brain MRI showed a midline rounded cystic lesion, 5x3 cm in size, located in extra-axially in the quadrigeminal cistern and extend infra-tentorially to compress the cerebellum downward along with bilateral dilated lateral ventricles (FIGURE 1).

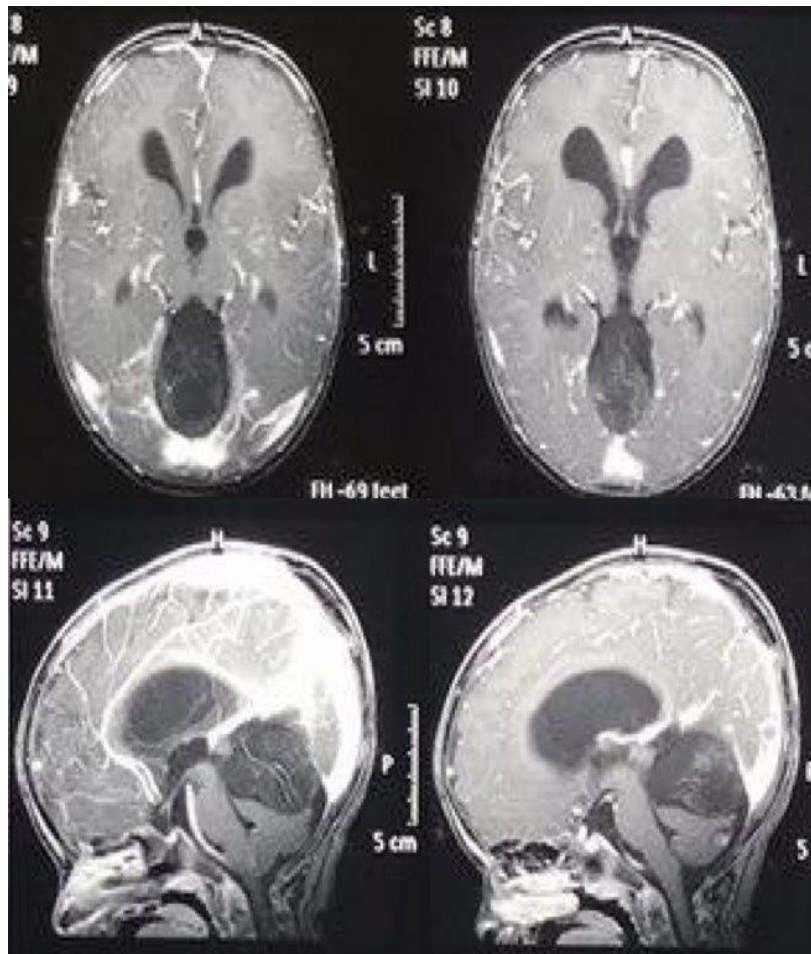
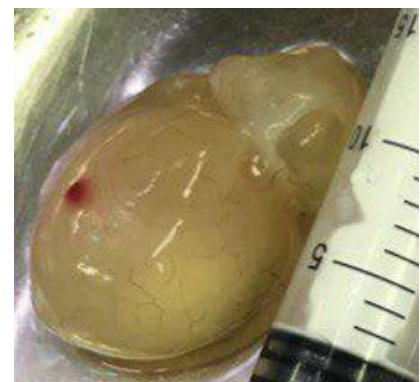

FIGURE 1. Pre-operative brain MRI showing a midline rounded cystic lesion, 5x3 cm in size, located in extra-axially in the quadrigeminal cistern and extend infra-tentorially to compress the cerebellum downward along with bilateral dilated lateral ventricles. The lesion was hypointense and homogenous in T1 with intensity higher than CSF, hyper-intense in T2 and showed no enhancement in contrasted image, also there was some vivid inclusions within the upper part of the cyst.

FIGURE 2. the delivered intact hydatid cyst.



The lesion was hypo-intense and homogenous in the T1 sequence of the MRI with intensity higher than the CSF, hyperintense in the T2, and showed no enhancement in the contrasted image, also there were some vivid inclusions within the upper part of the cyst.

At that point, the top differential diagnosis included were epidermoid, dermoid and arachnoid cysts only, because that location was an unusual location for a hydatid cyst and the age of the patient was too young for a hydatid cyst.

The decision was to do a surgical resection or fenestration according to the intra-operative

findings. we planned to delay the CSF shunting option as the sulci were not effaced, the young age of the patient and the surgery would remove the cause of the obstruction of the CSF pathways.

The surgery conducted at the next day, an intratentorial supra-cerebellar approach was done via midline occipital craniotomy. The cyst was a typical hydatid cyst. The cyst resected as one piece via initial dissection and then delivered using Dowling's hydrodissection technique (FIGURE 2,3).

The postoperative course went uneventfully. The histopathology confirms the diagnosis, further workup excluded other organs involvement.

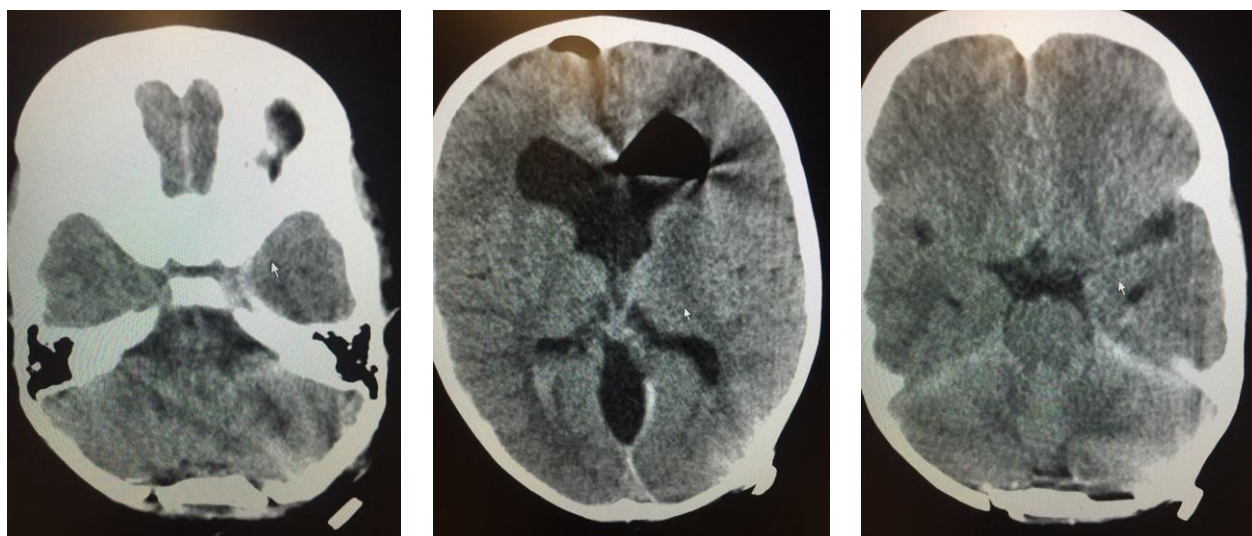


FIGURE 3. Early postoperative axial brain CT scan showing resection cavity

TABLE 1. Intracranial Cisternal Hydatid cysts: Case Report in English Literature

No.	Authors	Age/Gender	Complain	Diameter	Location	Treatment
1	Rumboldt et al (27)	50 Year/ Male	Headache	30 mm	Premedullary Cisten	Surgery
2	Beskonakli et al (28)	33 Year/ Male	Headache and impair vision	N/A	Interpeduncular Cistern	Surgery
3	Sanli et al (29)	7 Year/ Male	Symptoms of high Intracranial pressure	25 x 25 mm	Ambient Cistern	Surgery
4	Kizilca et al (37)	45 Year/ Female	Symptoms of high Intracranial pressure	N/A	Premedullary Cisten	Surgery
5	The authors of this case report	2.5 Year/ Male	Seizure	50 x 30 mm	Quadrigeminal Cistern	Surgery

## DISCUSSION

Variant locations of hydatid cyst were reported in the literature including aqueduct of Sylvius (16), Frontal lobe associated with massive edema and raise in the intracranial pressure (17), temporal lobe with midbrain herniation. (18)

Thalamic hydatid cyst was managed surgically through the transcallosal approach in a child who presented with left-sided weakness. (19)

An interosseous lesion involving the skull estimated to represent 3-4% of the lesion involving the skeleton which evident in 2% of all hydatid cyst. (20)

Spinal hydatid cysts are estimated at less than 1%, they are usually extradural and tend to rupture intraoperative more than other location. (21)

Meckel's cave can be involved with extension to the Cerebellopontine angle and the middle fossa. (22)

Brainstem hydatid cyst was reported in middle age woman presented with a headache and progressive hemiparesis. (23) both cases of Meckel's cave and Brainstem hydatid cysts were treated with decompression first prior to the removal to decrease the chances of intraoperative rupture. (22,23)

Cerebellar lesion with mass effect causing obstructive hydrocephalus was encountered in a child with a progressive headache followed by signs and symptoms of high intracranial pressure. (24)

Intraventricular involvement was estimated between 1.3 - 16.6% of multiple case series for intracranial hydatid disease with overall good outcome after surgical excision. (25) Other unusual locations include the seller and the para-sellar regions were reported. (26)

Cisternal hydatid cysts were reported to involve the pre-medullary, the interpeduncular and the ambient cisterns. (27,28,29) (Table 1)

An intermittent headache can be the only presenting symptoms even with a huge cyst. (30) In a Large series from China, headache and vomiting were the most common symptoms, this finding was supported in the literature as well.

Seizure attacks, focal neurological deficits, and skull deformities were reported. Papilledema was frequent in the ophthalmological examination especially in patients with high intracranial pressure, optic atrophy was seen as well. (4,31,32)

The Magnetic Resonance Imaging (MRI) thought to be more sensitive than the computed tomography (CT) to identify the pericystic layer and to

differentiated the hydatid cyst from the other similar cystic lesions like the epidermoid cyst, however, CT scan is more sensitive to identify the calcified lesions. (33)

Serious complications related to the rupture of the hydatid cyst include recurrence, cerebral vasospasm and infarction, hydrocephalus, anaphylactic shock, chemical meningitis, and even death. (34)

In two series of long-term follow up for cerebral hydatidosis in children, it can be concluded that the improvements of the imaging facilities lead to early recognition and improve the outcome. Poor prognostic factors can be identified including delay in the treatment, the rupture of the cyst at the presentation or intraoperatively, and poor control of the systemic disease. Single versus multiple cyst and age at the presentation was not identified as prognostic factors, however, some authors consider the multiplicity as a malignant form of the disease. (35,36)

Review of all the available literature reveals that our case is the first reported case of hydatid cyst located in the quadrigeminal cistern which was removed successfully.

## CONCLUSION

In spite of the feasibility of the imaging and the high suspension of cerebral hydatid cyst, still, the reports show more locations which can be described as unusual although for a head to toe suspected distribution of hydatid disease is already understood. An eminent medical and surgical (if indicated) treatment of the primary cerebral hydatid cyst are always effective and recommended.

## ABBREVIATIONS

CT: computed tomography  
MRI: magnetic resonance imaging  
CSF: cerebrospinal fluid

## REFERENCES

- Eckert J, Deplazes P. Biological, epidemiological, and clinical aspects of echinococcosis, a zoonosis of increasing concern. *Clin Microbiol Rev.* 2004 Jan;17(1):107-35. Review. PubMed PMID: 14726458; PubMed Central PMCID: PMC321468.
- Madeo J, Zheng X, Ahmed S, Ramos De Oleo R. Primary cerebral echinococcosis presenting as long-standing generalized weakness. *Germs.* 2013 Jun 1;3(2):63-6. doi: 10.11599/germs.2013.1038. eCollection 2013 Jun 1.



- PubMed PMID: 24432288; PubMed Central PMCID: PMC3882828.
3. Erşahin Y, Mutluer S, Güzelbağ E. Intracranial hydatid cysts in children. *Neurosurgery*. 1993 Aug; 33(2): 219-24; discussion 224-5. PubMed PMID: 8367043.
  4. Turgut M. Intracranial hydatidosis in Turkey: its clinical presentation, diagnostic studies, surgical management, and outcome. A review of 276 cases. *Neurosurg Rev*. 2001 Dec;24(4):200-8. Review. PubMed PMID: 11778827.
  5. Khaldi M, Mohamed S, Kallel J, Khouja N. Brain hydatidosis: report on 17 cases. *Childs Nerv Syst*. 2000 Nov;16(10-11):765-9. PubMed PMID: 11151730.
  6. Kocaman S, Ersahin Y, Mutluer S. Cerebral hydatid cysts in children. *J Neurosci Nurs*. 1999 Oct;31(5):270-7. PubMed PMID: 10633303.
  7. Duishanbai S, Jiafu D, Guo H, Liu C, Liu B, Aishalong M, Mijiti M, Wen H. Intracranial hydatid cyst in children: report of 30 cases. *Childs Nerv Syst*. 2010 Jun;26(6):821-7. doi: 10.1007/s00381-009-1008-2. Epub 2009 Dec 16. PubMed PMID: 20013283.
  8. Limaiem F, Bellil S, Bellil K, Chelly I, Mekni A, Khaldi M, Haouet S, Zitouna M, Kchir N. Primary hydatidosis of the central nervous system: a retrospective study of 39 Tunisian cases. *Clin Neurol Neurosurg*. 2010 Jan;112(1):23-8. doi: 10.1016/j.clineuro.2009.09.001. Epub 2009 Sep 24. PubMed PMID: 19781849.
  9. Nourbakhsh A, Vannemreddy P, Minagar A, Toledo EG, Palacios E, Nanda A. Hydatid disease of the central nervous system: a review of literature with an emphasis on Latin American countries. *Neurol Res*. 2010 Apr;32(3):245-51. doi: 10.1179/016164110X12644252260673. Review. PubMed PMID: 20406602.
  10. Ali M, Mahmood K, Khan P. Hydatid cysts of the brain. *J Ayub Med Coll Abbottabad*. 2009 Jul-Sep;21(3):152-4. PubMed PMID: 20929036.
  11. Sen N, Laha D, Gangopadhyay PK, Mohanty BC. Young girl with multiple intracranial hydatid cyst. *Ann Neurosci*. 2012 Apr;19(2):96-8. doi: 10.5214/ans.0972.7531.12190212. PubMed PMID: 25205976; PubMed Central PMCID: PMC4117048.
  12. Binesh F, Mehrabani M, Navabii H. Primary brain hydatosis. *BMJ Case Rep*. 2011 Mar 8;2011. pii: bcr0620103099. doi: 10.1136/bcr.06.2010.3099. PubMed PMID: 22707660; PubMed Central PMCID: PMC3063272.
  13. Thakur SH, Joshi PC, Kelkar AB, Seth N. Unusual presentation of hydatid cyst - ruptured intraventricular hydatid. *Indian J Radiol Imaging*. 2017 Jul-Sep;27(3):282-285. doi: 10.4103/ijri.IJRI\_70\_16. PubMed PMID: 29089673; PubMed Central PMCID: PMC5644318.
  14. Yurt A, Avci M, Selçuki M, Ozer F, Camlar M, Uçar K, Taşlı F, Altınörs N. Multiple cerebral hydatid cysts. Report of a case with 24 pieces. *Clin Neurol Neurosurg*. 2007 Nov; 109(9): 821-6. Epub 2007 Aug PubMed PMID: 17765392.
  15. Andronikou S, Welman CJ, Kader E. Classic and unusual appearances of hydatid disease in children. *Pediatr Radiol*. 2002 Nov;32(11):817-28. Epub 2002 Aug 16. PubMed PMID: 12389111.
  16. Gökalp HZ, Erdoğan A. Hydatid cyst of the aqueduct of Sylvius. Case report. *Clin Neurol Neurosurg*. 1988;90(1):83-5. PubMed PMID: 3359737.
  17. Bahloul K, Ouerchefani N, Kammoun B, Boudouara MZ. Unusual brain edema caused by an intracranial hydatid cyst: a case report and literature review. *Neurochirurgie*. 2009 Feb;55(1):53-6. doi: 10.1016/j.neuchi.2008.03.008. Epub 2008 Jun 30. Review. PubMed PMID: 18586282.
  18. Duransoy YK, Mete M, Barutçuoğlu M, Unsal UÜ, Selçuki M. Intracranial hydatid cyst is a rare cause of midbrain herniation: A case report and literature review. *J Pediatr Neurosci*. 2013 Sep 8(3): 224-7. doi: 10.4103/1817-1745.123683. PubMed PMID: 24470819; PubMed Central PMCID: PMC3888042.
  19. Erşahin Y, Mutluer S, Dermirtaş E, Yurtseven T. A case of thalamic hydatid cyst. *Clin Neurol Neurosurg*. 1995 Nov; 97(4): 321-3. PubMed PMID: 8599900.
  20. Erman T, Tuna M, Göçer I, İldan F, Zeren M, Cetinalp E. Intracranial intraosseous hydatid cyst. Case report and review of literature. *Neurosurg Focus*. 2001 Jul 15;11(1): ECP1. Review. PubMed PMID: 16724818.
  21. Luo K, Luo DH, Zhang TR, Wen H. Primary intracranial and spinal hydatidosis: a retrospective study of 21 cases. *Pathog Glob Health*. 2013 Mar;107(2):47-51. doi: 10.1179/2047773213Y.0000000072. PubMed PMID: 23683329; PubMed Central PMCID: PMC4001477.
  22. Taghipour M, Saffarian A, Ghaffarpasand F, Azarpira N. Dumbbell-Shape Hydatid Cyst of Meckel Cave Extending to Cerebellopontine Angle and Middle Fossa; Surgical Technique and Outcome of Rare Case. *World Neurosurg*. 2017 Aug;104 :1049.e7-1049.e10. doi: 10.1016/j.wneu.2017.05.091. Epub 2017 May 25. PubMed PMID: 28552738.
  23. Muthusubramanian V, Pande A, Vasudevan MC, Ravi R. Surgical management of brainstem hydatid cyst--an unusual site. *Surg Neurol*. 2009 Jan;71(1):103-6; discussion 106. doi: 10.1016/j.surneu.2007.06.077. Epub 2008 Feb 11. PubMed PMID: 18262629.
  24. Fakhouri F, Ghajar A, Mahli N, Shoumal N. Giant hydatid cyst in the posterior fossa of a child. *Asian J Neurosurg*. 2015 Oct-Dec;10(4):322-4. doi: 10.4103/1793-5482.162719. PubMed PMID: 26425166; PubMed Central PMCID: PMC4558813.
  25. Guzel A, Tatli M, Maciaczyk J, Altınors N. Primary cerebral intraventricular hydatid cyst: a case report and review of the literature. *J Child Neurol*. 2008 May;23(5):585-8. doi: 10.1177/0883073807309791. Epub 2008 Jan 11. Review. PubMed PMID: 18192651.
  26. Turgut M. Hydatidosis of central nervous system and its coverings in the pediatric and adolescent age groups in Turkey during the last century: a critical review of 137 cases. *Childs Nerv Syst*. 2002 Dec;18(12):670-83. Epub 2002 Oct 25. Review. PubMed PMID: 12483350.
  27. Rumboldt Z, Jednacac H, Talan-Hranilović J, Rumboldt T, Kalousek M. Unusual appearance of a cisternal hydatid cyst. *AJNR Am J Neuroradiol*. 2003 Jan;24(1):112-4. PubMed PMID: 12533337.

28. Beskonakli E, Solaroglu I, Tun K, Albayrak L. Primary intracranial hydatid cyst in the interpeduncular cistern. *Acta Neurochir (Wien)*. 2005 Jul;147(7):781-3; discussion 783. Epub 2005 May 20. PubMed PMID: 15900396.
29. Sanlı AM, Türkoğlu E, Kertmen H, Gürer B. Hydatid cyst of the ambient cistern radiologically mimicking an arachnoid cyst. *J Neurosurg Pediatr*. 2012 Sep;10(3):186-8. doi: 10.3171/2012.6. PEDS 11562. Epub 2012 Jul 13. PubMed PMID:22793161.
30. Basarslan SK, Gocmez C, Kamasak K, Ceviz A. The Gigant primary cerebral hydatid cyst with no marked manifestation: a case report and review of literature. *Eur Rev Med Pharmacol Sci*. 2015 Apr;19(8): 1327-9. Review. PubMed PMID: 25967703.
31. Erşahin Y, Mutluer S, Güzelbağ E. Intracranial hydatid cysts in children. *Neurosurgery*. 1993 Aug;33(2): 219-24; discussion 224-5. PubMed PMID: 8367043.
32. Duishanbai S, Geng D, Liu C, Guo HR, Hao YJ, Liu B, Wang YX, Luo K, Zhou K, Wen H; Research Group of Hydatid Diseases. Treatment of intracranial hydatid cysts. *Chin Med J (Engl)*. 2011 Sep;124 (18): 2954-8. PubMed PMID: 22040508.
33. Tsitouridis J, Dimitriadis AS, Kazana E. MR in cisternal hydatid cysts. *AJNR Am J Neuroradiol*. 1997 Sep;18(8): 1586-7. PubMed PMID: 9296204.
34. Salunke P, Patra DP, Mukherjee KK. Delayed cerebral vasospasm and systemic inflammatory response syndrome following intraoperative rupture of cerebral hydatid cyst. *Acta Neurochir (Wien)*. 2014 Mar;156(3):613-4. doi: 10.1007/s00701-013-1675-3. Epub 2013 Mar 10. PubMed PMID: 23474734.
35. Lunardi P, Missori P, Di Lorenzo N, Fortuna A. Cerebral hydatidosis in childhood: a retrospective survey with emphasis on long-term follow-up. *Neurosurgery*. 1991 Oct;29(4): 515-7; discussion 517-8. PubMed PMID: 1944831.
36. Onal C, Unal F, Barlas O, Izgi N, Hepgul K, Turantan MI, Canbolat A, Turker K, Bayindir C, Gokay HK, Kaya U. Long-term follow-up and results of thirty paediatric intracranial hydatid cysts: half a century of experience in the Department of Neurosurgery of the School of Medicine at the University of Istanbul (1952-2001). *Pediatr Neurosurg*. 2001 Aug;35(2): 72-81. PubMed PMID: 11549917.
37. Kızılca O, Altaş M, Senol U, Oztek MA. Hydatid disease located in the cerebellomedullary cistern. *Case Rep Med*. 2014: 271365. doi: 10.1155/2014/271365. Epub 2014 Mar 24. PubMed PMID: 24782895; PubMed Central PMCID: PMC3982244.