

Intraventricular meningioma in 4 years old child: case presentation

A.V. Ciurea, Iulia Vapor, A. Taşcu

“Bagdasar-Arseni” Clinical Emergency Hospital, Bucharest, Romania

Abstract

Meningiomas represent a rare entity in pediatric population. Also, in small children, intracranial tumors can reach giant dimensions with minimal neurological findings due to some special features of the brain and cranial vault at this age. The main diagnosis tool is the MRI. We choose to present the case of a 4 years old child with a giant intraventricular meningioma.

Keywords: child, meningioma, intraventricular tumour, MRI

Introduction

Although meningiomas represent the most common benign tumor in adult population, it accounts for less than 3% of primary intracranial tumors in children. In pediatric population, the features of this histological entity are very different from the adults. In children, meningiomas have unusual localizations more frequently than in adults. For example intraventricular meningiomas have an incidence of approximately 17% in the first two decades of life, compared with adults in which the incidence is approximately 5%. Other localizations more frequent seen in children are posterior fossa and primary intracerebral without any obvious dural attachment. Another feature frequently seen in children is lack of dural attachment (28.5%), whereas it is extremely rare in adults. This fact is

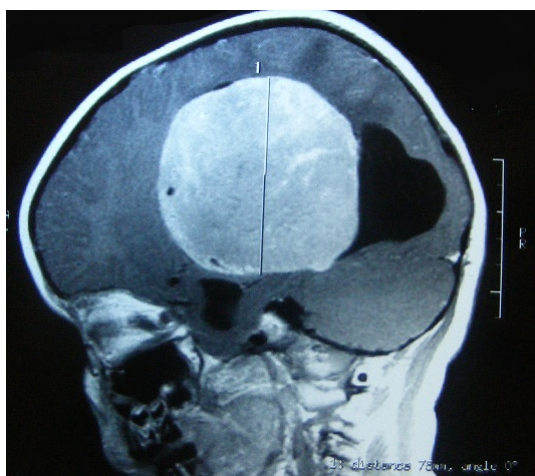probably due to the origin of the meningioma in the leptomeningeal elements located within the parenchyma or near the ventricles rather than the dura mater.

Case presentation

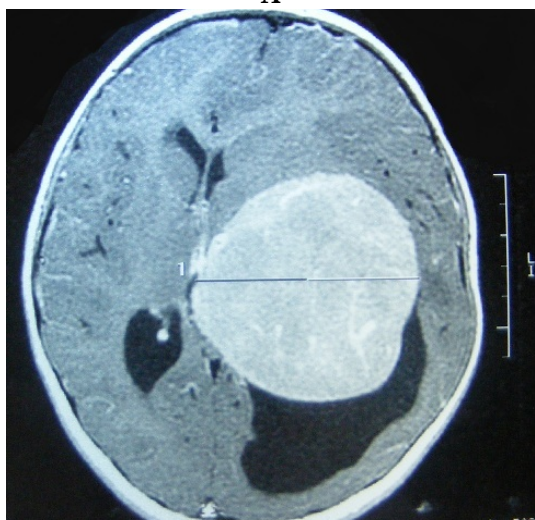
A four years old girl was admitted in the hospital for partial right brachial motor seizures, with progressive evolution in the last 3 months, and headache. The neurological exam revealed a right hemiparesis, right central facial palsy and gait disturbance. The development was normal and she had no history of trauma or medical problems. The brain MRI revealed a well-enhanced tumor with maximal dimensions 71x78x74 mm, noninfiltrative (Figure 1) located in the left lateral ventricle with secondary left ventriculomegaly and midline shift of approximately 1, 5 cm (Figure 2). Laboratory analyses were normal and the ophthalmological exam revealed papillary edema.

A left frontal transcortical transventricular approach was performed to remove the tumor. We found a well defined mass, noninfiltrative, with high consistency, very well vascularized. Gross total resection was accomplished with no significant intraoperative incidents.

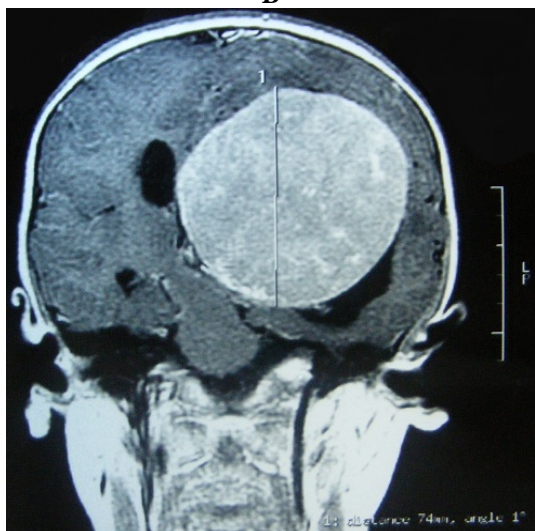
After the operation the patient was conscious, with right hemiparesis, right central facial palsy.



A



B



C

Figure 1 (A, B, C): Preoperative MRI: T1 with contrast enhancement images shows a well defined, noninfiltrative tumor, located in the left lateral ventricle with secondary left ventriculomegaly and midline shift , with dimensions of 71x78x74 cm.

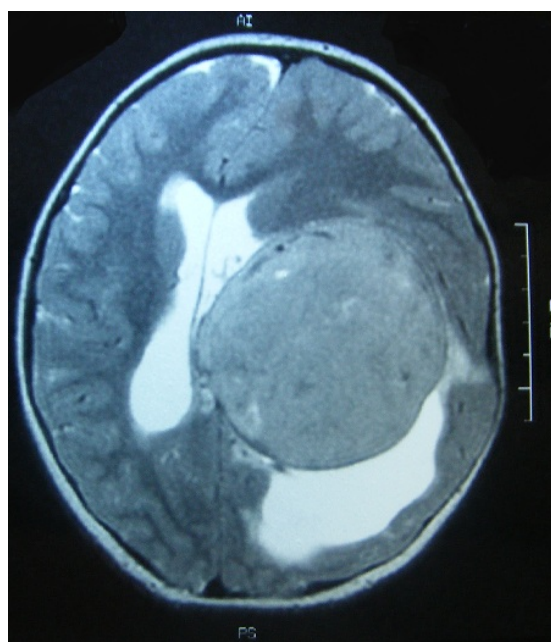


Figure 2 Preoperative MRI- T2 weighted image reveals the secondary ventriculomegaly with signs of transependymal absorption of CSF, but no surrounding tumoral edema.

The CT-scan performed 24 hours after the operation confirmed the gross total resection. The patient was discharged 7 days postoperative with the neurological deficits partial recovered.

The histopathological result was atypical meningioma with small areas of necrosis, patternless aspect, with small cells with high nucleocytoplasmic ratio. The immunohistochemical tests showed EMA positive, PGR positive in 30% and Ki 67 positive in 15%, those data confirming the histopathological aspect. The child was referred to the oncology department to establish the opportunity of radiotherapy or chemotherapy at this moment.

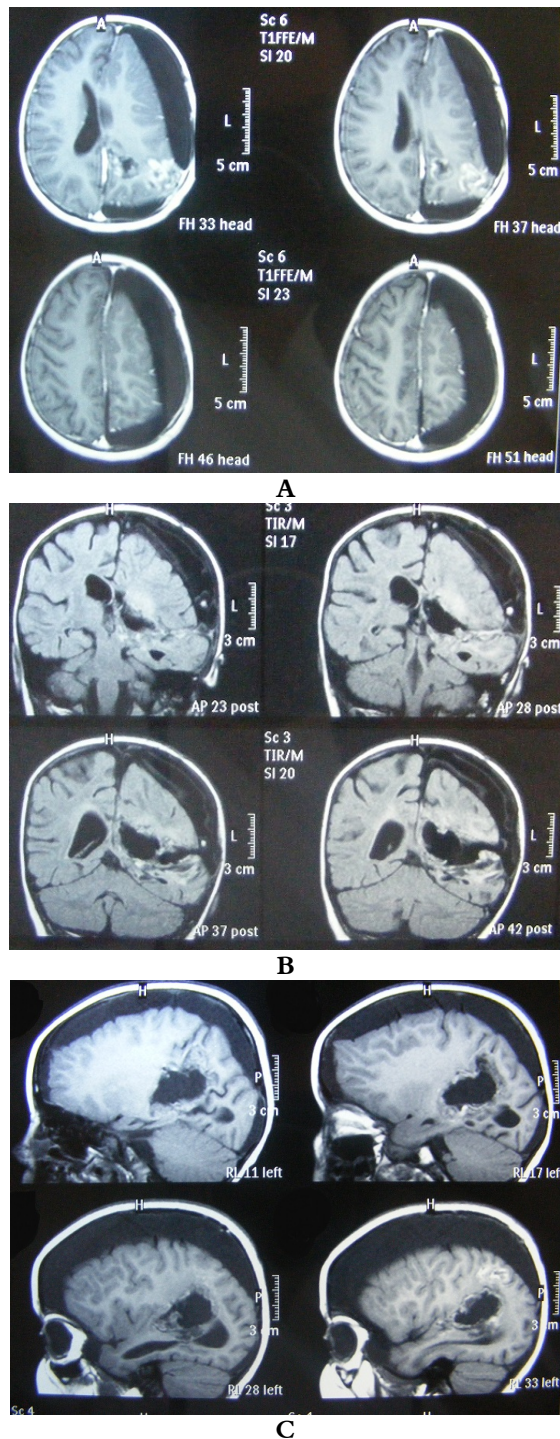


Figure 3 (A, B, C): One month postoperative MRI confirms the gross total removal, but also shows a compressive subdural hydroma.

At the one month follow-up control the patient presented with the neurological deficits improved from the discharge moment. The brain MRI showed no signs of residual tumor, but revealed a subdural hydroma, with compressive effect on the brain (Figure 3) so we decided to operate again the patient and evacuate the hydroma. After the operation the motor deficit improved. In case of unfavorable evolution of the hydroma at the next follow-up control we will insert a subduroperitoneal shunt.

Discussions

Meningiomas can affect any age group, but usually their incidence increases with advancing age, in pediatric population representing less than 3% of all primary brain tumors. Congenital or infantile cases are extremely uncommon and are encountered in the literature as case presentations.

There are two well known predisposing factors for appearance of meningiomas in children: neurofibromatosis 2 and prior exposure to ionizing radiation. Approximately 20-40% of children with meningiomas have NF-2, especially those with multiple tumors.

The localizations of meningiomas in children are different from their adult counterparts: convexity (50%), temporal (17%), lateral ventricles (17%) and falx-tentorial junction (17%). In adults the localizations are: parasagittal (30.8%), convexity (15.2%), tuberculum sellae (12.8%), sphenoidal ridge (11.9%), olfactory groove (9.8%), falx (8%), lateral ventricle (4.2%), tentorial (3.6%) and others (3.7%).

The symptomatology depends on the age of and the localization of the tumor. In small children the tumors can reach giant

dimensions due to the ability of the skull to compensate the volume changes, the increased volume of CSF in the subarachnoid spaces and the cisterns and a higher volume of water in the extracellular space. Later, the symptomatology depends on the localization of the tumor and is represented by focal neurological deficits, the signs of increased intracranial pressure and seizures. The lack of symptoms in small children can lead to giant tumor dimensions at the moment of diagnosis with many intra and postoperative complications.

Also in children the incidence of high-grade meningiomas is higher than in adults, have a tendency to grow more rapidly and undergo malignant changes. Due to this features the rate of recurrence is much higher. The most important prognostic factor is the total resection. The radiotherapy is prohibited at ages smaller than 3 years old.

Conclusions

We presented a case of giant intraventricular atypical meningioma in a small child (4 years old). This tumor is very rare at this age and in the literature this pathology is reported usually as case presentations or small series due to the rarity of this affection at this age. The symptomatology is poor, the dimensions at the time of diagnose are usually giant and the outcome depends on the grade of tumor resection.

Abbreviations used in this paper:
EMA=epithelial membrane antigen;
PGR=progesterone receptor; CSF=cerebrospinal fluid; MRI=magnetic resonance

imaging; NF-2=neurofibromatosis type 2; CT-computed tomography.

Correspondent author:

Dr. Al. Tascu

*“Bagdasar-Arseni” Clinical Emergency Hospital,
Bucharest, Romania*

tascu_alexandru@yahoo.com

References

1. Albright AL, Pollack IF, Adelson FP: Principles and Practice of Pediatric Neurosurgery: 1191-1192, 2009.
2. Ciurea AV, Arseni C, Lenke Horvath: Neurosurgical diseases of infant and young child (0-3 years). Medical Publishing House. Bucharest, 1979
3. Ciurea AV, Arseni C, Lenke Horvath: Paediatric Neurosurgical Pathology. Academy Publishing House. Bucharest, 1980.
4. Elisabeth J. Rushing, Cara Olsen, Mena H, Maria-Eugenia Rueda, Youn-Soo Lee, Keating RF, Packer RJ, Mariarita Santi: Central nervous system meningiomas in the first two decades of life: a clinicopathological analysis of 87 patients. *J Neurosurg Pediatrics* 6: 489-495, 2005
5. Kyung Sun Song, Sung-Hye Park, Byung-Kyu Cho, Kyu-Chang Wang, Ji Hoon Phi, Seung-Ki Kim: Third ventricular chordoid meningioma in a child. Case report. *J Neurosurg Pediatrics* 2: 269-272, 2008.
6. Lakhdar F, Arkha Y, El Ouahabi A, Melhaoui A, Rifi L, Derraz S, El Khamlichi A: Intracranial meningioma in children: different from adult forms? A series of 21 cases. *Neurochirurgie*. 56(4):309-14, 2010.
7. Mark S Greenberg. *Hanbook of Neurosurgery*: 238-239, 2006
8. Morina A, Kelmendi F, Morina O, Pazanin L, Dragusha S, Ahmeti F, Morina D: Rhabdoid meningioma in an eight-year-old child. *Med Arh*. 64(2):123-4, 2010
9. Rohringer M, Southerland GR, Louw DF, Sima AA: Incidence and clinicopathological features of meningioma. *J Neurosurg* 71: 665-672, 1989.
10. Sheikh BY, Siqueira E, Dayel F: Meningioma in children: a report of nine cases and a review of the literature. *Surg Neurol*. 1996; 45(4):328-35
11. Vachhrajani S, Jea A, Rutka JA, Susan Blaser, Cusimano M, Rutka JT: Meningioma with dural venous sinus invasion and jugular vein extension. Case report. *J Neurosurg Pediatrics* 2: 391-396, 2008.