

Ruptured intracranial mycotic aneurysm of the distal middle cerebral artery – case report

A. Chiriac, A. Iordache, N. Dobrin¹, I. Poata

“Gr. T. Popa” University of Medicine and Pharmacy, Iasi

¹“Prof. Dr. N. Oblu” Clinic Emergency Hospital, Iasi

Introduction

Mycotic aneurysm represents a rare but serious clinical condition characterized by significant morbidity and mortality. The most common causative pathogens of mycotic aneurysm are *Staphylococcus aureus* and *Salmonella* species. Also, other bacteria's like *Pseudomonas* spp., *Campylobacter fetus*, *Streptococcus* spp., *Clostridium* spp., and *Corynebacterium* spp. and *Klebsiella pneumoniae* have been noted as possible pathogens. This neurovascular entity develops as a consequence of vessel wall necrosis due to a massive presence of bacterial emboli into the systemic circulation.

Multiple treatment modalities are currently available and consist in conservative antibiotherapy, surgical closure or endovascular occlusion. We report a patient with ruptured mycotic aneurysm successfully treated by a combined treatment (surgical hematoma evacuation and conservative antibiotherapy).

Case presentation

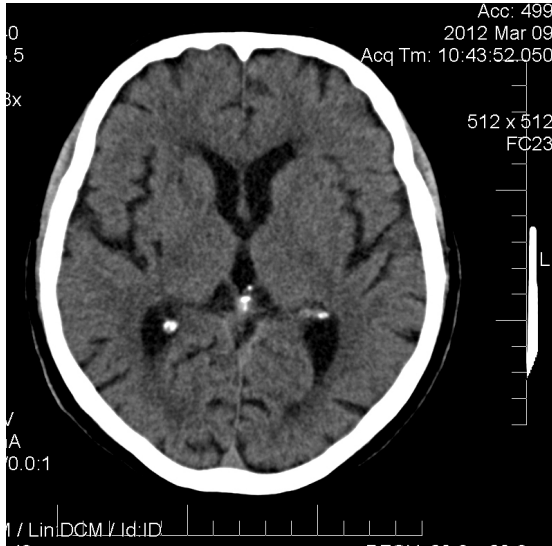
A 63-year-old male presented with a one week history of headache, vomiting and an episode of short time lost of conscious. He performs a cranio-cerebral CT scan with no pathological imagistic signs (figure 1). He was addressed to the Medical Clinic for

infectious diseases where the lumbar puncture shows a high level of cerebrospinal fluid leucocytes. Also, the blood leucocytes formula was highly modified.

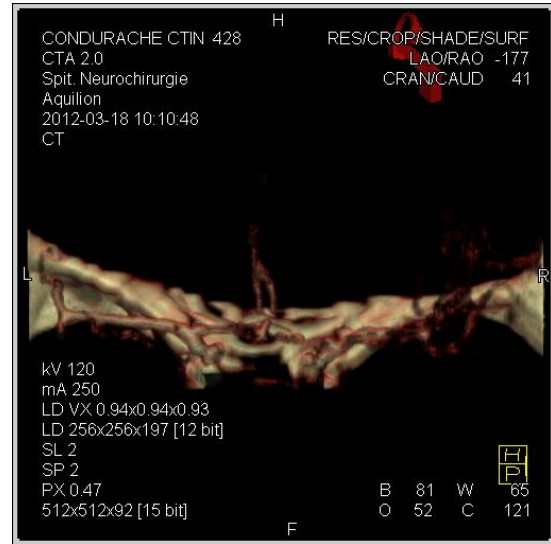
The patient was immediately admitted with the suspicion of meningitis with possible septic status. In the next two days he developed high-grade fever with delirium and strong headache episodes. In this situation a double antibiotic therapy was initiated.

Four days after admission, the patient developed altered sensorium and conscious. He was immediately addressed to our Neurosurgical Clinic. On clinical examination, the patient was febrile, tachypneic, disoriented and not obeying verbal commands. His motor examination revealed slight paucity of movements and tone on left side.

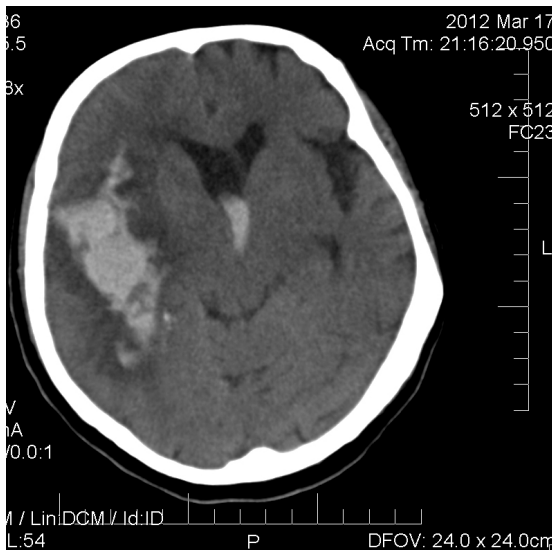
Soon after he experienced a precipitous decline in neurological status, becoming only responsive to the pain. He stopped spontaneously moving his left side with associated hyperreflexia and a positive Babinski sign on the left. Repeat CT scan showed an extensive increased right intracerebral haemorrhage with ventricular efraction and local mass effect (figure 2). A helical CT angiogram performed in emergency showed no vascular pathological signs (figure 3).

**Figure 1**

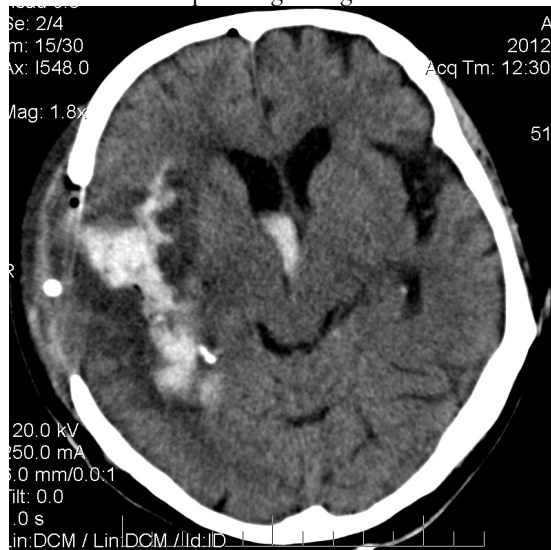
Initial diagnostic cerebral CT scan

**Figure 3**

Helical CT angiogram showing no vascular pathological signs

**Figure 2**

Diagnostic cerebral CT scan after neurological deterioration

**Figure 4**

Postoperative cerebral CT scan showing partial evacuation of intracerebral hematoma

Emergent evacuation of the intracerebral hematoma with external decompression was performed on the same day. No fresh hematoma or hemosiderin pigmentation was observed in the subarachnoid space (right Sylvian fissure) and a ruptured aneurysm could not be identified in the hematoma cavity.

A postoperative control CT scan was performed the next day showing a partial evacuation of right hemisphere hematoma (figure 4). The patient remained haemodynamically stable on intravenous antibiotics and subsequent sets of blood cultures had no growth. His mental status improved but his dense left hemiparesis still persisted.

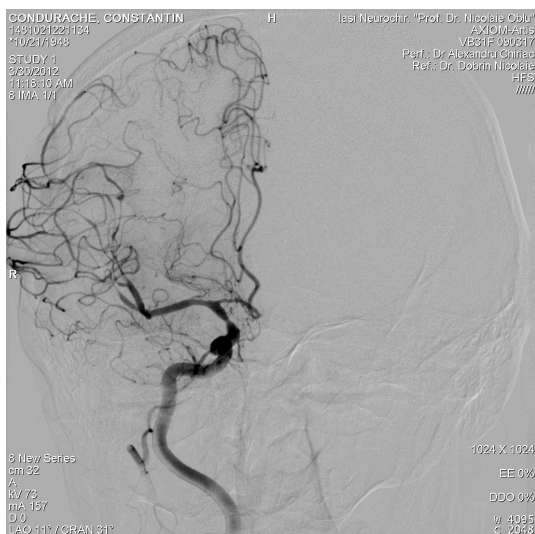

Figure 5a

DSA in AP exposure showing an aneurysm on distal M2 segment of right middle cerebral artery

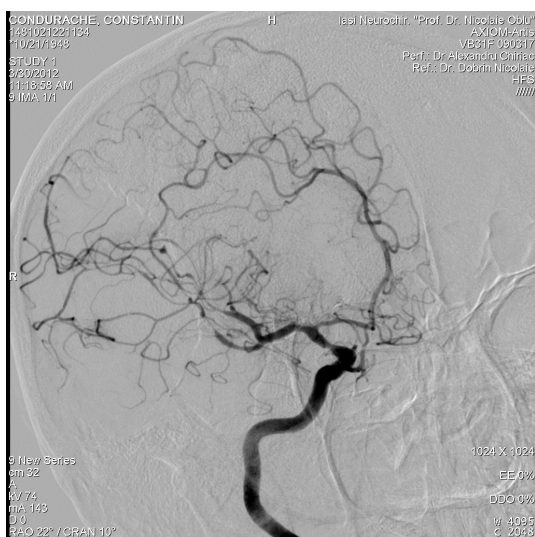


Figure 5b

DSA in Profile exposure showing an aneurysm on distal M2 segment of right middle cerebral artery

Four vessel digital subtraction angiography was performed for better visualization of the suspected arteriovenous malformation. The right carotid angiogram showed an irregular aneurysm arising from distal M2 segment of right middle cerebral artery (figure 5 a, b) and measured approximately 5 millimeters. Signs of

vasospasm were also identified on both M2 segment of right middle cerebral artery. The remainder of the angiogram did not revealed any abnormality. A decision was made to continue antibiotic therapy and repeat the digital subtraction angiography.

The digital subtraction angiography performed three weeks later revealed the total disappearance of the distal M2 aneurysm with no more signs of vasospasm (figure 6 a, b). Finally, the patient was discharged to a Recovery Clinic two weeks later with only a slight left side hemiparesis.

Discussion

Intracranial infectious aneurysms are rare vascular lesions and were first reported by Church in 1876 and account for 0.7-5.4% of all intracranial aneurysms. They are mainly located on the middle cerebral artery or its distal branches in up to 70% of the cases, less commonly on the anterior or posterior cerebral arteries. Their evolution is unpredictable even after commencement of antibiotic therapy. The mycotic aneurysms can either regress, develop de novo, or rupture. Variable outcomes have been reported (1), with a mortality rate of up to 83% (2).

Medical therapy is the first step in the management of mycotic aneurysms and consisting of long-term antibiotic therapy. However, surgery or endovascular therapy could be indicated in patients with intracerebral haematoma with significant mass effect or a possible vascular anatomical way to the lesion. To efficiency of medical therapy is determined by serial follow-up angiographic studies. The evolution of mycotic aneurysms with antibiotic therapy is unpredictable, they may regress, disappear, persist, enlarge or rupture. Their good responses to antibiotic therapy are indicated by regression in the size of the aneurysm or complete resolution of the aneurysms.[2,3,4,5,6]

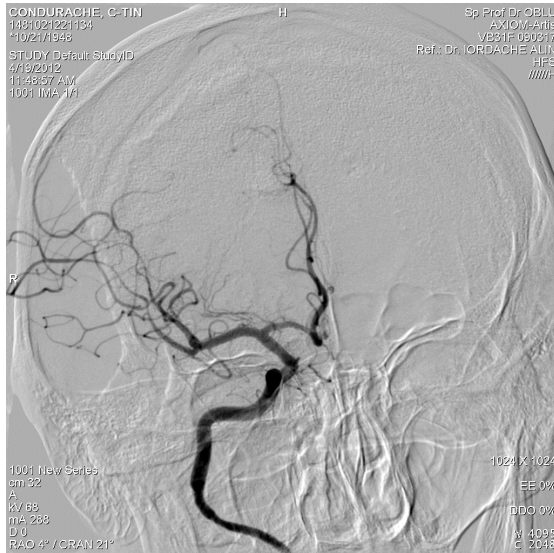

Figure 6a

DSA control in AP exposure showing total disappearance of the distal M2 aneurysm

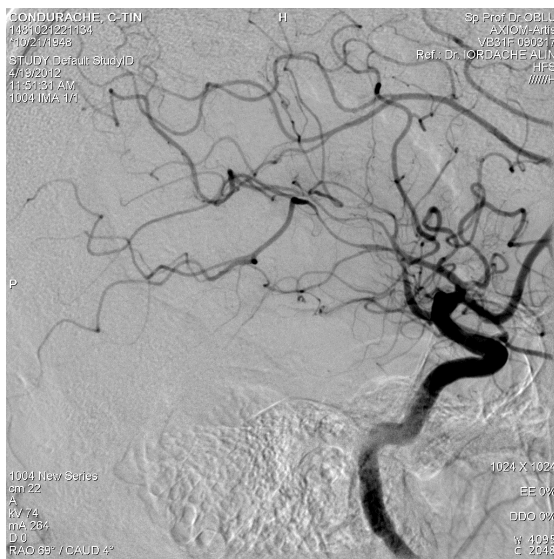


Figure 6b

DSA control in Profile exposure showing total disappearance of the distal M2 aneurysm

Conclusions

Our protocol is consisting in medical management for patients with aneurysms that have not yet ruptured or have no response to the antibiotics therapy. The medical therapy should be followed closely

with serial cerebral angiograms. Surgical treatment should be performed emergently in the setting of intraparenchymal hemorrhage or increased intracranial pressure. Endovascular intervention should be based especially on the involvement of eloquent vascular territory anatomy.

References

1. Haruki Yamakawa, Tatsuaki Hattori, Tetsuya Tanigawara, Yukiko Enomoto, Akio Ohkuma (2003) Ruptured infectious aneurysm of the distal middle cerebral artery manifesting as intracerebral hemorrhage and acute subdural mematoma – case report - , *Neurol Med chir (Tokyo)* 43:541 – 545;
2. North-Coombes D., Schonland M. M. (1974) Cerebral Mycotic Aneurysm- a case report - *S A. Medical Journal*, 1808 – 1810;
3. Raut Abhijit A, Ghatge Sharad B, Nagar Arpit, Narlawar Ranjeet S, Ahmed Nadeem, Limaye Uday L (2003) Mycotic Aneurysm of Posterior Cerebral Artery: Management By Endovascular Glue Embolization, *The Journal of Radiology*, 5:78-82;
4. Rene´ Chapot, Emmanuel Houdart, Jean-Pierre Saint-Maurice, Armand Aymard, Charbel Mounayer, Guillaume Lot, Jean-Jacques Merland (2002) Endovascular Treatment of Cerebral Mycotic Aneurysms, *Radiology* 2:389-396;
5. Antonio V. Salgado, Anthony J. Furlan, Thomas F. Keys (1987) Mycotic Aneurysm, Subarachnoid Hemorrhage, and Indications for Cerebral Angiography in Infective Endocarditis *Stroke* 1987, 18:1057-1060;
6. Wai-Kit Lee, Peter J. Mossop, Andrew F. Little, Gregory J. Fitt, John I. Vrazas, Jenny K. Hoang, Oliver F. Hennessy (2008) Infected (Mycotic) Aneurysms: Spectrum of Imaging Appearances and Management, *RadioGraphics*, 28:1853–1868;
7. Ahsan H, Ajmal F, Saleem M F, Sonawala A B (2009) Cerebral fungal infection with mycotic aneurysm of basilar artery and subarachnoid haemorrhage, *Singapore Med* 50(1) : e22;
8. Isabel Kuo, Theodore Long, Nathan Nguyen, Bharat Chaudry, Michael Karp, Nerses Sanossian (2010) Ruptured Intracranial Mycotic Aneurysm in Infective Endocarditis: A Natural History Case Reports in *Medicine* 10: 897-904;
9. Philip J Peters, Taylor Harrison, Jeffrey L Lennox (2006) A dangerous dilemma: management of infectious intracranial aneurysms complicating endocarditis, *Lancet Infect Dis* 6:742–48.