

Severe TBI with complex craniofacial fractures followed by cranioorbital reconstruction

F. Brehar, A. Giovani, L. Munteanu, R.M. Gorgan

Abstract: Young age is associated with better outcome in patients with severe traumatic brain injury (TBI). Still the reported mortality rate in patients that present in profound coma Glasgow Coma Scale (GCS) -3 pts is very high, even approaching 100% in the presence of fixed and dilated pupils in some series. We report a case of a 25 years old patient with a severe TBI in a car crush and presented in severe coma with a bilateral frontal and right temporal brain laceration with extended posttraumatic subarachnoid hemorrhage and a complex comminuted right frontal, maxillary and zygomatic fracture corresponding to Le Fort III fracture. After a difficult postoperative course with complications of tracheostomy like candidosis and bronchopneumony, then after a slowly progressive recovery, the patient was hemiparetic and with a persistent right 3rd nerve paresis at 6 weeks after the traumatic event, but was able to speak and to ambulate with assistance. Given the large bony defect that remained, a frontal and facial bony reconstruction was made by an interdisciplinary team using titanium plates and screws. Considering the excellent results in this case we advocate that young patients who suffered severe TBI even if they present in a very bad neurological shape should be given access to the best treatment.

Key words: Le Fort III fracture, severe brain injury, cranio-orbital reconstruction.

Introduction

Data from the Collaborative European NeuroTrauma Effectiveness Research in TBI (CENTER-TBI) show that 2.5 million people will suffer from some form of Traumatic Brain Injury (TBI) in Europe every year, 1 million will be admitted to the hospital and 75000 will die. In US the annual cost of TBI is over 75 billion USD.

The last 3 decades showed important

improvement in the surgical and medical treatment and in the outcome of severe TBI expressed in lower morbidity and mortality. (3, 4)

The surgical treatment should be prompt and include evacuation of the contusions, hematomas or lacerations using large craniotomies and dural reconstruction with fascia to decrease the cerebral pressure. (5) Every lesion which determines midline shift presents with a GCS<8 and has more than 2

cm diameter should be addressed surgically. The importance of the neurosurgical intensive care unit must be stressed but the neurosurgeon should direct the postoperative care of the patient as well. (2) The tracheostomy may be used only in situations when there is no other alternative. More and more departments use the monitorization of brain metabolism through jugular vein oxygen saturation. (6, 7) The secondary brain damage through seizures has to be avoided using anticritic medication and EEG monitoring to detect the seizure. while surgery aims survival the postoperative recovery is of great help in lowering the morbidity.

Case presentation

The 25 years old patient was driving a car that crushed frontally at more than 200km/h into a concrete wall. When He was brought by helicopter in the emergency department the only neurological response elicited was extension to nociception (GCS-4 pts.). A large frontal scalp laceration was visible, multiple bone fragments were palpable underneath with cerebral tissue extruded through the laceration. A CT scan with bone window and bone reconstruction was immediately obtained which showed bilateral frontal and right Temporal brain laceration with extended posttraumatic subarachnoid hemorrhage. Also bilateral frontoorbital complex fractures and right temporal complex fracture. Also the right maxilar and zigomatic bone presented cominution fractures and bilateral hemosinus was observed.

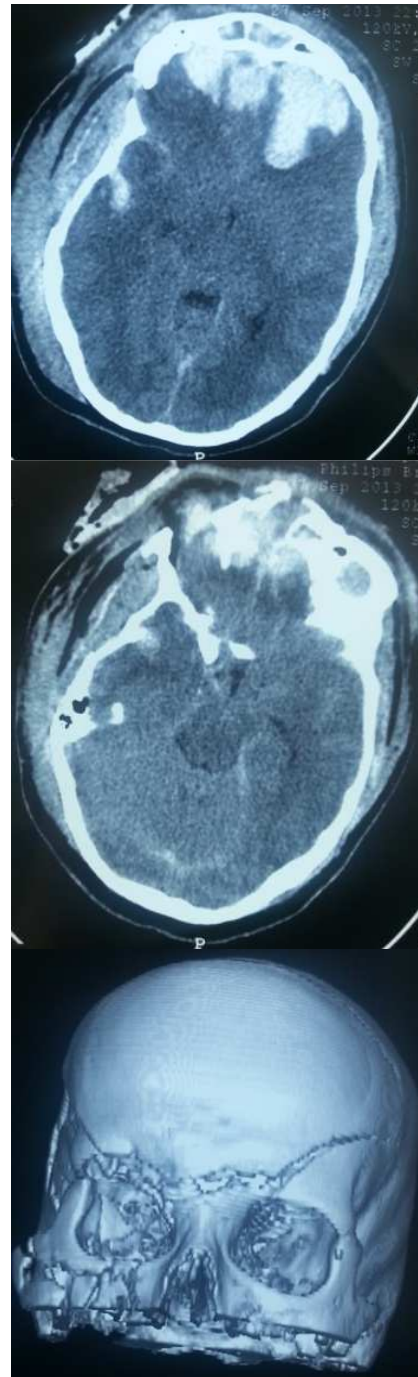

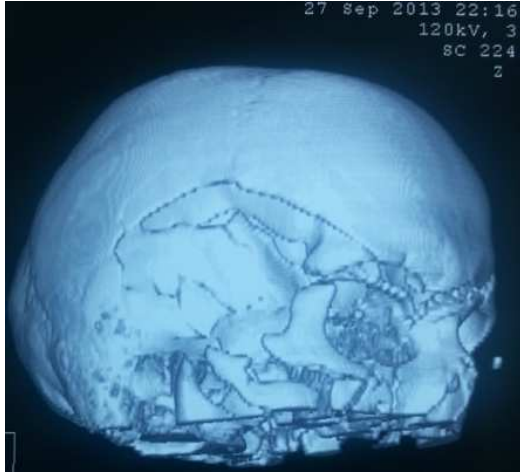


Figure 1 A - CT scan with bone reconstruction at presentation: bilateral frontal and right temporal brain laceration and bilateral frontoorbital complex fractures and right temporal complex fracture; right maxilar and zygomatic bone presented cominution fractures and bilateral hemosinus. B - 1 month postop CT – note ischemia and bone defect

The patient presented Gross edema of soft tissue, bilateral circumorbital ecchymosis with bilateral subconjunctival hemorrhage, epistaxis, CSF rhinorrhoea, enophtalmia, and left face deformity corresponding to LeFort III fracture.

After other serious life threatening lesions were excluded the patient went directly to surgery. Both the frontal brain lacerations were cured and hemostasis was achieved with difficulty. The bone fragments in the superior and lateral right orbital wall were removed then fragments from the right temporal bone. Dura was reconstructed with fascia and Gelaspon was applied on the defects.

The patient neurological status does not improve after surgery and after 3 days a tracheostomy is needed. On Day 10 post surgery the patient is febrile. A CSF sample is sent for analysis and the result was candida

infection. The antimicotic therapy is started. Two weeks later the neurological status improves the patient is extubated, spontaneously opens the eyes, and correctly executes verbal comands, but he has severe left sided hemiparesis.

During the third postop week the neurological status is worsening and the patient needs to be reintubated (GCS - 5 pts). The CT scan on this occasion shows a right frontal brain haemorrhagic laceration. Emergency surgery is performed and the hematoma evacuated and the laceration is resected with aspiration and coagulation.

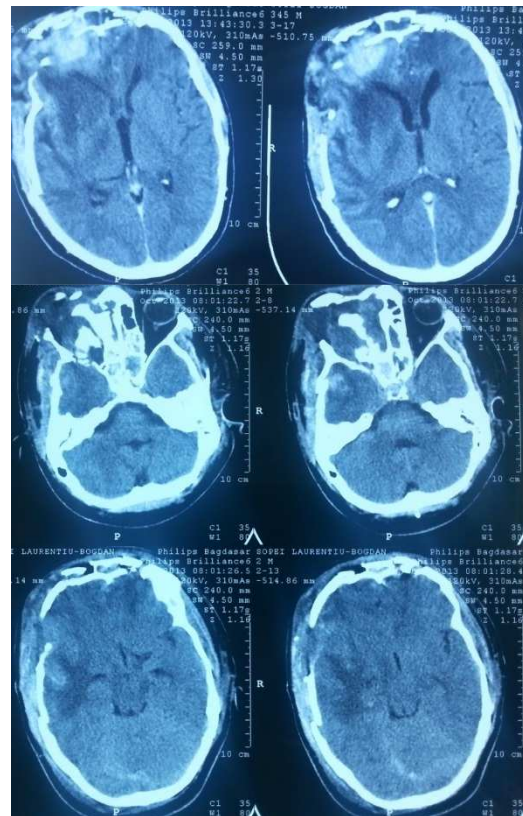


Figure 2 - 3 weeks postop – haemorrhagic transformation of right frontal brain laceration, with reintervention .and 6 weeks follow up CT scan

After this second surgery the evolution is slowly favourable and the patient regains consciousness. The patient is febrile again and staphylococcus and candida are found in the CSF. The antibiotic treatment is adjusted according to the antibiogram. A lumbar drainage is required for 5 days draining about 150ml/24 h CSF. After a slowly progressive neurological amelioration the patient is discharged from the ICU to the ward, 6 weeks after admission, with severe left hemiparesis, and right 3rd nerve palsy.

Following 5 months of intensive neurorehabilitation, the patient shows an impressive recovery being able to ambulate with assistance and to entertain a normal conversation though with minimal recovery of the 3rd nerve paresis.

Given the bone defect that remained after these operations (Figure 1) a third cranioplasty surgery was staged to reconstruct the frontotemporal defect and the roof and lateral wall of the orbita with perforated titanium plates. The surgery was performed by an interdisciplinary team including a maxillofacial surgeon. We used a large twisted sheet of titanium plate to reconstruct the superior orbital rim and the roof of the orbita. Another titanium plate was used to reconstruct the temporal bone defect.

Discussion

As TBI is considered “the most complex disease in our most complex organ.” There are many variables on which the outcome depends so it is difficult to be predicted. (1) TBI triggers a chain of chronic process, with progressive injury over hours, days, weeks, months, and even years. Following severe TBI the survivors may develop various cognitive impairment and emotional disturbances thus impairing their normal function in society. (8, 11) This case report shows that a good outcome can be achieved after severe TBI that brings the patient to the hospital in profound coma. The sooner the time from the accident to the surgery the better the chance of survival, in this case with a good recovery. (12, 13) The complex frontoorbital fracture in this case may have reduced the mass effect and the imminence of brain herniation consecutive to such extensive brain lesions as the patient presented. Even under a severe metabolic disturbance that followed the bronchopneumony associated with the intubation and the candida infection, the age of the patient may have been the decisive factor in the course he followed towards recovery. (9, 14)

As long as there is no clear guideline in treating these patients and we cannot predict the outcomes of such severe TBI we believe these cases should not be abandoned and they should benefit from the best surgical and medical treatment.

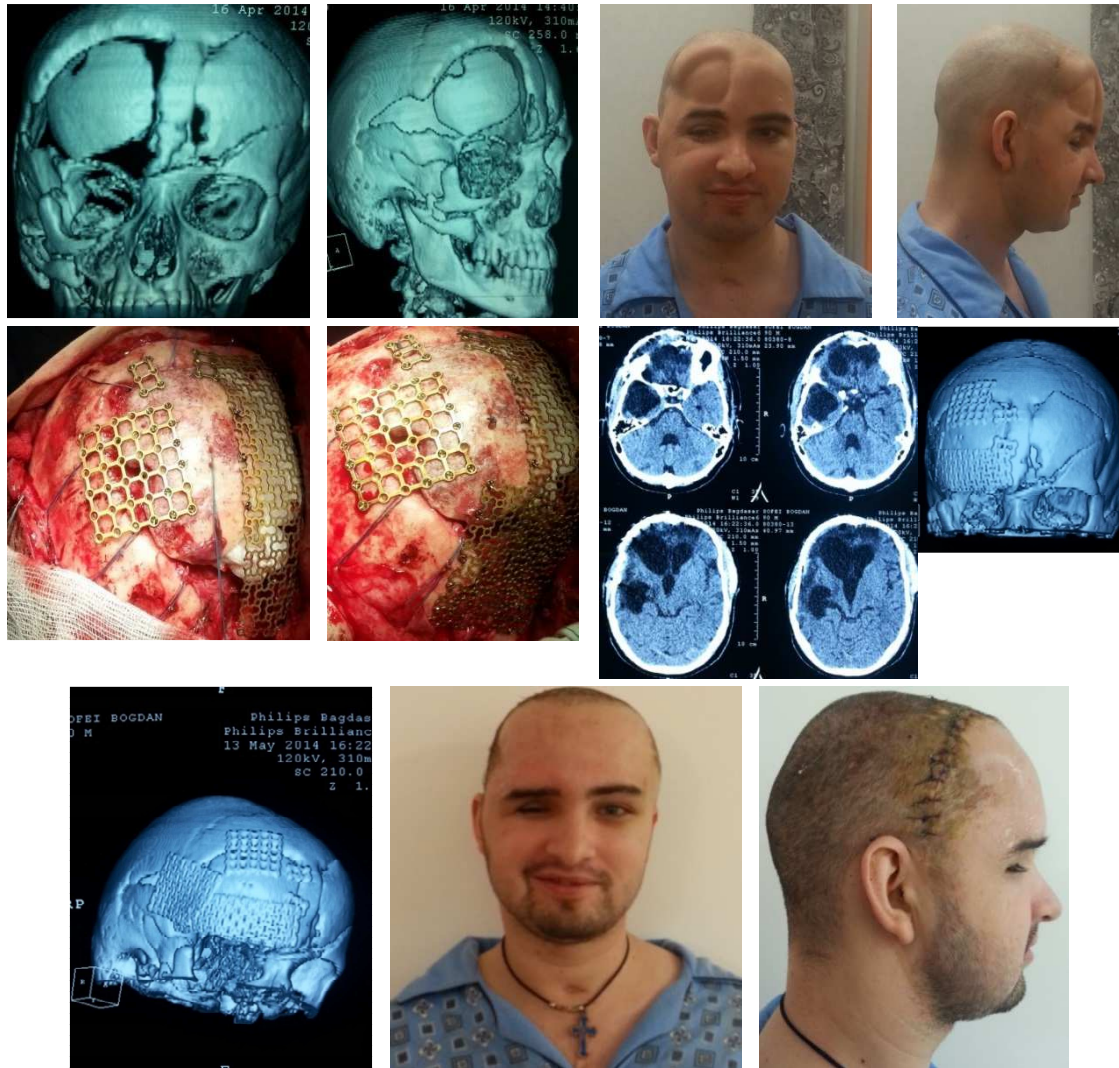


Figure 3 - Right frontoorbital reconstruction, 6 months after the first surgery

Correspondence

Giovani Andrei

giovani.andrei@gmail.com

References

1. Chesnut RM, Marshall LF, Klauber MR, Blunt BA, Baldwin N, Eisenberg HM, et al: The role of secondary brain injury in determining outcome from severe head injury. *J Trauma* 34:216–222, 1993

2. Demetriades D, Kuncir E, Velmahos GC, Rhee P, Alo K, Chan LS: Outcome and prognostic factors in head injuries with an admission Glasgow Coma Scale score of 3. *Arch Surg* 139:1066–1068, 2004

3. Eisenberg HM, Gary HE Jr, Aldrich EF, Saydjari C, Turner B, Foulkes MA, et al: Initial CT findings in 753 patients with severe head injury. A report from the NIH Traumatic Coma Data Bank. *J Neurosurg* 73:688–698, 1990

4. Fearnside MR, Cook RJ, McDougall P, McNeil RJ: The

Westmead Head Injury Project outcome in severe head injury. A comparative analysis of pre-hospital, clinical and CT variables. *Br J Neurosurg* 7:267–279, 1993

5. Gennarelli TA, Champion HR, Copes WS, Sacco WJ: Comparison of mortality, morbidity, and severity of 59,713 head injured patients with 114,447 patients with extracranial injuries. *J Trauma* 37:962–968, 1994

6. Goebert HW Jr: Head injury associated with a dilated pupil. *Surg Clin North Am* 50:427–432, 1970

7. Kotwica Z, Jakubowski JK: Head-injured adult patients with GCS of 3 on admission—who have a chance to survive? *Acta Neurochir (Wien)* 133:56–59, 1995

8. Lieberman JD, Pasquale MD, Garcia R, Cipolle MD, Mark Li P, Wasser TE: Use of admission Glasgow Coma Score, pupil size, and pupil reactivity to determine outcome for trauma patients. *J Trauma* 55:437–442, 2003

9. Phuenpathom N, Choomuang M, Ratanalert S: Outcome and outcome prediction in acute subdural hematoma. *Surg Neurol* 40:22–25, 1993

10. Pickett W, Ardern C, Brison RJ: A population-based study of potential brain injuries requiring emergency care. *CMAJ* 165:288–292, 2001

11. Signorini DF, Andrews PJ, Jones PA, Wardlaw JM, Miller JD: Predicting survival using simple clinical variables: a case study in traumatic brain injury. *J Neurol Neurosurg Psychiatry* 66:20–25, 1999

12. Tien HC, Cunha JR, Wu SN, Chughtai T, Tremblay LN, Brenneman FD, et al: Do trauma patients with a Glasgow Coma Scale score of 3 and bilateral fixed and dilated pupils have any chance of survival? *J Trauma* 60:274–278, 2006

13. Valadka AB: Injury to the Cranium, in Mattox KL, Feliciano DV, Moore EE (eds): *Trauma* (ed 4). New York: McGraw-Hill, 2000, pp 377–399

14. Waxman K, Sundine MJ, Young RF: Is early prediction of outcome in severe head injury possible? *Arch Surg* 126:1237–1242, 1991