

Current perspectives concerning the multimodal therapy in Glioblastoma

Florina Grigore¹, Felix Mircea Brehar^{1,2}, Mircea Radu Gorgan^{1,2}

¹Emergency Clinical Hospital "Bagdasar-Arseni", Bucharest, Romania

²"Carol Davila" University of Medicine and Pharmacy, Bucharest

Abstract: GBM (Glioblastoma) is the most common, malignant type of primary brain tumor. It has a dismal prognosis, with an average life expectancy of less than 15 months. A better understanding of the tumor biology of GBM has been achieved in the past decade and set up new directions in the multimodal therapy by targeting the molecular paths involved in tumor initiation and progression. Invasion is a hallmark of GBM, and targeting the complex invasive mechanism of the tumor is mandatory in order to achieve a satisfactory result in GBM therapy. The goal of this review is to describe the tumor biology and key features of GBM and to provide an up-to-date overview of the current identified molecular alterations involved both in tumorigenesis and tumor progression.

Key words: glioblastoma, molecular pathways, invasion, targeted therapy.

Introduction

Malignancies involving the Central Nervous System (CNS) are undoubtedly a diagnostic and therapeutic challenge. Among them, High-grade gliomas, are by far the most challenging issue for neurosurgeons and neuro oncologists. Glioblastoma is the highest-grade glioma tumor (WHO grade IV) [65], the most common type of primary malignant brain tumor in humans [43, 15], and one of the deadliest cancers. Despite extensive efforts to streamline the methods of diagnosis and treatment, GBM remains the neurosurgeon's Eternal Hydra [84] and an invariably lethal tumor with a median survival of 15-17 months

[101], despite maximal therapy. The standard of care [11] for patients with newly diagnosed GBM encompasses maximal safe surgical resection, if feasible, or stereotactic/open biopsy if tumor resection is not an option, followed by radiation therapy plus concomitant and adjuvant chemotherapy with Temozolomide. Unfortunately the standard treatment for patients with GBM remains palliative; it is virtually impossible to "cure" GBM, as complete resection is possible in only few cases and recurrence is diagnosed in as much as 83% of the patients [9]. The failure of standard therapy in GBM is reflected by the recurrence rates, a highly aggressive tumor behavior in relapses and the poor overall

patient prognosis. If we had to choose one word to describe GBM it would likely be heterogeneity that is reflected not only from a clinical, gross-morphological or histopathological perspective but also in terms of genetic, molecular and newer, proteomic, perspectives [76, 58]. Genotyping of brain tumors may have applications in stratifying patients for clinical trials of various novel therapies [94]. Cytogenetic and molecular analysis of the tumor along with robust animal models [1] set a new direction in understanding tumor pathogenesis and in developing a complex multimodal therapeutic sequence. In 2008 The Cancer Genome Atlas research team (TCGA) which aims at establishing a database of high-resolution expression profiles in tumors, choose GBM as the path breaker tumor [67]. A future genetic classification of brain tumors, derived from the technical *tour de force* of gene microarrays will provide a useful database and the path to improve results in cancer therapy [54]. A thorough understanding of the tumor biology and especially of the complex invasive and migratory mechanism of GBM is mandatory in order to develop a new generation of targeted, highly specific therapies and to fight "The Terminator", as GBM is often called [41].

Epidemiology, clinical features and imaging

GBM is the most frequent type of primary brain malignancy, with an overall incidence rate of 3.19 per 100,000 person-years in USA [15] and 3.32 (CI, 2.69–4.09) for male cases and 2.24 (CI, 1.56–3.22) for female cases, age-adjusted to the World Standard Population as showed by a population-based study on glioblastoma in the Canton of Zurich,

Switzerland [75]. The highest incidence rates of GBM are found in the 6th and 7th decades of life. Primary and secondary glioblastoma constitute distinct disease subtypes- the majority of cases (>90%) are primary glioblastomas that develop rapidly -de novo, while secondary glioblastomas develop through progression from low-grade, diffuse astrocytoma or anaplastic astrocytoma, manifest in younger patients, and have different genetic pathways [76] and prognosis [27]. Data suggest that older age, male gender and higher socio economic status, increase the risk for GBM [16].

In the majority of cases, the clinical presentation of glioblastoma is superposable on that of all intracranial expansive processes, expressing the progressively increased intracranial pressure against the incompressible compartment of the skull, as stated by the Monroe Kellie doctrine [70]. Common findings include: persistent headache, papilledema, incoercible vomiting, ocular palsies, altered level of consciousness. The clinical elements of glioblastoma can be summarized in general and focal signs (hemiparesis, sensory loss, visual loss, aphasia). Of the clinical elements is distinguished by frequency: headaches, as a constant finding [31], neurocognitive impairments and seizures. There are however a number of issues suggestive for an underlying GBM: the most remarkable aspect is the galloping pace of progression and worsening of symptoms (clinical manifestations in primary glioblastoma have a duration of <3 months to >50% of patients at the time of diagnosis [12], and the mean

period from first symptoms to histological diagnosis is around 6 months. The clinical picture of GBM depends on several aspects: the location of the tumor and adjacent structures involved in tumor expansion, the rhythm of tumor progression, the marked invasive behavior, a hallmark for GBM, bleeding - either within the tumor (glioblastomas are strongly vascularized tumors, with an impressive potential of neoangiogenesis), or bleeding in other vascular structures secondarily involved in the extending - infiltrative lesion, the existence of multifocal lesions, patient age and comorbidities. There have been reported cases with atypical clinical features such as ulnar neuropathy, syncopal events [93], or even sudden unexpected death [88]. The progress of medical imaging tools, today owning a remarkable degree of accuracy in describing different types of lesions, decreased the importance of a thorough clinical approach in order to establish the topography of the tumor. However, we always must pay attention to the "warning signs" that alert on the possibility of an evolving tumor process: 1) any signs or symptoms that suggest a progressively increased ICP; 2) any evolving neurological deficit; 3) occurrence of epilepsy in adult life [109]; and mostly an accelerated worsening in any above - suggestive for an underlying GBM.

GBM is a "colorful but deadly tumor" [80], with pleomorphic aspects in imaging tools-findings. Usually CT-scan is the first step in the imaging investigations. It usually describes an iso/hypo dense lesion with irregular boundaries and a central hypodense area that

reflects the necrosis [79]. Peritumoral edema and bleeding areas within the lesion are also constant findings. Despite important improvements in CT-scan technique [21], MRI is the best choice [26] to describe the morphology of the tumor, as CT-scan can miss posterior fossa lesions-despite it's not a common topography for GBM, it can also overpass small tumors that fail to capture the contrast agent. The preoperative imaging modality of choice is gadolinium-enhanced magnetic resonance imaging (MRI) [35]. Other imaging modalities, such as positron emission tomography with (18F)-fluoro-deoxy-d-glucose or SPECT-MRI, may also be considered in selected cases [24]. However the standard MRI-approach has its limits: viable tumor areas extend beyond the region signal switch, therefore the magnitude of tumor extension and infiltration cannot be assessed accurately by MRI studies. The indefinable borders of glioblastoma cell infiltration into the surrounding healthy tissue prevent complete surgical removal. Another drawback of MRI studies is that sometimes fail to distinguish post-treatment radiographic imaging changes [113] the so called "pseudoprogession" from true tumor progression [103]-underlying once more the need for improvement in the tumor imaging field.

From stem to GBM

Over time there have been questioned some etiopathogenic hypotheses about GBM, each having a number of arguments more or less sustainable with scientific evidence. Initially it was thought that glioblastoma tumor cells derive from embryonic primitive

cells - the *embryonal remains theory* of Bailey and Cushing (1926), which dominated the tumor pathogenesis for many years [4] and encompasses the general concept that cancers arose from embryo-like cells, which remained in a tissue. Subsequently came the *astrocyte origin-theory*, a prominent theory that encompasses the idea that this tumors arise from neoplastic transformation of mature adult cells (dedifferentiation)-brought into perspective by Kernohan, suggesting that a normal astrocyte is transformed into a neoplastic cell by "escaping" certain points in the cell cycle and gaining resistance to apoptosis by blocking apoptotic pathways in cells-becoming malignant cells. As it multiplies, the daughter cells become variably anaplastic [91].

However, it is currently thought that high-grade gliomas arise from more primitive elements, specifically stem cells, and it may be that the ostensible dedifferentiation is an artifact of the histologic appearance of tumors. The characterization of a fraction of tumor cells in many types of cancer (colon, breast, blood, brain) opened a new chapter in cancer research, providing a new, hierarchic model of malignancy for GBM. Cancer stem cell can become specific targets that can be incorporated into the development of multimodal therapeutic strategies. Cancer stem cells have been identified in GBM and some pediatric brain tumors - especially medulloblastoma [29, 111]. This fraction of cells is different from the bulk tumor cells by several aspects: they own an abnormal expression of cellular pathways such as Notch or stat3 and they are somehow resistant to

classic therapy- chemo-resistant and resistant to radiation therapy. Stem cells theory in gliomagenesis [92] practically revolutionized the concept of GBM tumor ontogeny. The idea that states the absence of neural regenerative potential may be considered invalid by the results of recent research [98, 59]. On top of this pyramid is a cell group possessing a distinctive behavior-neural stem cells. This cell population permits the tumor survival, but the cells are also involved in the highly invasive nature characteristic of this type of tumor. Neural stem cells population provides the "fuel" for the invasive behavior of the tumor. It raises naturally the question about the origin of these stem cells and the extent to which these cell populations normally reside in certain areas of the CNS, and the event that triggers malignant transformation of stem cells. In certain types of malignancies that develop in this stem-model (the so called "stem cells disease") such as chronic myeloid leukemia [8] it is clear that these malignant stem cells arise from normal hematopoietic stem cells that undergo a series of genetic mutations and epigenetic changes. The major attribute of these cells is the ability to self-renewal [110], but first we have to find out what is "self" in terms of stem cells. However, the actual existence and features [93] of stem cells - not only neural stem cells but also stem cells that reside in other parts of the body is subject of controversy - as "seeing is believing" and no one yet succeeded to "catch " a stem cell under the microscope. What we have is a functional pattern for a stem cell, based on several phenotypic markers, the self-renewal ability being by far the most important aspect

that brings into perspective a possible stem - cell emergence for GBM.

Underlying genetic alterations in tumor initiation

Malignant astrocytomas, and particularly glioblastoma, have a number of common characteristics with the rest of malignancies, features that generally define the hallmarks of cancer [37]: (1) the ability of cancer cells to stimulate their own growth; (2) the capacity to resist inhibitory signals that might otherwise stop their growth; (3) they resist their own programmed cell death (apoptosis); (4) they stimulate the growth of blood vessels to supply nutrients to tumors (angiogenesis); (5) they can multiply forever-potential immortalization with telomerase activation and (6) they invade local tissue and spread to distant sites (metastasis). GBM is a unique type of tumor, owing a very heterogeneous cell population, genetic and molecular pathways. In addition, another 4 cardinal aspects must be taken into account in understanding possible gliomagenesis: 1) abnormal metabolic pathways; (2) evading the immune system; (3) chromosome abnormalities and unstable DNA; and (4) inflammation. Following we try to present an integrated, evidence - based view, on what we know about GBM pathways, tailored on what we recognize as oncogenic events in general.

One of the main features of cancer ontogeny is genomic instability [63]. This feature can take many forms: aneuploidy or intimate changes in chromosomal structure are equally frequent. One of the most common chromosomal abnormality in GBM is the loss of heterozygosity [85]. The most frequent

involved regions, as shown by hybridization studies, are: **p, 6q, 9p, 10p, 10q, 13q, 14q, 15q, 17p, 18q, 19q, 22q**, and Y [53]. By far the most common finding is the loss of heterozygosity at 10 q level, occurring in 60- 80 % of the cases. Loss of the heterozygous nature turns the hemizygotism area in a vulnerable area. Extensive studies found at least three distinct loci to be deleted at 10q level (e.g., **10p14-p15, 10q23-24**, distal to **10q25**) while some samples show a complete loss of a copy of chromosome 10 underlying once more the pleomorphic nature of GBM. Integrating the main features of a malignant behavior - and the findings that show this type of aneuploidy (as PTEN mutation is almost exclusively found in cases with LOH) - we can strongly suggest the possibility of tumor suppressor genes residing in this loci, and mark the genomic instability as the *first hot spot* gliomagenesis.

The cell cycle encompasses a fine regulated sequence of biochemical processes, which is supervised by a very accurate structure the so called - "cell cycle control system" [3]. RB pathway and p53, among others, are the "guardians" of the cell cycle- the key players in tumor suppressing activity. Disturbances in cell cycle are the background of enhanced, uncontrolled cell proliferation. The tumor suppressing genes involved in RB (retinoblastoma) or p53 pathway [33], are either inactivated or encounter mutational defects [28, 95, 19] in GBM cases (loss of chromosome 9 which contains CDKN2A, CDKN2B, and PTPRD genes involved in p53 and RB pathways is also identified in some cases). There is also strong evidence that genetic alterations in the PTEN tumor

suppressor gene on 10q23 - become involved in this "mutational gained tumor independence". Some data suggest even fine interactions between **PTEN**, **p53**, and **RB** pathways contributory to this anarchic proliferation as a result of a damaged suppressing activity [28]. Summarizing, we can argue the existence of a *second hot spot* in tumor biology at the cell cycle control level with the respective complex mechanisms involved.

Any cellular structure whose volume exhibits 2-3 cm³ cannot virtually survive without a proper vascular backup. The processes of neo-angiogenesis [13] is a cancer hallmark and is highly accelerated in GBM adjusted to the speeding rhythm of growth and is mediated by fine mechanism that involve growth factors, and other local mechanism [44]. Amplification of the epidermal growth factor receptor (EGFR) gene on chromosome 7 is also a habitual finding in GBM. **EGFR** gene amplification or mutation and subsequent activation of the PI3K/AKT pathways is found in 30-40 % of primary GBM. EGFR is a cell membrane receptor - that is normally found in many cells. EGFR and its ligands are expressed in variable proportions even during embryogenesis in the neural tissue and persists in postnatal and mature brain. Abnormal expression or altered signaling of growth factors and their respective pathways is a common theme in GBM. Altered function of EGFR, VEGF, PDGR, and TGF have all been implicated in GBM. Moreover, up regulation of EGFR was identified in a number of other cancers [74] (lung cancer, breast cancer, colon cancer), all above reputed in terms of

malignancy. A majority of EGFR amplifications in glioblastoma contain a mutant variant of EGFR, that is EGFRviii [25, 34] and is linked to a dismal prognosis [39]. Murine glioma models confirmed the involvement of EGFR in gliomagenesis. Also deletion of NFKBIA [89] (an EGFR signaling inhibitor) [10] is related to a poor prognosis. As an important aspect, EGFR amplifications and mutation scarcely occur in secondary GBM, suggesting different mechanism involved in the two types of GBM [106]. All above bring forward a *third hot spot* at the growth factor paths level.

New data suggest that GBM de novo and secondary GBM can be regarded as completely different tumors each having an individual path of progression with just discreet overlap sequences [76]. **IDH1** encodes isocitrate dehydrogenase 1 and is involved in energy metabolism. IDH1 mutations have been predominantly identified in secondary glioblastoma and low-grade gliomas [46], with mutations in more than 70% of cases and they are found only sporadically in primary glioblastoma [107]. Therefore, IDH1 could be used to differentiate primary from secondary glioblastoma, and moreover highlights abnormal cellular metabolic pathways as a *fourth hot spot* in tumor activity.

Current research data provide a multitude of presumed hot spots in GBM tumor initiation and progression that put into perspective possible new therapies [105] for this unique type of tumor. Studies by The Cancer Genome Atlas (TCGA) have incorporated genomic alterations within expression analysis, and set molecular

subclasses in high-grade glioma, delineating a pattern of disease progression that resembles stages in neurogenesis, and have been used to classify glioblastoma into: **proneural, neural, classic, and mesenchymal** subtypes [82]. Different subtypes of glioblastoma have been shown to behave differently in response to treatment [9].

GBM invasion - one direction - several molecular "vehicles"

GBM is highly invasive by nature, it can be regarded as a referential model of malignancy. First, the tumor has an important local extension [51], the rapid, diffuse, infiltration of adjacent structures, and secondly there is a metastatic potential [62, 66] though not a common situation for GBM - occurring especially in patients undergoing surgical procedures [42], which create favorable local conditions for dissemination and not least there are situations of multifocal tumors [2] in patients diagnosed with GBM - situations that beyond the radiological diagnosis and coarse morphological description, question the possible existence of synchronous, methachronous tumors or the expression of complex mechanisms of invasion within the brain [5] - still unsolved- so that the multifocal appearance could be a particular model of invasion [72]. In the local extension of GBM, there have been observed "selective routes" - primarily it is known that the extension is elective in the brain parenchyma - in different white matter structures depending on the specific topography of the primary tumor. The majority of supratentorial glioblastoma are localized in the cerebral hemispheres - with

epicenter in full white matter [1]. Elective extension in the white matter [14] is argued by the fact that despite the highly invasive profile of the tumor, subarachnoid extension is rarely seen in glioblastoma- metastasis through the cerebrospinal fluid is exceptional. Migrating glioma cells tend to move along the vessels, dendrites, and fibers in white matter. A preferred extension route used by GBM is the corpus callosum - the tumor extends into the contralateral hemisphere generating a spectacular morphology, a symmetric bilateral transcallosal lesion described as "butterfly glioma". Cerebral white matter myelin structure and the elective white matter-routes (internal capsule, fornix, etc.) in GBM local extension opens the hypothesis of alterations at the cohabitation mechanisms level between - glial cells and the myelin sheet. Normally, besides structural proteins, in myelin structure there are a number of proteins with highly specific functions, called neurite growth inhibitors NI35/250- that inhibit the abnormal axonal regeneration, growth and proliferation of astrocytes and fibroblasts. Blocking the abovementioned with monoclonal antibodies led to a "leak" at the white matter level - as in vitro and in vivo studies show [14]. These white matter findings may be suggestive for the existence of an alteration in the mechanism of NI35/250 dampening in determining the invasive behavior of tumor cells particularly in the white matter. These characteristics suggest that GBM possesses specific biological mechanisms that mediate its invasive nature [57]. A sequential approach was proposed as a model of invasion [64]: 1) detachment of cells with invasive potential from the main tumor

mass 2) adhesion to extracellular matrix 3) degradation of the extracellular matrix 4) cell motility and contractility to integrate the infiltrated territory and further migration. In this sequence, there have been identified several "key-molecules". Some presumed signaling pathways to invasion are linked to constitutive cell-membrane proteins such as: RTK (EGFR, PDGFR), Integrins [87, 104] and CD44 [112, 77]. Overexpression of these membrane proteins, among other molecules is linked to GBM invasion.

The primary event - the detachment of cells from the primary tumor - involves a series of events that lead in a first phase to an unstable status of the cell in the tumor microenvironment. This event was blamed on the links provided by cadherin disintegration [20]. Cadherin provide a Ca²⁺-dependent transmembrane protein involved in cell adhesion, which contributes to the stabilization of the tissue cells. Abnormal high expression of cadherin 11 was identified in GBM, especially near vascular structures [50, 81]. The pivotal cell or cells so destabilized from the bulk tumor, can initiate the invasive path.

Continuing the invasive trajectory of the detached cells involves metalloproteinase activity (MMP) respectively MMP-2 and MMP-9 proteolytic activity which "destroy" barriers in the path of matrix invasion, while adaptive integration in microclimate is ongoing [30], as MMP are considered to be key regulators of the microclimate [52]. Moreover, levels of MMP-2 and MMP-9 are considered the strongest predictors of glioblastic invasive potential [108]. However, it also raises the

question of the selective high activity of these endopeptidase and orientation of the migratory route preferential toward areas discussed, as we still don't have a referential pattern of normal MMP in neural tissue, so that we can't shape an explanation of this "polarization" of the cell invasive route.

The cell that migrates from the bulk tumor in the invasive GBM model, must have two fundamental characteristics: contractility and motility. Myosin 2 is the substrate supposed to accomplish these 2 features. The migratory cell must adapt his diameter to fit in spaces even smaller than its nuclear diameter [6]. Isoforms A and B of myosin 2 are those which allow performing these narrow areas. Involvement of myosin 2 expression in invasive type behavior has been proved by the positive results of direct blocking of myosin 2 in counteracting GBM invasion [47].

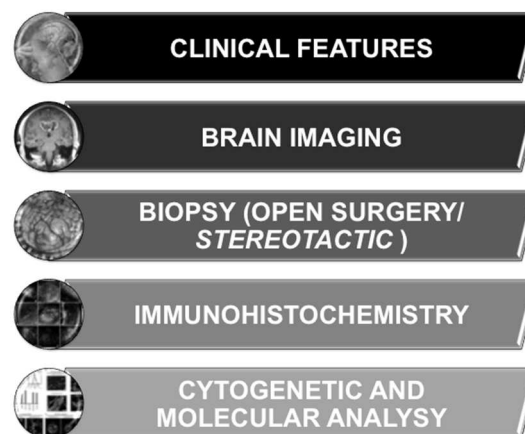


Figure 1 - The modern diagnostic sequencing for GBM

Going deeper into the tumor cell biology we can refer to transcription factors involved in abnormal pathways. As next-generation

sequencing technologies are emerging, transcriptome description brings into perspective new key-molecules in GBM invasion. A transcription factor is a structure that binds to a specific DNA region and controls the activity of selected genes. Transcription factors are overactive in cancer cells [23] and they are strong candidates as targets for future specific molecular therapies in cancer [102]: (1) the NF-kappaB and AP-1 families of transcription factors, 2) the STAT family members and 3) the steroids receptors are just some examples [60]. Transcription factor Olig2 is often expressed in oligodendroglia and in “transit-amplifying cells” of the subventricular zone, the presumed site of most adult neural stem/progenitor cells. Olig2 is frequently found in NG2-positive glia

and is required for development of these cells. NG2 is a chondroitin sulfate proteoglycan that is thought to be another marker of oligodendrocyte progenitor cells. Olig2 promotes the proliferation of both neural progenitors and GBM stem cells by repressing the p21 tumor suppressor [61]. TWIST is another transcription factor whose abnormal activity is related with GBM invasion-underlying a mesenchymal change in promoting invasion [18] by a process called epithelial to mesenchymal transition [69]. This would help the cells detached from the primary lesion to survive and further infiltrate the trajectory. TWIST1 is also a strong candidate as a target molecule for future therapies.

TABLE 1
Key molecules involved in GBM invasion and the underlying mechanism

<i>Molecule</i>	<i>Function</i>
CD44	<i>mediates ECM adhesion</i>
RHAMM	<i>mediates ECM adhesion</i>
MMP9	<i>CD44 cleavage=> ECM adhesion; degradation of ECM</i>
ADAM proteases	<i>CD44 cleavage=>ECM adhesion</i>
Integrins avB3 and avB5	<i>ECM adhesion and cytoskeletal rearrangement</i>
FAK and Pyk 2	<i>cytoplasmic mediators for integrins=> ECM adhesion</i>
MMP2	<i>degradation of ECM</i>
cadherin 11	<i>detachment of the cells from the tumor</i>
EGFR	<i>increases MMP1 expression=>degradation of ECM</i>
PTEN/PI3K/AKT pathway	<i>regulation of MMP activity=>ECM adhesion and rearrangement, PTEN mutation is linked to an invasive phenotype</i>
myosin II	<i>cell contractility and motility</i>
tf Olig2 and TWIST	<i>cell integration in the migration path</i>

This sequential model has a number of evidence-based arguments, and brings into the line a number of issues regarding GBM complex invasive mechanism, and further puts into perspective molecular therapeutic directions. But there are some obscure issues that remain to be elucidated as for example the probability of micro-regional heterogeneity in the extracellular matrix, the importance of co-expression and co-activation of surface receptors with consequent activation of cellular signaling mechanisms to initiate an invasive type of behavior, the exact order of any phase of the invasion and to what extent there is an overlap sequence in all above.

State of the art in the treatment of GBM

Genetic mutations, epigenetic modifications and micro-environmental heterogeneity cause resistance to radio- and chemotherapy altogether resulting in a hardly to overcome therapeutic scenario. Multiple challenges remain in high-grade gliomas management [83]. Upon initial diagnosis of glioblastoma, standard treatment consists of maximal surgical resection, radiotherapy, and concomitant and adjuvant chemotherapy with Temozolomide [11, 35] (in selected cases less aggressive therapy is employed-patients older than 70 years undergo radiation therapy or Temozolomide alone).

Patients should be evaluated by a specialized multidisciplinary team: antiepileptic drugs are prescribed for seizures; steroid-therapy, with glucose level monitoring; a careful assessment of the patients's ability to perform activity of daily living or to undergo therapy - Karnofsky performance status scale can be used, all above are important

therapeutic aspects- maintenance of quality of life should be the key end-point of the therapy [40].

Surgery is an integral part of GBM treatment [90]. Surgical removal of the glioblastoma by craniotomy can be beneficial for some people, both to alleviate symptoms associated with the tumor and to extend survival following radical removal. Also the only accurate diagnosis of GBM relies on biopsy sample. The only way to be sure that a brain tumor is a glioblastoma is by looking directly at the tumor tissue-either by performing an open surgery procedure or by stereotactic means. Fluorescence guidance in resection of malignant glioma has been shown to improve extent of resection and 6-month progression-free survival in a prospective, multi-institutional clinical and preliminary experience in the United States has confirmed the high correlation of this fluorescence with imaging and histologic features [99]. Of course that the outcome of surgical treatment in patients with GBM is highly influenced by tumor topography [97], extension [10] and the actual extent of the surgical resection [78]. Moreover, the extent of surgical resection is an independent prognostic factor-an analysis of 28 studies found a mean duration of survival advantage of total over subtotal resection for glioblastoma (14 vs. 11 month) [48].

The pivotal study of Stupp [101] in NEJM marked the split between pre and post Temozolomide era in the treatment of GBM. We can analyze the difference between the two periods in terms of survival [49, 22]: the median survival of patients treated with surgery and a regimen of radiation therapy was

12.0 months while patients who underwent surgical procedures, radiation therapy plus Temozolomide was 31.9 months. Before Temozolomide, Glioblastoma has been viewed as a chemo-resistant tumor. Temozolomide is currently used in the majority protocols for GBM treatment [17]. Adjuvant external-beam RT is well established in the postoperative treatment [56, 68]. The addition of radiotherapy to surgery has been shown to increase survival from 3-4 months to 7-12 months [100]. The responsiveness of glioblastoma to radiotherapy is highly variable. In many instances, radiotherapy can induce tumor remission, often marked with stability or regression of neurologic deficits as well as diminution in the size of the contrast-enhancing mass, but the period of response is short-lived because the tumor typically recurs within 1 year, resulting in further clinical deterioration and the appearance of an expansive region of contrast enhancement [45]. Alternative forms of fractionation have been investigated. Several studies have reported no improvements in terms of survival, but also no increased toxicity was found. Escalating doses beyond 60 Gy has not been shown to be of value.

In May 2009 FDA approved Bevacizumab for the treatment of Glioblastoma, as a single agent for patients with progressive disease following prior therapy. Bevacizumab is a vascular endothelial growth factor-specific angiogenesis inhibitor. The reasoning for using it in GBM resides in tumor pathogenesis, as mentioned before, one of the defining characteristics of GBM is an abundant and aberrant vasculature [38]. In a

simple approach - we try "to starve" the tumor by attacking his vascular backup. Since 2009, several Phase 2 studies and retrospective series have demonstrated that Bevacizumab significantly increased six-month progression-free survival [55] in patients with recurrent GBM and may do so in new-onset GBM [36]. Bevacizumab can be used as a single-agent therapy and in combination therapy with cytotoxic agents, specifically Irinotecan with no clear superiority among either regimen [71]. But despite general enthusiasm regarding Bevacizumab, in 2013 a Phase III, international study showed that it failed to increase overall survival (OS) or statistically significant progression-free survival (PFS) for Glioblastoma patients in the frontline setting. The randomized, double-blind, placebo-controlled study enrolled 637 patients all of whom were newly diagnosed with glioblastoma. Participants underwent surgery to resect some or most of the tumor, received the standard of care of chemo-radiation with Temozolomide, and were randomized to receive either Bevacizumab or placebo. The study was designed with two primary endpoints: PFS and OS [32]. So that the real benefit of Bevacizumab for patients with newly diagnosed GBM is still unclear [73].

Conclusion

New approaches for the management of GBM are necessary. A further understanding of the tumor pathways and enrollment of patients into clinical trials will generate new information regarding investigational therapies. All efforts should be directed to achieve not only a better overall prognosis, but

to get quality years of life for glioblastoma patients.

Correspondence

Florina Grigore

Emergency Clinical Hospital "Bagdasar-Arseni"

Berceni Street 10-12, Bucharest, Romania

E-mail: florina.grigore@icloud.com

References

1. Agnihotri, S., Burrell, K. E., Wolf, A., Jalali, S., Hawkins, C., Rutka, J. T., & Zadeh, G. (2013). Glioblastoma, a brief review of history, molecular genetics, animal models and novel therapeutic strategies. *Archivum immunologiae et therapiae experimentalis*, 61, 25–41. doi:10.1007/s00005-012-0203-0
2. Agrawal, A., Makannavar, J. H., Shetty, J. P., Shetty, L., & Varkey, B. (2012). Multifocal glioblastoma multiforme. *European Journal of General Medicine*, 9, 289–291. doi:citeulike-article-id:12139877
3. Alberts, B., Johnson, A., Lewis, J., Raff, M., Roberts, K., & And Walter, P. (2008). *Molecular Biology of the Cell. Amino Acids* (Vol. 54, p. 1725). Retrieved from <http://discovery.ucl.ac.uk/109973/>
4. Bailey, P., & Cushing, H. (1926). A classification of the tumors of the glioma group on a histogenetic basis with a correlated study of prognosis. *JAMA : the journal of the American Medical Association*, 87(4), 268.
5. Barnard, R. O., & Geddes, J. F. (1987). The incidence of multifocal cerebral gliomas. A histologic study of large hemisphere sections. *Cancer*.
6. Beadle, C., Assanah, M. C., Monzo, P., Vallee, R., Rosenfeld, S. S., & Canoll, P. (2008). The role of myosin II in glioma invasion of the brain. *Molecular biology of the cell*, 19, 3357–3368. doi:10.1091/mbc.E08-03-0319
7. Bleeker, F. E., Molenaar, R. J., & Leenstra, S. (2012). Recent advances in the molecular understanding of glioblastoma. *Journal of Neuro-Oncology*. doi:10.1007/s11060-011-0793-0
8. Bonnet, D., & Dick, J. E. (1997). Human acute myeloid leukemia is organized as a hierarchy that originates from a primitive hematopoietic cell. *Nature medicine*, 3, 730–737. doi:10.1038/nm0797-730
9. Brandes, A. A., Tosoni, A., Franceschi, E., Sotti, G., Frezza, G., Amistà, P., ... Ermani, M. (2009). Recurrence pattern after temozolomide concomitant with and adjuvant to radiotherapy in newly diagnosed patients with glioblastoma: correlation With MGMT promoter methylation status. *Journal of clinical oncology : official journal of the American Society of Clinical Oncology*, 27, 1275–1279. doi:10.1200/JCO.2008.19.4969
10. Bredel, M., Scholtens, D. M., Yadav, A. K., Alvarez, A. A., Renfrow, J. J., Chandler, J. P., ... Harsh, G. R. (2011). NFKBIA deletion in glioblastomas. *The New England journal of medicine*, 364, 627–637. doi:10.1056/NEJMoa1006312
11. Brem, S. S., Bierman, P. J., Black, P., Blumenthal, D. T., Brem, H., Chamberlain, M. C., ... Vronionis, F. D. (2005). Central nervous system cancers: Clinical Practice Guidelines in Oncology. *Journal of the National Comprehensive Cancer Network : JNCCN*, 3, 644–690.
12. Bruce, J. N. (n.d.). Glioblastoma Multiforme Clinical Presentation. Retrieved from <http://emedicine.medscape.com/article/283252-clinical>
13. Carmeliet, P., & Jain, R. K. (2000). Angiogenesis in cancer and other diseases. *Nature*, 407, 249–257. doi:10.1038/35025220
14. Caroni, P., & Schwab, M. E. (1988). Antibody against myelin-associated inhibitor of neurite growth neutralizes nonpermissive substrate properties of CNS white matter. *Neuron*, 1, 85–96. doi:10.1016/0896-6273(88)90212-7
15. CBTRUS; Central Brain Tumor Registry of the USA Hisdale. (2011). CBTRUS Statistical Report: Primary Brain and Central Nervous System Tumors Diagnosed in the United States in 2004-2007. CBTRUS Statistical Report. Retrieved from <http://www.cbtrus.org/2011-NPCR-SEER/WEB-0407-Report-3-3-2011.pdf>
16. Chakrabarti, I., Cockburn, M., Cozen, W., Wang, Y.-P., & Preston-Martin, S. (2005). A population-based description of glioblastoma multiforme in Los Angeles County, 1974-1999. *Cancer*, 104, 2798–2806. doi:10.1002/cncr.21539
17. Chang, S. M., Parney, I. F., Huang, W., Anderson, F. A., Asher, A. L., Bernstein, M., ... Laws, E. R. (2005). Patterns of care for adults with newly diagnosed malignant glioma. *JAMA : the journal of the American Medical Association*, 293, 557–564. doi:10.1001/jama.293.5.557
18. Childs, G., & Segall, J. E. (2012). Twists and turns of invasion. *Nature Cell Biology*. doi:10.1038/ncb2477
19. Chow, L. M. L., Endersby, R., Zhu, X., Rankin, S., Qu, C., Zhang, J., ... Baker, S. J. (2011). Cooperativity within

- and among Pten, p53, and Rb pathways induces high-grade astrocytoma in adult brain. *Cancer cell*, 19, 305–316. doi:10.1016/j.ccr.2011.01.039
20. Cifarelli, C. P. (2009). Cadherin-dependent adhesion of human glioblastoma cells promotes neurite outgrowth and increased migratory capacity. *Neuro-Oncology*, 11, 572. Retrieved from <http://www.embase.com/search/results?subaction=viewrecord&from=export&id=L70028680\http://neurooncol.og.ukejournals.org/cgi/reprint/11/5/563\http://dx.doi.org/10.1215/15228517-2009-034>
21. Colonnese, C., & Romanelli, P. (2012). Advanced neuroimaging techniques in the management of glioblastoma multiforme. *Curr Radiopharm.*
22. Darefsky, A. S., King, J. T., & Dubrow, R. (2012). Adult glioblastoma multiforme survival in the temozolomide era: a population-based analysis of Surveillance, Epidemiology, and End Results registries. *Cancer*, 118, 2163–2172. doi:10.1002/cncr.26494
23. Darnell, J. E. (2002). Transcription factors as targets for cancer therapy. *Nature reviews. Cancer*, 2, 740–749. doi:10.1038/nrc906
24. De Witte, O., Levivier, M., Violon, P., Salmon, I., Damhaut, P., Wikler, D., ... Goldman, S. (1996). Prognostic value positron emission tomography with [18F]fluoro-2-deoxy-D-glucose in the low-grade glioma. *Neurosurgery*, 39, 470–476; discussion 476–477.
25. Del Vecchio, C. A., Giacomini, C. P., Vogel, H., Jensen, K. C., Florio, T., Merlo, A., ... Wong, A. J. (2012). EGFRvIII gene rearrangement is an early event in glioblastoma tumorigenesis and expression defines a hierarchy modulated by epigenetic mechanisms. *Oncogene*. doi:10.1038/onc.2012.280
26. Doblaz, S., He, T., Saunders, D., Pearson, J., Hoyle, J., Smith, N., ... Towner, R. A. (2010). Glioma morphology and tumor-induced vascular alterations revealed in seven rodent glioma models by in vivo magnetic resonance imaging and angiography. *Journal of magnetic resonance imaging: JMRI*, 32, 267–275. doi:10.1002/jmri.22263
27. Dropcho, E. J., & Soong, S. J. (1996). The prognostic impact of prior low grade histology in patients with anaplastic gliomas: a case-control study. *Neurology*, 47, 684–690. doi:10.1212/WNL.47.3.684
28. England, B., Huang, T., & Karsy, M. (2013). Current understanding of the role and targeting of tumor suppressor p53 in glioblastoma multiforme. *Tumour biology: the journal of the International Society for Oncodevelopmental Biology and Medicine*, 34, 2063–74. doi:10.1007/s13277-013-0871-3
29. Fan, X., & Eberhart, C. G. (2008). Medulloblastoma stem cells. *Journal of clinical oncology: official journal of the American Society of Clinical Oncology*, 26, 2821–2827. doi:10.1200/JCO.2007.15.2264
30. Fillmore, H. L., VanMeter, T. E., & Broaddus, W. C. (2001). Membrane-type matrix metalloproteinases (MT-MMPs): expression and function during glioma invasion. *Journal of neuro-oncology*, 53, 187–202. doi:10.1023/A:1012213604731
31. Forsyth, P. A., & Posner, J. B. (1993). Headaches in patients with brain tumors: a study of 111 patients. *Neurology*, 43, 1678–1683. doi:10.1212/WNL.43.9.1678
32. Friedman, H. S., Prados, M. D., Wen, P. Y., Mikkelsen, T., Schiff, D., Abrey, L. E., ... Cloughesy, T. (2009). Bevacizumab alone and in combination with irinotecan in recurrent glioblastoma. *Journal of clinical oncology: official journal of the American Society of Clinical Oncology* (Vol. 27, pp. 4733–4740). doi:10.1200/JCO.2008.19.8721
33. Fulci, G., Labuhn, M., Maier, D., Lachat, Y., Hausmann, O., Hegi, M. E., ... Van Meir, E. G. (2000). p53 gene mutation and ink4a-arf deletion appear to be two mutually exclusive events in human glioblastoma. *Oncogene*, 19, 3816–3822. doi:10.1038/sj.onc.1203700
34. Gan, H. K., Kaye, A. H., & Luwor, R. B. (2009). The EGFRvIII variant in glioblastoma multiforme. *Journal of clinical neuroscience: official journal of the Neurosurgical Society of Australasia*, 16, 748–754. doi:10.1016/j.jocn.2008.12.005
35. Ghose, A., Lim, G., & Husain, S. (2010). Treatment for glioblastoma multiforme: current guidelines and Canadian practice. *Current oncology (Toronto, Ont.)*, 17, 52–58. doi:10.3747/co.v17i6.574
36. Gil-Gil, M. J., Mesia, C., Rey, M., & Bruna, J. (2013). Bevacizumab for the treatment of glioblastoma. *Clinical Medicine Insights. Oncology*, 7, 123–35. doi:10.4137/CMO.S8503
37. Hanahan, D., & Weinberg, R. A. (2011). Hallmarks of cancer: the next generation. *Cell*, 144(5), 646–674. doi:10.1016/j.yane.2012.02.046
38. Hardee, M. E., & Zagzag, D. (2012). Mechanisms of Glioma-Associated Neovascularization. *The American Journal of Pathology*. doi:10.1016/j.ajpath.2012.06.030
39. Heimberger, A. B., Hlatky, R., Suki, D., Yang, D., Weinberg, J., Gilbert, M., ... Aldape, K. (2005).

- Prognostic effect of epidermal growth factor receptor and EGFRvIII in glioblastoma multiforme patients. *Clinical cancer research: an official journal of the American Association for Cancer Research*, 11, 1462–1466. doi:10.1158/1078-0432.CCR-04-1737
40. Henriksson, R., Asklund, T., & Poulsen, H. S. (2011). Impact of therapy on quality of life, neurocognitive function and their correlates in glioblastoma multiforme: a review. *Journal of neuro-oncology*, 104, 639–646. doi:10.1007/s11060-011-0565-x
41. Holland, E. C. (2000). Glioblastoma multiforme: the terminator. *Proceedings of the National Academy of Sciences of the United States of America*, 97, 6242–6244. doi:10.1073/pnas.97.12.6242
42. Houston, S. C., Crocker, I. R., Brat, D. J., & Olson, J. J. (2000). Extraneural metastatic glioblastoma after interstitial brachytherapy. *International journal of radiation oncology, biology, physics*. doi:10.1016/S0360-3016(00)00662-3
43. Howlader, N., Noone, A. M., Krapcho, M., Neyman, N., Aminou, R., & Waldron, W. (2011). *SEER Cancer Statistics Review, 1975–2010*, National Cancer Institute. Bethesda, MD, based on November 2012 SEER data submission, posted to the SEER web site, 2013. http://seer.cancer.gov/csr/1975_2010 (Accessed on June 08, 2013).
44. Huang, P. H., Xu, A. M., & White, F. M. (2009). Oncogenic EGFR signaling networks in glioma. *Science signaling*, 2, re6. doi:10.1126/scisignal.287re6
45. Hulshof, M. C., Schimmel, E. C., Andries Bosch, D., & González González, D. (2000). Hypofractionation in glioblastoma multiforme. *Radiotherapy and oncology: journal of the European Society for Therapeutic Radiology and Oncology* (Vol. 54, pp. 143–148). doi:10.1016/S0167-8140(99)00183-8
46. Ichimura, K., Pearson, D. M., Kocialkowski, S., Bäcklund, L. M., Chan, R., Jones, D. T. W., & Collins, V. P. (2009). IDH1 mutations are present in the majority of common adult gliomas but rare in primary glioblastomas. *Neuro-oncology*, 11, 341–347. doi:10.1215/15228517-2009-025
47. Ivkovic, S., Beadle, C., Noticewala, S., Massey, S. C., Swanson, K. R., Toro, L. N., ... Rosenfeld, S. S. (2012). Direct inhibition of myosin II effectively blocks glioma invasion in the presence of multiple motogens. *Molecular Biology of the Cell*. doi:10.1091/mbc.E11-01-0039
48. Jeremic, B., Grujicic, D., Antunovic, V., Djuric, L., Stojanovic, M., & Shibamoto, Y. (1994). Influence of extent of surgery and tumor location on treatment outcome of patients with glioblastoma multiforme treated with combined modality approach. *Journal of neuro-oncology*, 21, 177–185. doi:10.1007/BF01052902
49. Johnson, D. R., & O'Neill, B. P. (2012). Glioblastoma survival in the United States before and during the temozolomide era. *Journal of Neuro-Oncology*. doi:10.1007/s11060-011-0749-4
50. H., Phillips-Mason, P. J., Burden-Gulley, S. M., Kerstetter-Fogle, A. E., Basilion, J. P., Sloan, A. E., & Brady-Kalnay, S. M. (2012). Cadherin-11, a Marker of the Mesenchymal Phenotype, Regulates Glioblastoma Cell Migration and Survival In Vivo. *Molecular Cancer Research*. doi:10.1158/1541-7786.MCR-11-0457
51. Kaye, A. H. . M. B. M. F.), & Laws, Edward R (MD, P. (n.d.). *Brain Tumors: An Encyclopedic Approach*.
52. Kessenbrock, K., Plaks, V., & Werb, Z. (2010). Matrix metalloproteinases: regulators of the tumor microenvironment. *Cell*, 141, 52–67. doi:10.1016/j.cell.2010.03.015
53. Kim, D. (1995). Chromosomal abnormalities in glioblastoma multiforme tumors and glioma cell lines detected by comparative genomic hybridization, 60(6), 812–9.
54. Kong, J., Cooper, L. A. D., Wang, F., Gutman, D. A., Gao, J., Chisolm, C., ... Brat, D. J. (2011). Integrative, Multimodal Analysis of Glioblastoma Using TCGA Molecular Data, Pathology Images, and Clinical Outcomes. *IEEE Transactions on Biomedical Engineering*, 58, 3469–3474. doi:10.1109/TBME.2011.2169256
55. Lamborn, K. R., Yung, W. K. A., Chang, S. M., Wen, P. Y., Cloughesy, T. F., DeAngelis, L. M., ... Prados, M. D. (2008). Progression-free survival: an important end point in evaluating therapy for recurrent high-grade gliomas. *Neuro-oncology*, 10, 162–170. doi:10.1215/15228517-2007-062
56. Laperriere, N., Zuraw, L., Cairncross, G., Cancer, T., & Ontario, C. (2002). Radiotherapy for newly diagnosed malignant glioma in adults: a systematic review. *Radiotherapy and oncology: journal of the European Society for Therapeutic Radiology and Oncology*, 64, 259–73. Retrieved from <http://www.ncbi.nlm.nih.gov/pubmed/12242114>

57. Lefranc, F., Brotchi, J., & Kiss, R. (2005). Possible future issues in the treatment of glioblastomas: special emphasis on cell migration and the resistance of migrating glioblastoma cells to apoptosis. *Journal of clinical oncology : official journal of the American Society of Clinical Oncology*, 23, 2411–2422. doi:10.1200/JCO.2005.03.089
58. Lemée, J.-M., Com, E., Clavreul, A., Avril, T., Quillien, V., de Tayrac, M., ... Menei, P. (2013). Proteomic analysis of glioblastomas: what is the best brain control sample? *Journal of proteomics*, 85, 165–73. doi:10.1016/j.jprot.2013.04.031
59. Levy, M. L., Ho, A. L., Hughes, S., Menon, J., & Jandial, R. (2008). Stem cells and the origin of gliomas: A historical reappraisal with molecular advancements. *Stem Cells and Cloning: Advances and Applications*, 1, 41–48. doi:http://dx.doi.org/10.2147/SCCAAS3851
60. Libermann, T. A., & Zerbini, L. F. (2006). Targeting transcription factors for cancer gene therapy. *Current gene therapy*, 6, 17–33. doi:10.2174/156652306775515501
61. Ligon, K. L., Huillard, E., Mehta, S., Kesari, S., Liu, H., Alberta, J. A., ... Rowitch, D. H. (2007). Olig2-regulated lineage-restricted pathway controls replication competence in neural stem cells and malignant glioma. *Neuron*, 53, 503–517. doi:10.1016/j.neuron.2007.01.009
62. Liwnicz, B. H., & Rubinstein, L. J. (1979). The pathways of extraneural spread in metastasizing gliomas: a report of three cases and critical review of the literature. *Human pathology*.
63. Lo, K. C., Bailey, D., Burkhardt, T., Gardina, P., Turpaz, Y., & Cowell, J. K. (2008). Comprehensive analysis of loss of heterozygosity events in glioblastoma using the 100K SNP mapping arrays and comparison with copy number abnormalities defined by BAC array comparative genomic hybridization. *Genes, chromosomes & cancer*, 47, 221–237. doi:10.1002/gcc.20524
64. Lois, C., García-Verdugo, J. M., & Alvarez-Buylla, A. (1996). Chain migration of neuronal precursors. *Science (New York, N.Y.)*, 271, 978–981. doi:10.1126/science.271.5251.978
65. Louis, D. N., Ohgaki, H., Wiestler, O. D., Cavenee, W. K., Burger, P. C., Jouvet, A., ... Kleihues, P. (2007). The 2007 WHO classification of tumours of the central nervous system. *Acta neuropathologica*, 114, 97–109. doi:10.1007/s00401-007-0243-4
66. Lun, M., Lok, E., Gautam, S., Wu, E., & Wong, E. T. (2011). The natural history of extracranial metastasis from glioblastoma multiforme. *Journal of Neuro-Oncology*. doi:10.1007/s11060-011-0575-8
67. McLendon, R., Friedman, A., Bigner, D., Van Meir, E. G., Brat, D. J., M. Mastrogiannis, G., ... Aldape, K. (2008). Comprehensive genomic characterization defines human glioblastoma genes and core pathways. *Nature*. doi:10.1038/nature07385
68. Mehta, M. P., Tomé, W. A., & Olivera, G. H. (2000). Radiotherapy for brain tumors. *Current oncology reports*, 2, 438–444. doi:10.1007/s11912-000-0064-2
69. Mikheeva, S. A., Mikheev, A. M., Petit, A., Beyer, R., Oxford, R. G., Khorasani, L., ... Rostomily, R. C. (2010). TWIST1 promotes invasion through mesenchymal change in human glioblastoma. *Molecular cancer*, 9, 194. doi:10.1186/1476-4598-9-194
70. Mokri, B. (2001). The Monro-Kellie hypothesis: applications in CSF volume depletion. *Neurology*, 56, 1746–1748. doi:10.1212/WNL.56.12.1746
71. Moustakas, A., & Kreisl, T. N. (2010). New treatment options in the management of glioblastoma multiforme: a focus on bevacizumab. *OncoTargets and therapy*, 3, 27–38. doi:10.2147/OTT.S5307
72. Nakada, M., Kita, D., Watanabe, T., Hayashi, Y., Teng, L., Pyko, I. V., & Hamada, J.-I. (2011). Aberrant Signaling Pathways in Glioma. *Cancers*. doi:10.3390/cancers3033242
73. Narayana, A., Gruber, D., Kunnakkat, S., Golfinos, J. G., Parker, E., Raza, S., ... Gruber, M. L. (2012). A clinical trial of bevacizumab, temozolomide, and radiation for newly diagnosed glioblastoma. *Journal of Neurosurgery*. doi:10.3171/2011.9.JNS11656
74. Normanno, N., De Luca, A., Bianco, C., Strizzi, L., Mancino, M., Maiello, M. R., ... Salomon, D. S. (2006). Epidermal growth factor receptor (EGFR) signaling in cancer. *Gene*, 366, 2–16. doi:10.1016/j.gene.2005.10.018
75. Ohgaki, H., Dessen, P., Jourde, B., Horstmann, S., Nishikawa, T., Di Patre, P.-L., ... Kleihues, P. (2004). Genetic pathways to glioblastoma: a population-based study. *Cancer research*, 64, 6892–6899. doi:10.1158/0008-5472.CAN-04-1337
76. Ohgaki, H., & Kleihues, P. (2007). Genetic pathways to primary and secondary glioblastoma. *The American journal of pathology*, 170, 1445–1453. doi:10.2353/ajpath.2007.070011

- 77.Okada, H., Yoshida, J., Sokabe, M., Wakabayashi, T., & Hagiwara, M. (1996). Suppression of CD44 expression decreases migration and invasion of human glioma cells. *International journal of cancer. Journal international du cancer*, 66, 255–260. doi:10.1002/(SICI)1097-0215(19960410)66:2<255::AID-IJC20>3.0.CO;2-A
- 78.Orringer, D., Lau, D., Khatri, S., Zamora-Berridi, G. J., Zhang, K., Wu, C., ... Sagher, O. (2012). Extent of resection in patients with glioblastoma: limiting factors, perception of resectability, and effect on survival. *Journal of Neurosurgery*. doi:10.3171/2012.8.JNS12234
- 79.Osborn, A. (n.d.). *Osborn's Brain: Imaging, Pathology, and Anatomy* (1 Har/Psc., p. 1200).
- 80.Pappas, S., & (LiveScience). (n.d.). No Title. Retrieved February 11, 2014, from <http://www.livescience.com/24098-colorful-but-deadly-images-of-brain-cancer.html>
- 81.Perego, C., Vanoni, C., Massari, S., Raimondi, A., Pola, S., Cattaneo, M. G., ... Pietrini, G. (2002). Invasive behaviour of glioblastoma cell lines is associated with altered organisation of the cadherin-catenin adhesion system. *Journal of cell science*, 115, 3331–3340.
- 82.Phillips, H. S., Kharbanda, S., Chen, R., Forrester, W. F., Soriano, R. H., Wu, T. D., ... Aldape, K. (2006). Molecular subclasses of high-grade glioma predict prognosis, delineate a pattern of disease progression, and resemble stages in neurogenesis. *Cancer cell*, 9, 157–173. doi:10.1016/j.ccr.2006.02.019
- 83.Preusser, M., de Ribaupierre, S., Wöhrer, A., Erridge, S. C., Hegi, M., Weller, M., & Stupp, R. (2011). Current concepts and management of glioblastoma. *Annals of neurology*, 70, 9–21. doi:10.1002/ana.22425
- 84.Quiñones-Hinojosa, A. (2012). *Schmidek and Sweet: Operative Neurosurgical Techniques. Indications, Methods and Results (Expert Consult - Online and Print)* (p. 2592). doi:10.1016/B978-1-4160-6839-6.10159-5
- 85.Rasheed, B. K., McLendon, R. E., Friedman, H. S., Friedman, A. H., Fuchs, H. E., Bigner, D. D., & Bigner, S. H. (1995). Chromosome 10 deletion mapping in human gliomas: a common deletion region in 10q25. *Oncogene*, 10, 2243–2246.
- 86.Reya, T., Morrison, S. J., Clarke, M. F., & Weissman, I. L. (2001). Stem cells, cancer, and cancer stem cells. *Nature*, 414, 105–111. doi:10.1038/35102167
- 87.Riemenschneider, M. J., Mueller, W., Betensky, R. A., Mohapatra, G., & Louis, D. N. (2005). In situ analysis of integrin and growth factor receptor signaling pathways in human glioblastomas suggests overlapping relationships with focal adhesion kinase activation. *The American journal of pathology*, 167, 1379–1387. doi:10.1016/S0002-9440(10)61225-4
- 88.Riezzo, I., Zamparese, R., Neri, M., De Stefano, F., Parente, R., Pomara, C., ... Fineschi, V. (2013). Sudden, unexpected death due to glioblastoma: report of three fatal cases and review of the literature. *Diagnostic pathology*, 8, 73. doi:10.1186/1746-1596-8-73
- 89.Rinkenbaugh, A. L., & Baldwin, A. S. (2011). Monoallelic deletion of NFKBIA in glioblastoma: when less is more. *Cancer cell*, 19, 163–165. doi:10.1016/j.ccr.2011.01.045
- 90.Roberts, D. W., Valdés, P. A., Harris, B. T., Hartov, A., Fan, X., Ji, S., ... Paulsen, K. D. (2012). Glioblastoma Multiforme Treatment with Clinical Trials for Surgical Resection (Aminolevulinic Acid). *Neurosurgery Clinics of North America*. doi:10.1016/j.nec.2012.04.001
- 91.Ropper, A. H., & Samuels, M. A. (2009). *Adams and Victor's Principles of Neurology, Ninth Edition*. McGrawHill.
- 92.Sanai, N., Alvarez-Buylla, A., & Berger, M. S. (2005). Neural stem cells and the origin of gliomas. *The New England journal of medicine*, 353, 811–822. doi:10.1056/NEJMra043666
- 93.Sanlı, A. M., Turkoglu, E., Dolgun, H., & Sekerci, Z. (2010). Unusual manifestations of primary Glioblastoma Multiforme: A report of three cases. *Surgical neurology international*, 1, 87. doi:10.4103/2152-7806.74146
- 94.Schmidt, M. C., Antweiler, S., Urban, N., Mueller, W., Kuklik, A., Meyer-Puttlitz, B., ... von Deimling, A. (2002). Impact of genotype and morphology on the prognosis of glioblastoma. *Journal of neuropathology and experimental neurology*, 61, 321–328.
- 95.Sherr, C. J., & McCormick, F. (2002). The RB and p53 pathways in cancer. *Cancer cell*, 2, 103–112. doi:10.1016/S1535-6108(02)00102-2
- 96.Showalter, T. N., Andrel, J., Andrews, D. W., Curran, W. J., Daskalakis, C., & Werner-Wasik, M. (2007). Multifocal glioblastoma multiforme: prognostic factors and patterns of progression. *International journal of radiation oncology, biology, physics*, 69, 820–824. doi:10.1016/j.ijrobp.2007.03.045
- 97.Simpson, J. R., Horton, J., Scott, C., Curran, W. J., Rubin, P., Fischbach, J., ... Nelson, J. S. (1993). Influence of location and extent of surgical resection on survival of patients with glioblastoma multiforme: results of three

- consecutive Radiation Therapy Oncology Group (RTOG) clinical trials. *International journal of radiation oncology, biology, physics* (Vol. 26, pp. 239–244). doi:10.1016/0360-3016(93)90203-8
98. Slack, J. M. W. (2008). Origin of stem cells in organogenesis. *Science* (New York, N.Y.), 322, 1498–1501. doi:10.1126/science.1162782
99. Stummer, W., Pichlmeier, U., Meinel, T., Wiestler, O. D., Zanella, F., & Reulen, H.-J. (2006). Fluorescence-guided surgery with 5-aminolevulinic acid for resection of malignant glioma: a randomised controlled multicentre phase III trial. *The lancet oncology* (Vol. 7, pp. 392–401). doi:10.1016/S1470-2045(06)70665-9
100. Stupp, R., Hegi, M. E., Gilbert, M. R., & Chakravarti, A. (2007). Chemoradiotherapy in malignant glioma: standard of care and future directions. *Journal of clinical oncology: official journal of the American Society of Clinical Oncology*, 25, 4127–4136. doi:10.1200/JCO.2007.11.8554
101. Stupp, R., Hegi, M. E., Mason, W. P., van den Bent, M. J., Taphoorn, M. J. B., Janzer, R. C., ... Mirimanoff, R.-O. (2009). Effects of radiotherapy with concomitant and adjuvant temozolomide versus radiotherapy alone on survival in glioblastoma in a randomised phase III study: 5-year analysis of the EORTC-NCIC trial. *The lancet oncology* (Vol. 10, pp. 459–466). doi:10.1016/S1470-2045(09)70025-7
102. Thorne, J. L., Campbell, M. J., & Turner, B. M. (2009). Transcription factors, chromatin and cancer. *The international journal of biochemistry & cell biology*, 41, 164–175. doi:10.1016/j.biocel.2008.08.029
103. Tran, D. K. T., & Jensen, R. L. (2013). Treatment-related brain tumor imaging changes: So-called “pseudoprogression” vs. tumor progression: Review and future research opportunities. *Surgical neurology international*, 4, S129–35. doi:10.4103/2152-7806.110661
104. Uhm, J. H., Gladson, C. L., & Rao, J. S. (1999). The role of integrins in the malignant phenotype of gliomas. *Frontiers in bioscience: a journal and virtual library*, 4, D188–D199. doi:10.2741/Uhm
105. Wang, Y., & Jiang, T. (2013). Understanding high grade glioma: molecular mechanism, therapy and comprehensive management. *Cancer letters*, 331, 139–46. doi:10.1016/j.canlet.2012.12.024
106. Watanabe, K., Tachibana, O., Sata, K., Yonekawa, Y., Kleihues, P., & Ohgaki, H. (1996). Overexpression of the EGF receptor and p53 mutations are mutually exclusive in the evolution of primary and secondary glioblastomas. *Brain pathology* (Zurich, Switzerland), 6, 217–223; discussion 23–24. doi:10.1097/00005072-199605000-00017
107. Watanabe, T., Nobusawa, S., Kleihues, P., & Ohgaki, H. (2009). IDH1 mutations are early events in the development of astrocytomas and oligodendrogliomas. *The American journal of pathology*, 174, 1149–1153. doi:10.2353/ajpath.2009.080958
108. Wild-Bode, C., Weller, M., & Wick, W. (2001). Molecular determinants of glioma cell migration and invasion. *Journal of neurosurgery*, 94, 978–984. doi:10.3171/jns.2001.94.6.0978
109. Wilkinson, I., & Lennox, G. (2005). *Essential Neurology* (4th ed., p. 288). Wiley-Blackwell.
110. Wu, X.-Z. (2008). Origin of cancer stem cells: the role of self-renewal and differentiation. *Annals of surgical oncology*, 15, 407–414. doi:10.1245/s10434-007-9695-y
111. Yang, Z.-J., Ellis, T., Markant, S. L., Read, T.-A., Kessler, J. D., Bourboulas, M., ... Wechsler-Reya, R. J. (2008). Medulloblastoma can be initiated by deletion of Patched in lineage-restricted progenitors or stem cells. *Cancer cell*, 14, 135–145. doi:10.1016/j.ccr.2008.07.003
112. Yoshida, T., Matsuda, Y., Naito, Z., & Ishiwata, T. (2012). CD44 in human glioma correlates with histopathological grade and cell migration. *Pathology international*, 62, 463–70. doi:10.1111/j.1440-1827.2012.02823.x
113. Zhou, J., Tryggstad, E., Wen, Z., Lal, B., Zhou, T., Grossman, R., ... van Zijl, P. C. M. (2011). Differentiation between glioma and radiation necrosis using molecular magnetic resonance imaging of endogenous proteins and peptides. *Nature medicine*, 17, 130–134. doi:10.1038/nm.2268