

Article

When hanging caused an intracranial haemorrhage - a rare case report

Vardan Kulshreshtha, Ashok Kumar, Gaurav Jaiswal, Tarun Kumar Gupta
INDIA



When hanging caused an intracranial haemorrhage - a rare case report

**Vardan Kulshreshtha, Ashok Kumar, Gaurav Jaiswal,
Tarun Kumar Gupta**

Department Of Neurosurgery, RNT Medical College, Udaipur, INDIA

Abstract: Depressive illness is a growing health hazard into modern era days. Depression may sometimes result in suicidal tendency in a major number of patients. Suicidal attempt not only leads to loss of life, but also a significant number of survivors retain various morbidity. We here report a rare case of intracranial haemorrhage (ICH) following a suicidal attempt by hanging.

Key words: suicidal hanging, intracranial haemorrhage

Introduction

Depression is a common disorder in modern world. Its prevalence is rising and there are a number of reasons behind. The depression is a treatable disorder. A major number of patients with depression present to the physicians with unexplainable vague complaints and this happen mostly in primary care settings. The average national deficit of psychiatrists in India is estimated to be 77% which may be as high as 90% in certain states individually. (1) Hence to get proper and timely treatment in Indian scenario is rather a difficult task. The depression has been rated as the third leading cause of the global burden of the disease accounting for 4.3% of the disability adjusted life years (DALY). It will be a leading cause of

disease burden by year 2030. (2, 3) Patients often has the tendency to commit suicide in course of their depressive disease. The problem is worse in those suffering from chronic depression. We here report a case of patient of depressive disorder who presented to us with ICH immediately following a suicidal attempt by hanging.

Case report

A 30 year old male patient was referred to the department of neurosurgery from department of emergency medicine with alleged history of suicidal attempt by hanging. The patient was a diagnosed case of depression but defaulter on treatment. No history of substance abuse or any chronic drug intake was present. There was a history

of attempted suicide in past also. The vitals were all within normal limits. The Glasgow coma scale (GCS) was E2V2M5 with dilated left side pupil. There was right sided hemiparesis noted with left sided facial weakness. There was ligature mark noted around the neck. There were no other external injury marks over the scalp and elsewhere over the body. Non contrast computed tomography (NCCT) head revealed a large ICH in left in thalamoganglionic region with intraventricular haemorrhage with significant mass effect and midline shift of 9 mm to contralateral side. Left side frontotemporoparietal (FTP) decompressive craniotomy was done. The ICH was evacuated completely and duroplasty performed. The patient was managed postoperatively as per the standard institutional protocols. The patient was discharged in satisfactory condition with advice to review in psychiatry clinics. On 6 month and 1 year follow up the patient was well and independent.

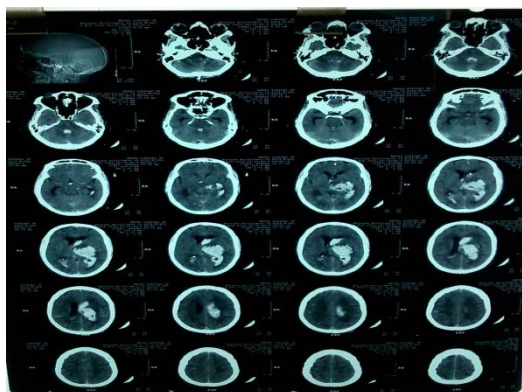


Figure 1 - Preoperative CT scan

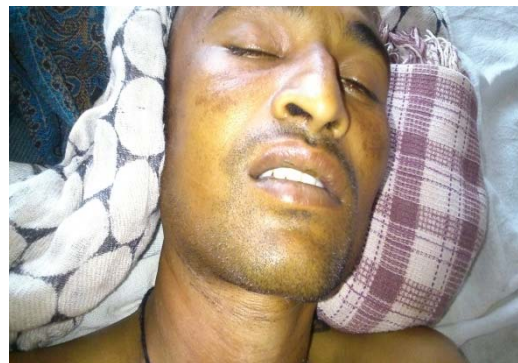

Figure 2 - Photo of patient with ligature mark on neck

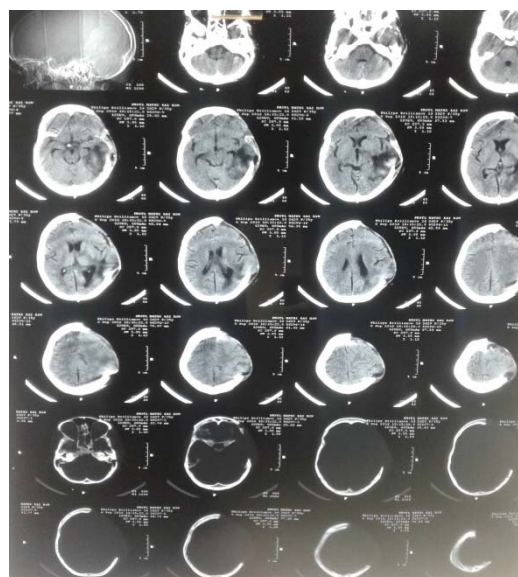


Figure 3 - Postoperative CT scan

Discussion

Recently it has been found that 10-15% patients in their life time suffer a major depressive illness⁴ and 5% suffer from a major depression in a given year. (5) In Indian scenario the overall prevalence of depression is 15.9% roughly similar to the global prevalence. (6) More than half of the depression patients may have suicidal

ideation (7). One of the study from India reported suicidal attempts in 16% patients of depression. (8) Further those attempted suicide once had a higher tendency to commit suicide in future too. Various modes of attempting suicide are hanging, drowning, poisoning, drug over dosage, self inflicted gun shots/burns etc. As per the National crime records Bureau (NCRB) of India, total number of suicides committed in 2014 were 1,31,666. The number of suicides in the country during the decade (2004–2014) has recorded an increase of 15.8% (1,31,666 in 2014 from 1,13,697 in 2004).

When a person attempts a suicide he may lose his life or may be saved if timely intervened by some help. The survivors may also end up with various morbidities. Hanging is a form of strangulation that involves suspension of body with the ligature tied around the neck. Weight of body acts. Hangings may be sub classified as complete or incomplete. When the whole body hangs off the ground and the entire weight of the victim is suspended at the neck, the hanging is said to be complete. Incomplete hangings imply that some part of the body is touching the ground and that the weight of the victim is not fully supported by the neck. Hangings may also be classified by intent (e.g., homicidal, suicidal, autoerotic, accidental). The various injuries that take place while a person attempts hanging are asphyxia, venous congestion of brain, cerebral ischemia, fracture/ dislocation of cervical vertebra. Various changes which have been described in the literature are diffuse cerebral hypoxia, diffuse cerebral oedema,

subarachnoid haemorrhage, arterial intimal injury. The hanging causes a form of asphyxia. Most of the patients die because of the hypoxic ischemic neuronal damage.

There has been to date no case report in the literature of neurosurgery and forensic medicine about development of ICH in victim surviving hanging. We report this case to bring this rare presentation of hanging resulting in ICH and later on uneventful recovery without any neurological deficit.

Conclusion: The various manifestations of hanging have been described in literature such as anoxic edema, hypoxic encephalopathy, venous brain congestion. Occurrence of ICH after hanging should be kept in mind especially in those not gaining consciousness on time or showing focal neurological deficits. Timely diagnosis and intervention can be life saving in these patients.

Correspondence

Vardan Kulshreshtha, 41-B, Ambamata Scheme ,
Udaipur, Rajasthan(India)
E-mail: drvardan@gmail.com, +917023334765

References

1. World Health Organisation. Global burden of disease report, 2004 update. Available at http://www.who.in/healthinfo/global_burden_disease/GBD_report_2004update_fullpdf.
2. Ostun, T.B., Ayuso-Mateos, J.L., Chatterji, S., Mathers, C., Murray, C.J.L. Global burden of depressive disorder in the year 2000. *British Journal of Psychiatry*, 184, 386-92, 2004.
3. Thirunavukarasu, M., Thirunavukarasu, P. Training and national deficit of psychiatrists in India- A critical analysis. *Indian J Psychiatry*, 52, 83-8. 2010.
4. Bromet, E., Andrade, L.H., Hwang, I., Sampson, N.A., Alonso, J., de Girolamo, G, et al. Cross- national

epidemiology of DSM-IV major depressive episodes. BMC Med, 9, 90. 2000

5. Murphy, J. M., Laird, N.M., Monson, R.R., Sobel, A.M., Leighton, A.H. A 40 year perspective on the prevalence of depression. The sterling county study. Arch Gen Psychiatry, 57, 209-15, 2000.

6. Poongothai, S., Pradeepa ,R., Ganesan, A., Mohan,V. Prevalence of depression in a large sub urban south Indian population. The Chennai urban rural epidemiology study (CURES-70).Plos One2009;4:E7185

7.Sokero TP, Melartin TK, Rytsälä HJ, Leskelä US, Lestelä-Mielonen PS, Isometsä ET.Suicidal ideation and attempts among psychiatric patients with major depressive disorder. J Clin Psychiatry 2003;64:1094-100.

8.Srivastava AS, Kumar R. Suicidal ideation and attempts in patients with major depression: Sociodemographic and clinical variables. Indian J Psychiatry 2005;47:225-8.