

# COMPELLING COMMENTS

## The Cutaneous Horn: Fascinating Since 1588

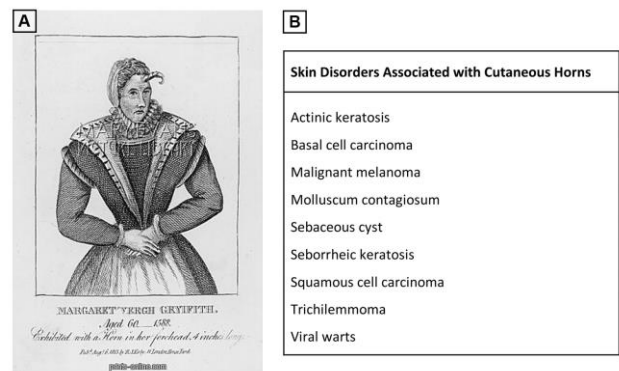
Nicole Nagrani BS<sup>a</sup>, Adrianna Gonzalez BS<sup>a</sup>, Anna Nichols MD, PhD<sup>a,b</sup>

<sup>a</sup>Department of Dermatology and Cutaneous Surgery, University of Miami Miller School of Medicine, Miami, FL

<sup>b</sup>Department of Dermatology and Cutaneous Surgery, Sylvester Comprehensive Cancer Center, Miami, FL

In 1588, Margaret Gryffith captured the attention of many after growing a four-inch horn from her forehead (Figure 1A). According to folklore, Margaret’s husband, just before his death, accused her of “giving him the horn,” a phrase implying that she had been unfaithful. Margaret denied this allegation and countered that a horn would grow from her forehead if she had committed adultery. According to the legend, a horn did grow and suggested to people that this “unworldly horn” was a warning for others to repent their sins and ask God for forgiveness. Margaret was put on display in London, attracting poets and playwrights, who would later document their observations in their writings.<sup>1</sup> These descriptions are thought to be the first written record of a cutaneous horn.

In 1598, 35-year-old Frenchman Francois Trouvillou was discovered in France with a large, finger-length horn protruding from his forehead that curved backwards nearly penetrating his scalp.<sup>2</sup> Trouvillou’s case was documented in Judge Du Thou’s historical anecdotes. In 1642 Thomas Bartholin encountered this report, which stimulated his interest in cutaneous horns and propelled



**Figure 1.** (A) A depiction of Margaret Gryffith (image reproduced with permission from the Mary Evans Picture Gallery). (B) Table listing skin conditions associated with cutaneous horns.

him to investigate them further. Ultimately, Bartholin concluded that cutaneous horns were not supernatural phenomenon as originally believed, but rather were produced by skin tumors. Bartholin’s work prompted German scholar Georg Franck von Franckenau to write the first article dedicated to the cutaneous horn. Published in 1676, *Tractatus Philologico-Mediscus de Cornutis* describes a series of 25 cases of cutaneous horns reported by multiple medical dignitaries.<sup>2</sup>

In 1791, Everard Home published an article supporting Bartholin's hypothesis that cutaneous horns were tumors that resulted from altered skin growth.<sup>3</sup> It is now well-established that cutaneous horns are composed of cornified keratinaceous material, have a predilection for sun-exposed skin, and can arise from benign, pre-malignant, and malignant skin lesions (Figure 1B).<sup>2</sup>

**Conflict of Interest Disclosures:** None.

**Funding:** None.

**Corresponding Author:**

Nicole Nagrani, BS  
Department of Dermatology and Cutaneous Surgery  
University of Miami Miller School of Medicine  
[NXN237@miami.edu](mailto:NXN237@miami.edu)

---

**References:**

1. Wood JO. Woman with a horn. *Huntington Library Quarterly* 1966; 29: 295–300.
2. Bondeson J. Everard Home, John Hunter, and cutaneous horns: a historical review. *The American Journal of dermatopathology*. 2001;23(4):362-369.
3. Home E. Observations on certain horny excrescences of the human body. *Philos Trans R Soc Lond B Biol Sci* 1791; 81: 95–105.