

Oncologic Outcomes of a Novel Mapping Biopsy Technique Before Surgical Excision in the Management of Extramammary Paget Disease

 Kyle M. Rose, ¹ Rosalie Zurlo,²  Roger Li,¹ Gerard Mosiello,³  Philippe E. Spiess¹

¹Department of Genitourinary Oncology, Moffitt Cancer Center, Tampa, United States ²University of South Florida, Morsani College of Medicine, Tampa, United States

³Department of Cutaneous Oncology, Moffitt Cancer Center, Tampa, United States

Abstract

Objective To analyze oncologic outcomes of patients with extramammary Paget disease (EMPD) undergoing a novel mapping biopsy before tumor excision (WLE).

Methods We analyzed 19 consecutive patients with EMPD treated with biopsy and/or surgical excision at Moffitt Cancer Center from 2013 to 2021. Biopsy technique, patient demographics, pathology, and oncologic outcomes were analyzed.

Results In total, 19 patients were included in the analysis. Median age at diagnosis was 72. No patients were diagnosed with secondary malignancy during mandatory workup. Of the 17 patients receiving novel mapping biopsy, 8/17 had at least one positive core biopsy site, with a mean of 7% positivity of the total core sites (4/60). Mapping biopsy positive sites helped shape perimeters for wide local excision (WLE) for patients opting for surgical treatment. Although an extensive mapping biopsy was performed, WLE margins were positive in 11/17 patients. Although positive pathologic margins following surgical excision were prominent, only one patient experienced recurrence of EMPD during a median follow-up period of 38 months.

Conclusions We have demonstrated a standardized mapping biopsy before surgical excision in the management of EMPD in men. Despite extensive mapping biopsies, positive surgical margin rates are high, and this may reflect the occult nature of the disease process. Close follow-up is warranted in patients regardless of margin status, but those with positive surgical margins may benefit from more aggressive regimens.

Introduction

Extramammary Paget disease (EMPD) is a rare neoplasm presenting in the genital and perianal regions of men and women. It is characterized by a chronic erythematous plaque and is commonly associated with pruritis and pain^[1]. The discomfort associated with the lesions often leads to mischaracterization as eczema or fungal infection, which may further delay treatment. Unfortunately, despite standard of care measures, recurrence rates as high as 16% to 61% have been reported^[2–5]. Surgical excision with negative margins is the gold standard in management, but topical and systemic chemotherapy can also be used if there are contraindications to surgery^[6].

Key Words

Biopsy, extramammary Paget disease, recurrence, oncology

Competing Interests

None declared.

Article Information

Received on May 17, 2022
Accepted on August 19, 2022
This article has been peer reviewed.

Soc Int Urol J. 2023;4(1):34–38

DOI: 10.48083/LCME5237

EMPD is treated by a variety of specialties including urologists, colorectal surgeons, and dermatologists, depending on location and patient access to care. As a result, there is no standardized biopsy or wide local excision (WLE) technique for EMPD to ensure negative resection margins. Dermatologists frequently utilize Mohs micrographic surgery to provide pathological confirmation of negative margins intraoperatively. In contrast, WLE is traditionally employed by urologists and colorectal surgeons, and requires a pre-resection biopsy. In either case, standardization of biopsy and excision technique is lacking.

The establishment of a global strategy for mapping before excision is paramount in the surgical management of EMPD. Herein, we describe a novel standardized technique in the mapping and treatment of EMPD at our institution. Our objective was to determine the efficacy of this mapping technique before excision by analyzing recurrence rates of EMPD, thereby assessing the accuracy of surgical margin delineation.

Materials and Methods

After obtaining institutional review board approval, we performed an analysis on patients undergoing surgical excision for EMPD at our facility between 2013 and 2021. For inclusion, patients were required to have had a mapping biopsy and/or WLE. All cases were performed by a single surgeon. All patients underwent mandatory cystoscopy and colonoscopy, which were required to be negative. Patient demographics, clinicopathologic outcomes, and perioperative outcomes were collected. Patient clinical stage was determined using the TNM staging system for EMPD as described by Ohara et al.[7]. Perioperative complications were scored using the modified Clavien-Dindo scale[8].

The technique for mapping biopsy before excision involves 60 total biopsy sites, taken in a clockwise fashion around the lesion. The biopsies are typically 1.5 mm in size, and 5 are taken for each “hour” of the clock face, spaced 1 cm apart. This technique allows the surgical team to clearly demarcate the required tissue needed to achieve a negative margin at the time of WLE. All biopsy specimens were reviewed by a dedicated dermatopathologist.

Results

From 2013 to 2021, 19 patients underwent mapping biopsy followed by WLE. The median age (IQR) at surgery was 72 (66.5 to 76.0). **Table 1** details baseline patient characteristics. Of note, 13 (65%) had a history of malignancy before EMPD diagnosis, the most common of which was a dermatologic carcinoma in 12 patients, followed by prostate cancer in 4 patients.

TABLE 1.

Clinical characteristics of patients before mapping biopsy

Age (median, IQR)	72 (76.0–66.5)
Prior cancer diagnoses	13 (68%)
Smoking history	11 (47%)
Prior failed treatment	3 (16%)
Symptomatic at presentation	9 (47%)
Presence of multifocality	1 (5%)
Positive mapping biopsy	10 (53%)
Cores positive on mapping biopsy	4 (6.7%)

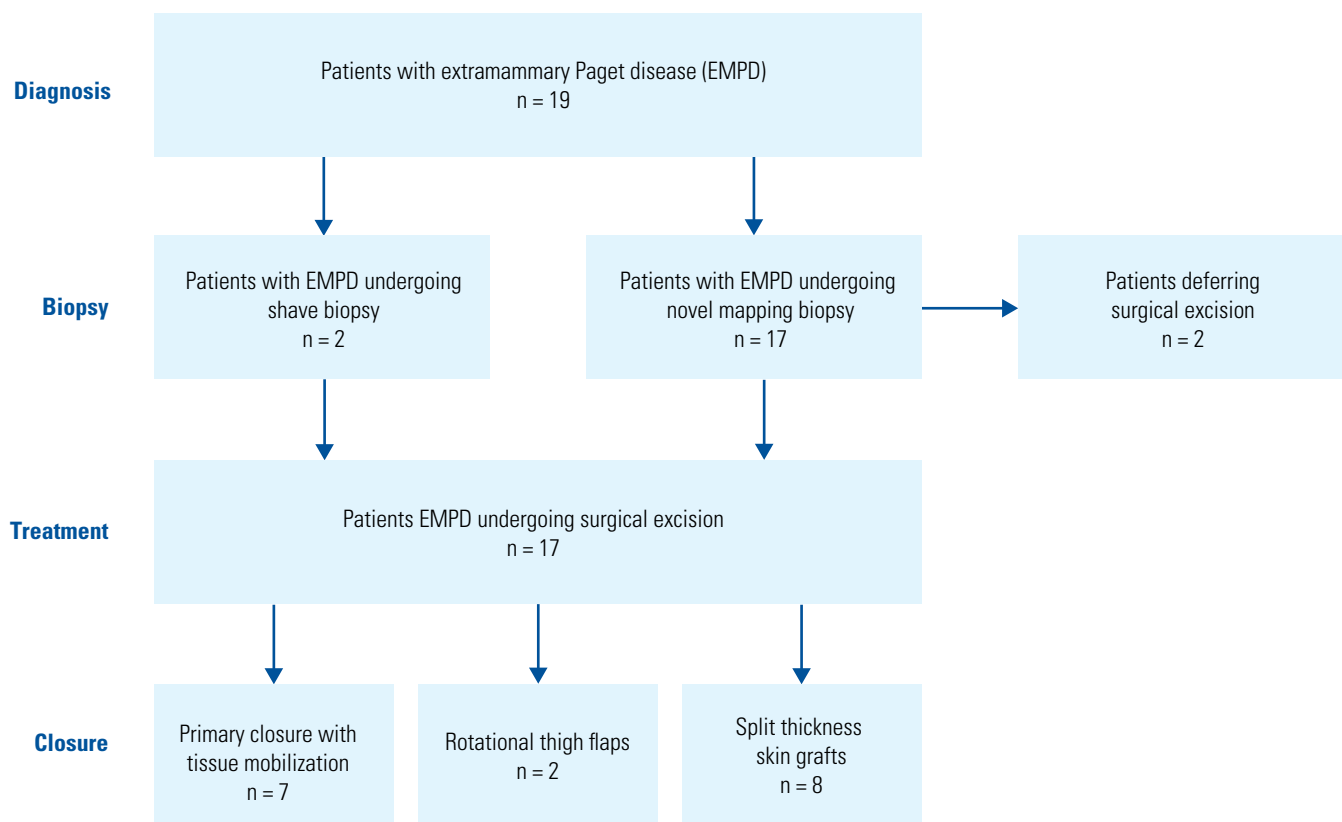
Eleven patients (58%) had a past or current history of smoking. Most patients had at least one medical comorbidity, with 14 diagnosed with hypertension, 8 with hyperlipidemia, 7 with CAD, and 7 with BPH.

Three patients were treated with topical chemotherapy before presentation, while 6 patients were treated with topical antifungals due to misdiagnosis. Preoperative irritative symptoms were reported in 9 patients (47%) at a median (IQR) duration of 2.5 (1.0 to 3.0) years, and included erythema in 17 (89%), itching in 10 (53%), pain in 8 (42%), and drainage in 2 (11%). EMPD occurred in the scrotum-alone in 8 (42%), the perineum in 1 (5%), the groin in 3 (16%), the penis in 2 (11%), and was multifocal in 6 (32%).

Seventeen patients received mapping biopsy, and 2 had shave biopsies. Two patients decided against surgical excision of lesion after biopsy, opting for conservative monitoring. Eight mapping biopsies (47%) were positive for EMPD in at least one core, with an average of 7% of cores positive (4/60). Mapping biopsy results were used to delineate WLE borders, and negative results typically indicated a smaller resection site. Of the 17 patients undergoing surgical excision, 16 had WLE. For wound closure, 8 patients required split thickness skin graft (STSG), in 3, local tissue mobilization was used to assist in closure, 2 patients required creation of a thigh flap, and in 1 case, primary re-approximation was used (**Figure 1**).

All patients were staged as primary pT1 EMPD on final pathology. Margins were positive in 65% of lesions (11/17). Of the 13 patients with immunohistochemistry

FIGURE 1.



staining. Ck7 was positively stained in 10 cases (77%). Lymphovascular and adnexal invasion were uncommon, both occurring in 3 of 7 patients. The median follow-up for the cohort was 14 months, during which time 1 patient experienced recurrence with osseous metastasis 6 years following WLE, and is currently undergoing chemoradiation therapy. During follow-up, there was 1 death of unrelated etiology.

Complications occurred in 5 patients (29%), all related to wound healing. There were 2 episodes of wound dehiscence, one episode of skin necrosis requiring debridement, one episode of tension discomfort requiring repeat STSG, and one episode of prolonged wound healing with abnormal drainage. **Table 2** illustrates the size of excised lesions in patients with and without wound complications, for which there were no differences between groups.

Discussion

In this series, we describe a standardized mapping biopsy process for EMPD. Our central finding is the high positive WLE margin rate despite extensive preoperative punch biopsy mapping. While surgical excision with negative resection margins remains the gold standard treatment in EMPD, barriers to achieving negative margins include the multifocal nature of this

TABLE 2.

Postoperative wound issue and size of primary lesion

	Wound Complications Post-WLE		P-value
	Yes	No	
Median size of lesion (cm)	121	124.6	0.74
IQR	66–168	85–147	

disease process, as well as the presence of skip lesions. Positive margins have been identified as risk factors for tumor invasion, recurrence, and metastasis in prior EMPD series^[9,10]. In a recently published review by Leong and Chung, the investigators compiled composite scores for recurrence based on margin status at the time of excision. Patients with positive margins at WLE demonstrated a higher recurrence rate of 48% versus 15% in those with negative margins. Similarly, the authors compared composite scores of WLE and Mohs micrographic surgery, and identified Mohs as having a lower positive margin rate (18% versus 33%). The use of Mohs surgery may be a limiting

factor depending on resources available to certain institutions, but microdissection and pathologic review in real time appear to be beneficial. Additional surgical augmentations include the use of intraoperative frozen sections, which has demonstrated a higher negative margin rate (92% versus 26%)[11]. Additionally, surgeons have utilized fluorescein to augment visualization during excision, which has a 97% positive predictive value and 99.9% negative predictive value[12]. Both of these tools add value in the surgeon's armamentarium.

The high positive surgical margin rate in our series is unfortunately a common, with previous studies reporting rates as high as 40% to 60% after surgical excision[13–17]. However, while recurrence rates are higher in margin-positive patients, the direct impact on cancer specific survival is less clear, especially in the non-invasive malignancy setting. In a survival analysis using the Surveillance, Epidemiology, and End Results (SEER) program, worse survival was associated with increased age and male sex, and in patients who did not receive surgery as primary therapy, especially those who had received radiotherapy[18]. A similar SEER study performed by Herrel and colleagues reported an overall survival of 60% at 120 months post diagnosis[19]. The authors identified that patient age and presence of EMPD in the perianal and truncal regions portended a worse prognosis[19]. However, it is important to note the limitations of these 2 large-sample studies, in that the SEER database does not allow for analysis by margin status. Alternatively, tumor invasion was identified as a significant contributor to survival, as described in the study by Hegarty et al. of 20 patients, in which patients with invasive EMPD demonstrated a lower survival rate of 14.5 months versus 55 months in those with intra-epidermal adenocarcinoma[9].

Our findings suggest that positive surgical margins may not correlate as strongly with recurrence as previously thought. The presence of positive surgical margins does place the patient in a higher risk group,

which prompts the surgical team to escalate outpatient follow-up and surveillance. In clinical practice, this could include more frequent examinations, repeat biopsies for recurrent disease, and photograph documentation. The novel mapping biopsy and WLE in our study were performed by a single surgeon to improve uniformity and consistency. Importantly, surgeons should be aware of the potential for wound complications following WLE, which occurred in 5 patients in our series.

Limitations of our study include its retrospective nature, presenting the potential for selection bias among patients with localized disease. The novel mapping biopsy and WLE utilized in our study was performed by a single surgeon to improve uniformity and consistency. Additionally, our patients were exclusively male, and therefore extrapolation of our findings to the gynecologic field should be limited. Further, the median follow-up in our cohort was relatively short at 14 months. Long-term follow-up data are needed to solidify the relationship between positive surgical margins and disease recurrence. Due to the rarity of this disease process, large-scale randomized trials will be unlikely to accrue, and thus there is a need for uniform mapping biopsies and surgical techniques, as previously described.

Conclusions

In this study, we have demonstrated a standardized mapping biopsy before surgical excision in the management of EMPD in men. Despite extensive mapping biopsies, positive surgical margin rates are high, and this may reflect the occult nature of the disease process. Close follow-up is warranted in patients regardless of margin status, but those with positive surgical margins may benefit from more aggressive regimens. Long-term follow-up is needed to determine the impact of microscopically positive margins on disease specific survival, which will aid the surgical team in determining aggressiveness of resection.

References

- McDaniel B, Brown F, Crane JS. Extramammary Paget disease. In: StatPearls. *Treasure Island*(FL)2022 Jan. Available at: <https://pubmed.ncbi.nlm.nih.gov/29630276/>. Accessed November 12, 2022.
- Hendi A, Brodland DG, Zitelli JA. Extramammary Paget's disease: surgical treatment with Mohs micrographic surgery. *J Am Acad Dermatol*.2004;51(5):767-773. doi: 10.1016/j.jaad.2004.07.004.
- Lee KY, Roh MR, Chung WG, Chung KY. Comparison of Mohs micrographic surgery and wide excision for extramammary Paget's disease: Korean experience. *Dermatol Surg*.2009;35(1):34-40.
- Pierie JP, Choudry U, Muzikansky A, Finkelstein DM, Ott MJ. Prognosis and management of extramammary Paget's disease and the association with secondary malignancies. *J Am Coll Surg*. 2003;196(1):45-50.
- Wong DS-Y Ko LW-L, Cheung T-H. Extramammary Paget's disease: surgical control from the plastic surgery perspective. *Surg Pract*.2016;20(3):110-113. doi.org/10.1111/1744-1633.12188
- NIH, National Center for Advancing Translational Sciences. Extramammary Paget disease.2021. Available at: <https://rarediseases.info.nih.gov/diseases/4192/extramammary-paget-disease>. Accessed September 17, 2021.
- Ohara K, Fujisawa Y, Yoshino K, Kiyohara Y, Kadono T, Murata Y, et al. A proposal for a TNM staging system for extramammary Paget disease: retrospective analysis of 301 patients with invasive primary tumors. *J Dermatol Sci*.2016;83(3):234-239. doi: 10.1016/j.jdermsci.2016.06.004.
- Mitropoulos D, Artibani W, Biyani CS, Bjerggaard Jensen J, Roupret M, Truss M. Validation of the Clavien-Dindo grading system in urology by the European Association of Urology Guidelines Ad Hoc Panel. *Eur Urol Focus*.2018;4(4):608-613.
- Hegarty PK, Suh J, Fisher MB, Taylor J, Nguyen TH, Ivan D, Prieto VG, et al. Penoscrotal extramammary Paget's disease: the University of Texas M. D. Anderson Cancer Center contemporary experience. *J Urol*.2011;186(1):97-102. doi: 10.1016/j.juro.2011.02.2685
- Leong JY, Chung PH. A primer on extramammary Paget's disease for the urologist. *Transl Androl Urol*.2020;9(1):93-105.
- Yang WJ, Kim DS, Im YJ, Cho KS, Rha KH, Cho NH, et al. Extramammary Paget's disease of penis and scrotum. *Urology*.2005;65(5):972-975. doi: 10.1016/j.urology.2004.12.010
- Misas JE, Cold CJ, Hall FW. Vulvar Paget disease: fluorescein-aided visualization of margins. *Obstet Gynecol*.1991;77(1):156-159.
- Fanning J, Lambert HC, Hale TM, Morris PC, Schuerch C. Paget's disease of the vulva: prevalence of associated vulvar adenocarcinoma, invasive Paget's disease, and recurrence after surgical excision. *Am J Obstet Gynecol*.1999;180(1 Pt 1):24-27.
- Marchesa P, Fazio VW, Oliari S, Goldblum JR, Lavery IC, Milsom JW. Long-term outcome of patients with perianal Paget's disease. *Ann Surg Oncol*.1997;4(6):475-480.
- Sarmiento JM, Wolff BG, Burgart LJ, Frizelle FA, Ilstrup DM. Paget's disease of the perianal region--an aggressive disease? *Dis Colon Rectum*.1997;40(10):1187-1194.
- Yugueros P, Keeney GL, Bite U. Paget's disease of the groin: report of seven cases. *Plast Reconstr Surg*.1997;100(2):336-339.
- Zollo JD, Zeitouni NC. The Roswell Park Cancer Institute experience with extramammary Paget's disease. *Br J Dermatol*.2000;142(1):59-65.
- Yao H, Xie M, Fu S, Guo J, Peng Y, Cai Z, et al. Survival analysis of patients with invasive extramammary Paget disease: implications of anatomic sites. *BMC Cancer*.2018;18(1):403. doi: 10.1186/s12885-018-4257-1
- Herrel LA, Weiss AD, Goodman M, Johnson TV, Osunkoya AO, Delman KA, et al. Extramammary Paget's disease in males: survival outcomes in 495 patients. *Ann Surg Oncol*.2015;22(5):1625-1630. doi: 10.1245/s10434-014-4139-y