

# Technical success rate of uterine artery embolisation for treatment of uterine leiomyomas at the University of the Free State

**H F Potgieter**  
MB ChB

**C S de Vries**  
MMedRad (D)

**E Loggenberg**  
MMedRad (D)

Department of Diagnostic Radiology  
University of the Free State  
Bloemfontein

mean total fluoroscopy time was 16.8 minutes, ranging from 4.8 minutes to 47.3 minutes.

## Introduction

Uterine leiomyomas occur in 20 - 50% of women above the age of 40 years making it the most frequent tumour of the female genital tract.<sup>1,2</sup> Metromenorrhagia, acute bleeding, pelvic pain, heaviness and discomfort are amongst the symptoms caused by uterine leiomyomas.

Uterine artery embolisation has been reported to be a minimally invasive, safe and effective alternative to traditional uterine leiomyoma treatment. Traditional treatments include the less invasive medical hormonal therapy and the more invasive surgical options such as myomectomy and hysterectomy. Uterine artery embolisation improved the clinical symptoms of leiomyomas, reduced tumour and uterine size, and caused few complications in the follow-up period.<sup>3-11</sup>

Uterine artery embolisation was first used in the 1970s to treat post-

partum haemorrhage.<sup>12</sup> In a benchmark study done in 1995, Ravina *et al.*<sup>13</sup> proposed uterine artery embolisation as an alternative to surgery for treating uterine leiomyomas.

Results published in 1999 were very promising. A 30 - 60% reduction in uterine size, and patient satisfaction rates ranging from 80% to 90% regarding reduction in uterine bulk symptoms and menorrhagia were reported. An estimated 6 000 procedures were performed with minimal serious infective morbidity and only two reported deaths.<sup>14-16</sup>

## Patients and methods

From November 1998 to July 2001 (33 months), 67 uterine artery embolisations were performed at the Department of Diagnostic Radiology (UFS) by two invasive radiologists (Dr E Loggenberg and Dr C S de Vries). Women diagnosed with leiomyomas and referred for uterine artery embolisation by gynaecologists from the Department of Obstetrics and Gynaecology (UFS) were included in the treatment. Magnetic resonance imaging (MRI) was done before the angiography and at 3 and 6 months after the procedure.

The procedures were done on a Siemens Multistar Angiography unit (Siemens, Erlangen). All patients underwent angiographies under local anaesthesia. Routinely, puncture of the right femoral artery with introduction of a 4-French sheath was used. A 4-French renal double curve catheter with a 0.35 Terumo guide-wire was used to select the left uterine artery, which was then embolised with PVA-particles (150 - 550 micron). The catheter was then removed, flushed

## Abstract

The technical success rate of uterine artery embolisations at the Department of Diagnostic Radiology, University of the Free State (UFS) is reported. From November 1998 to July 2001, 67 women, aged 35 - 75 years, received uterine artery embolisation. The procedure was usually performed through a single 4-French sheath set which was introduced into the right femoral artery using a 4-French catheter and injecting PVC particles (150 - 550 micron). Embolisation was performed successfully in 85.5% of the women. The

and the right uterine artery selected with repetition of the embolisation. Embolisation was done until complete cessation of blood flow in the leiomyoma was achieved (Figs 1 - 4).

The patients then went back to the ward for overnight observation and were discharged the next day.

## Results

### Procedure

A total of 67 patients received uterine artery embolisation over the 33-month period and 5 patients were lost to follow-up.

In 55 patients only a right femoral artery puncture was needed. In 4 patients bilateral femoral artery punctures were needed as it was difficult to select the right uterine artery from the ipsilateral side. The left femoral artery approach alone was used in 2 patients as 1 patient had enlarged lymph nodes on the right and there was difficulty in palpating the right femoral pulse of the other. The transbrachial approach was used in 1 patient because of the acute angle of the internal iliac artery, the uterine arteries could not be selected. The radiologist (Dr E Loggenberg) performing the procedure found the transbrachial approach to be surprisingly easy.

Fluoroscopy time ranged from 4.8 to 47.3 minutes, with a mean of 16.8 minutes. Pulse fluoroscopy (15 pulses per second) was used to minimise radiation.

In all 67 patients the procedure was performed with a 4-French catheter and 0.35 Terumo guidewire. Only 8 patients required an additional 4-French catheter and in 4 patients an additional guidewire was used.

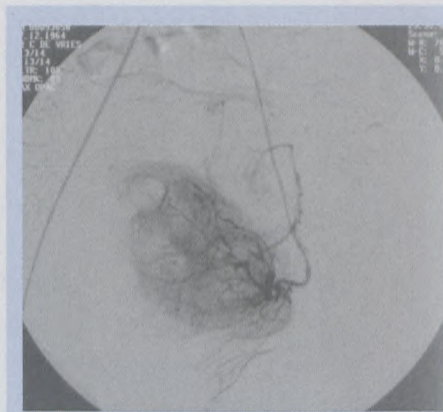


Fig. 1. Selection of left uterine artery showing the blush of the fibroid and uterus.

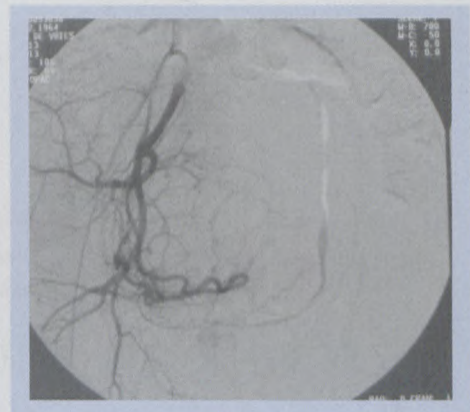


Fig. 4. Arteriogram after embolisation.

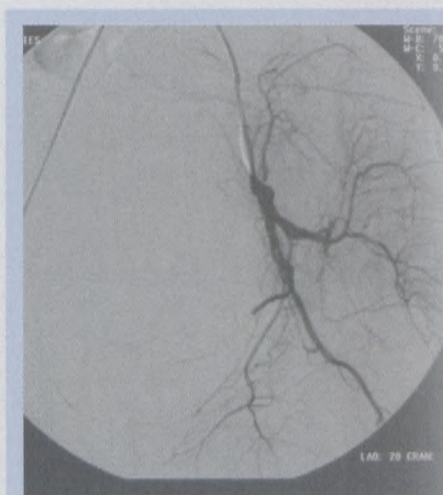


Fig. 2. Arteriogram after embolisation.

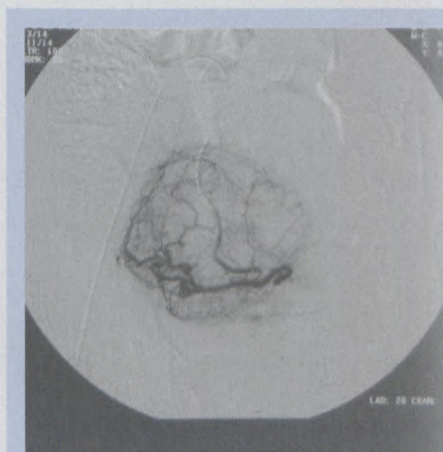


Fig. 3. Selection of right uterine artery showing the blush of the fibroid and uterus.

ine artery. One patient had unusually small uterine arteries and a microcatheter would have been helpful. The other patient was a 75-year-old woman with congestive heart failure, type 2 diabetes mellitus, hypertension, on warfarin therapy with dysfunctional uterine bleeding. Both her iliac arteries were very tortuous, she had a tight stenosis of the left internal iliac artery and plaques in the left uterine artery. When the right internal iliac artery was selected no right uterine artery could be demonstrated.

The left uterine artery of 1 patient could not be demonstrated by angiography and therefore the radiologist was unable to select it.

Inability to select the right uterine artery occurred in 6 patients. In a 47-year-old patient, the right internal iliac artery was tortuous; however, the case was completed successfully 2 days later via the transbrachial approach. Severe vasospasm occurred in 1 patient, and in another selection of the uterine artery was successfully done but no vessels supplying the leiomyoma could be identified. In 1 patient, the procedure failed because of the anatomical variation of where the superficial femoral artery originated from the right internal iliac artery, making the risk for embolisation to

### Analysis of outcome

In 2 patients it was impossible to select either the right or the left uter-

it **pays**  
to talk to the  
healthcare  
specialists



call **Corinth**, your  
fast track to the **UK**  
**0800 20 11 20**

E-mail [corinth@icon.co.za](mailto:corinth@icon.co.za)  
or [corinthdrs@icon.co.za](mailto:corinthdrs@icon.co.za)

**Radiographers**

**Audiologists**

**Biomedical Scientists Cardiographer**

**CSO/Cardiac Technicians**

**Dental Nurses Dieticians**

**Doctors/Specialists**

**Medical Admin and Clerical**

**Medical Laboratory Technicians**

**Medical Secretaries**

**Occupational Therapists**

**Phlebotomists Physiotherapists**

**Radiographers Social Workers**

**Speech and Language Therapists**

**Theatre Nurses**

M&D 7564

[www.corinthhealthcare.com](http://www.corinthhealthcare.com)

## ORIGINAL ARTICLE

the foot substantial. In the last 2 patients it was impossible to select the right internal iliac artery because of anatomical difficulties.

### Conclusion

Successful embolisation of the uterine arteries was performed in 85.5% of the patients. In 86.6% of the patients only a single 4-French catheter was used and in only 2 patients, a micro-catheter could have altered the outcome. The mean fluoroscopy time was 16.8 minutes.

An ordinary diagnostic 4-French catheter is sufficient for uterine artery embolisation in the majority of cases. Use of expensive micro-catheters, guidewires or glide-catheters should not routinely be necessary.

### References

1. Buttram VC, Reiter RC. Uterine leiomyomata: etiology, symptomatology, and management. *Fertil Steril* 1981; **36**: 433-445.
2. Verkauf BS. Myomectomy for infertility enhancement and preservation. *Fertil Steril* 1992; **58** (1): 1-15.
3. Ravina JH, Bouret JM, Ciraru-Vigueron N, *et al*. Recourse to particular arterial embolization in the treatment of some uterine leiomyoma. *Bull Acad Natl Med* 1997; **181**: 233-243.
4. Worthington-Kirsch RL, Popky GL, Hutchins FL Jr. Uterine arterial embolization for the management of leiomyomas: quality-of-life assessment and clinical response. *Radiology* 1998; **208**: 625-629.
5. Bradley EA, Reidy JF, Forman RG, Jarosz J, Braude PR. Transcatheter uterine artery embolisation to treat large uterine fibroids. *Br J Obstet Gynaecol* 1998; **105**: 235-240.
6. Goodwin SC, Mc Lucas B, Lee M, *et al*. Uterine artery embolization for the treatment of uterine leiomyomata midterm results. *J Vasc Interv Radiol* 1999; **10**: 1159-1165.
7. Spies JB, Scialli AR, Jha RC, *et al*. Initial results from uterine fibroid embolization for symptomatic leiomyomata. *J Vasc Interv Radiol* 1999; **10**: 1149-1157.
8. Hutchins FL Jr, Worthington-Kirsch RL, Berkowitz RP. Selective uterine artery embolization as primary treatment for symptomatic leiomyomata uteri. *J Am Assoc Gynecol Laparosc* 1999; **6**: 279-284.
9. Pelage JP, Le Dref O, Soyer P, *et al*. Fibroid-related menorrhagia: treatment with superselective embolization of the uterine arteries and midterm follow-up. *Radiology* 2000; **215**: 428-431.
10. Brunereau L, Herbretreau D, Gallas S, *et al*. Uterine artery embolization in the primary treatment of uterine leiomyomas: Technical features and prospective follow-up with clinical and sonographic examinations in 58 patients. *AJR* 2000; **175**: 1267-1272.
11. Siskin GP, Stainken BF, Dowling K, Meo P, Ahn J. Outpatient uterine artery embolization for symptomatic fibroids: experience in 49 patients. *J Vasc Interv Radiol* 2000; **11**: 305-311.
12. Heaston DK, Mineau DE, Brown BJ, Miller FJ Jr. Transcatheter arterial embolization for control of persistent massive puerperal hemorrhage after bilateral surgical hypogastric artery ligation. *AJR* 1979; **133**: 152-154.
13. Ravina JH, Herbretreau D, Cicaru-Vigueron N. Arterial embolization to treat uterine myomata. *Lancet* 1995; **346**: 671-672.
14. Vashist A, Studd J, Carey A, Burn P. Fatal septicaemia after fibroid embolization. *Lancet* 1999; **354**: 307-308.
15. Lanocita R, Frigerio LF, Patelli G, *et al*. A fatal complication of percutaneous transcatheter embolization for the treatment fibroids. In: proceedings of the Second International Symposium on Embolization of Uterine Myomata/Society for Minimally Invasive Therapy Eleventh International Conference; 16 - 18 September 1999, Boston, USA.
16. Walker W, Worthington-Kirsch RL. Fatal septicaemia after fibroid embolization. *Lancet* 1999; **354**: 1730.