

Linear diaphragmatic calcification in a two year-old child with tuberculosis

I Rachman

MB, FRCP

Principal Medical Officer, Brooklyn Chest Hospital, Cape Town

G Boss

MB, DCH

Retired Chest Physician, London

The incidental finding, on a chest x-ray, of dense, linear shadows lying above and parallel to one or both domes of the diaphragm, is widely regarded as pathognomonic of calcification due to previous exposure to asbestos.

Features of asbestos-related pleural thickening differ from the changes seen following tuberculosis pleurisy, even in the absence of symptomatic or radiographic underlying lung disease. In the former, bilateral, finger-like shadows project from the axillary margins of one or both lungs, often with bizarre, characteristically 'antler' shaped opacities lying more medially. These tend gradually to enlarge and calcify. Rarely, there is progression to invasive malignancy, mesothelioma; this may also present as a 'pleural effusion for diagnosis'.

In TB, unilateral sheets of diffuse, often hazy shadowing, may be seen, which becomes dense as calcification develops; the diaphragmatic pleura is traditionally spared.

We describe the case of a young child with x-ray changes typical of pleural asbestosis, in which the mineral could not be reasonably implicated.

Case report

JJ, born 21/7/74, was admitted to AJ Stals Hospital, Cape Town, on 14/6/76 with extensive pulmonary TB and paratracheal and hilar lymphadenopathy. The diagnosis was based on a Mantoux reaction greater than 10 mm, the presence of AFB in gastric washings, and the appearance of the chest x-ray, which showed extensive bilateral pulmonary consolidation, more on the left, and widening of the upper mediastinum (Figure 1). She

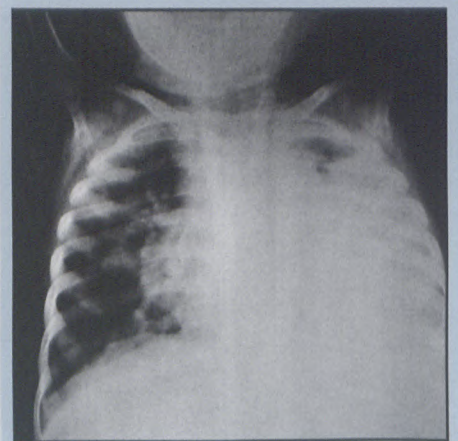



Figure 1: Admission chest radiograph demonstrating bilateral pulmonary consolidation more marked on the left, and mediastinal widening. No diaphragmatic calcification is seen.

was treated with streptomycin, isoniazid, rifampicin and pyrazinamide and made good progress until her discharge on 9/3/77. She had needed transfusing on admission, Hb 4.0g. An attack of chicken pox two months later did not halt her progress; in particular, no related lung involvement was evident.

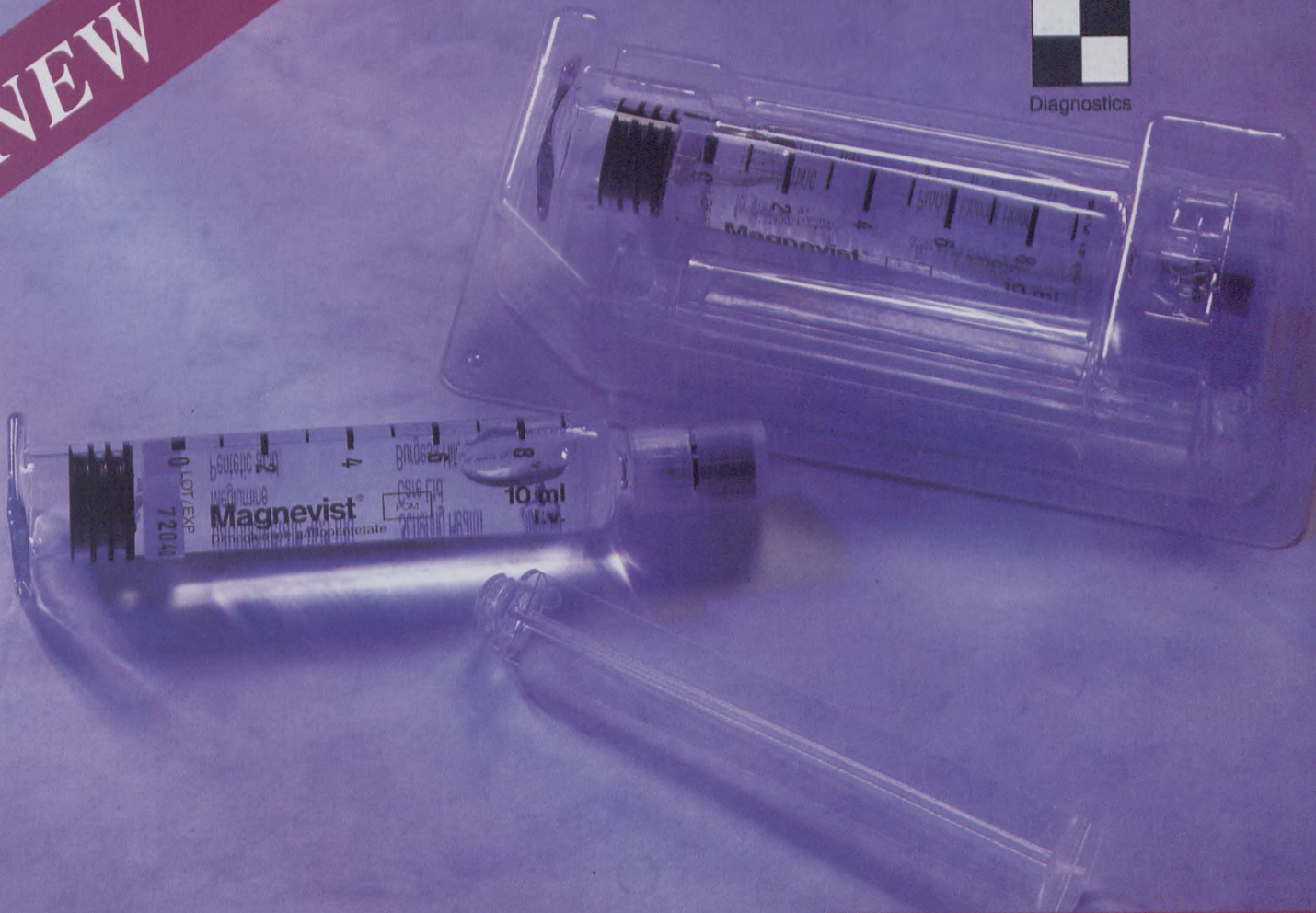
to page 6

NEW

SCHERING



Diagnostics



Magnevist[®] pre-filled syringes 10, 15 & 20 ml.

- **CONVENIENCE**

Schering understands that timing, accuracy and efficacy are of essence in MRI

- **SIMPLICITY**

Pre-filled syringes offer fast and easy application

- **EASE OF USE**

Injected volume instantly visible through reverse scaling

- Another innovative product in the Schering Diagnostics range.

Magnevist[®]
Enhancing MRI

Schering (Pty) Ltd (Reg. No. : 64/09072/07) 106 Sixteenth Road, Randjespark, Midrand 1685. P.O. Box 5278, Halfway House 1685. UIO 3198
Tel: (011) 313-9700. Fax: (011) 313-9793. e-mail: schering@icon.co.za

S1 Magnevist[®] 20 ml. 1 ml solution contains Gadopentetic acid, Dimeglumine salt 469,01 mg DTPA, Meglumine salt max. 1,02 mg. Reg. No.: W/28/199.

32851

Linear diaphragmatic calcification in a two year old child with tuberculosis

from page 4

A fleck of calcification on the right diaphragm can be seen two months after treatment was begun (Figure 2), and well marked bilateral linear calcific shadows at the time of discharge from hospital (Figure 3).

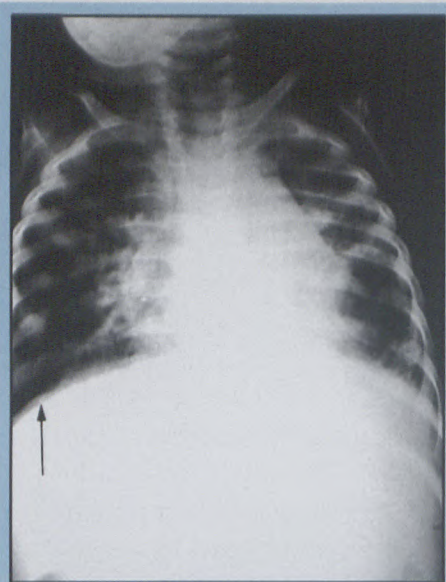


Figure 2: Chest radiograph two months after commencement of therapy demonstrating partial clearing of lung opacification and small fleck of calcification (arrow) on the right diaphragmatic pleura.

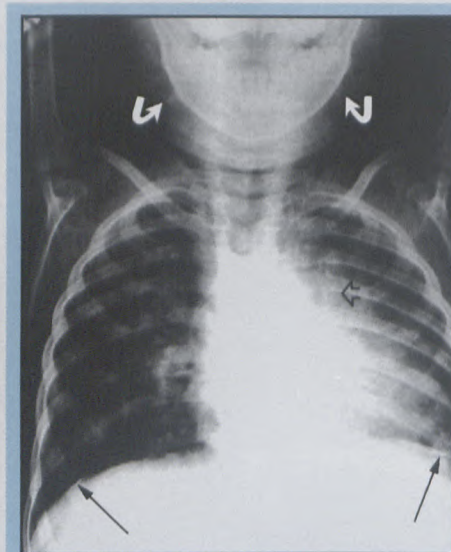


Figure 3: Note linear diaphragmatic pleural calcification (arrows) on chest radiograph 9 months after commencement of therapy. Also note calcified mediastinal (open arrow) and cervical (curved arrows) lymphadenopathy.

Discussion

The little girl came from Gordon's Bay, a coastal village near Cape Town. No evidence of exposure to asbestos could be obtained. Contact with the mineral would, in any case, be most unlikely to cause this x-ray appearance in so young a patient.

Simon¹ cites tuberculosis rheumatoid pleurisy and haemothorax following trauma, as well as asbestos exposure, as possible causes of linear diaphragmatic calcification.

The reason for the rarity of diaphragmatic pleurisy leading to calcification in the relatively common diseases cited by Simon is not clear. A subpleural inflammatory effusion could conceivably be affected by reduced or altered movement of the diaphragm, leading to a more rapid resolution, with fewer sequelae. On the other hand, the ability of the asbestos fibres to penetrate the pleura causing an asymptomatic inflammatory reaction leading finally to calcification, could presumably be related to the extreme chronicity of the process, said to be not less than about 20 years and often much longer.

Perhaps we should revise our interpretation of linear diaphragmatic calcification seen on the chest x-ray.

Reference

1. Simon G. Chest x-ray diagnosis. 3rd ed, 1971, p109.

COMPANY NEWS

SCHERING

Pre-filled syringes for MRI

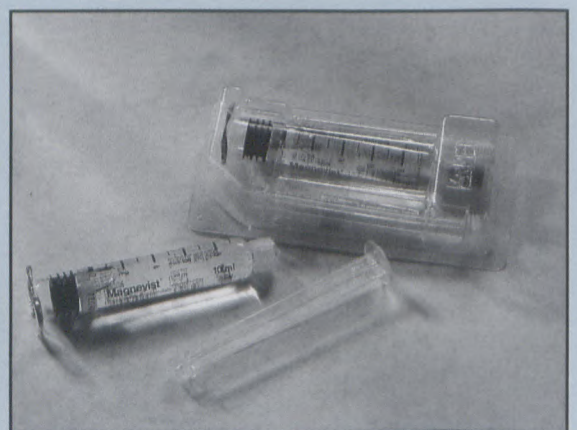
MAGNEVIST® WAS the first paramagnetic MRI contrast agent for intravenous injection. Since its introduction, radiologists all over the world have made it the most widely used and extensively documented contrast agent for MRI, according to a spokesperson for Schering (Pty) Ltd.

To complement the existing range of Magnevist® vials and Magnevist

enteral®, the company has introduced Magnevist® in pre-filled syringes.

Launched on April 1st, Magnevist pre-filled syringes present a new era in MRI convenience. The syringes are available in ready-to-use 10, 15, and 20 ml sizes, and the injection volume is instantly visible through reverse scaling.

The syringes are competitively priced and available in pre-packed boxes of 5 syringes.



The Magnevist® pre-filled syringes from Schering

Information from Schering (Pty) Ltd, tel (011) 313-9700.