

Mediastinal Assessment in Traumatic Rupture of the Aorta

Abstract

The precise method for measuring mediastinal widening in thoracic trauma is poorly understood and too much emphasis is placed on it as the sole criterion for performing aortography. This review article describes the established methods of measurement and their limitations, and also discusses the importance of other signs pointing to aortic rupture such as blurring of the aortic knuckle and a subjective impression of mediastinal abnormality which are more helpful in determining the need for angiography.

CM Young

MBBS(Lond) FRCS(Ed)
FFRad(D)(SA)

Department of Radiology,
Grote Schuur Hospital and
University of Cape Town

Introduction

The commonest site of aortic injury is at the isthmus i.e. between the left subclavian artery origin and the ligamentum arteriosum and is thought to be due to deceleration affecting fixed and relatively mobile segments of the organ. Rupture causes immediate death in up to 90% of trauma victims. A small number of severely

injured patients however may be in the fortunate position of having an increased chance of survival owing to the development of rapid evacuation transportation and regional trauma centres. Those who reach hospital have a contained rupture i.e. a localized false aneurysm. This feature is often not recognized on a chest radiograph as a much wider area of haematoma obscures it¹. Mediastinal widening in these cases is caused by bleeding from associated injuries to minor arteries and veins; nevertheless the association has been shown to be useful as originally described by Marsh and Sturm.² If the mediastinal haematoma had been caused by blood from the aortic rupture, then the patient would almost certainly have exsanguinated.

The natural history of these false aneurysms is poorly understood. Clinical management and also the modern radiological literature is still largely based on Parmley's 1958 post-mortem study of mortality data³ as quoted in Pais' excellent *Seminars* review on angiography in the trauma patient.⁴ Pais states that in Parmley's paper there was no angiographic correlation and therefore patients with aortic false aneurysm who had survived were not taken into consideration. A recent review on the subject in *Clinical Radiology* by White and Mirvis from Baltimore⁵ states that 40% of untreated patients die within 24 hours of hospital admission. Although the evidence for this is not given, the percentage figure corresponds exactly with Parmley's data. Several other contemporary authors suggest that the immediate natural history may be more benign than suggested^{4,6,7} and this has also been our experience.⁸ Cowley found that there was no statistical association between mortality and either transport time to the hospital or time from injury to operation.⁶ Richardson found that no patient with ruptured aorta or aortic branch injury reaching hospital died from that injury before its operative treatment, bearing in mind that other

to page 9

Mediastinal Assessment in Traumatic Rupture of the Aorta

life-threatening injuries in these patients required operation first.⁷

Standard methods of mediastinal measurement

It is common practice in our institution (both by radiologists and trauma surgeons) to assess mediastinal width on chest X-ray post thoracic trauma, using 8 cm as a criterion for aortography. This measurement was described by Marsh and Sturm, radiologist and surgeon respectively in their landmark article in the *Annals of Thoracic Surgery*.² They compared 47 severely injured patients with 100 controls using a 100 cm antero-posterior (AP) supine chest film. Five cases of aortic rupture were found in patients with a widened mediastinum, and they concluded that a mediastinal measurement more than 8 cm was a definite indication for aortography. The slightly misleading phrase "at the level of the aortic knob" was used in the text, although their diagram clearly shows the measurement was made immediately above the aortic knuckle, the position recommended by Milne *et al* in their description of the "vascular pedicle".⁹

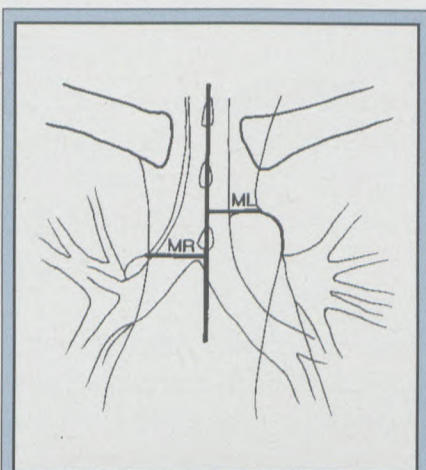


Figure 1: Diagram of mediastinal structures seen on a supine chest radiograph to show method of transverse width measurement (ML+MR) (see text).

Transverse mediastinal width (the "vascular pedicle")

The distance from the midline (spinous process) to the left border of the left subclavian artery take-off (ML) is added to the distance from the midline to the intersection of the right border of the superior vena cava (SVC) and right main bronchus (MR) (See Figure 1).

Milne *et al* give an elegant explanation of the nature of the vascular pedicle in a series of three articles describing the normal subject, the patient with acquired heart disease and also the traumatised patient.^{9,10,11} They point out that when the patient assumes the supine position, the pedicle width increases to a different extent on each side. The subclavian artery, forming the left side of the superior mediastinum, has a low compliance hence will change little in diameter. The venous structures making up the right border, superiorly the right brachiocephalic vein and inferiorly the SVC, will change markedly in size between the erect and supine postures. It is important to note that the clarity of the right paratracheal stripe and the azygos vein is preserved. Milne *et al* also observed that increased mediastinal width occurs in fluid overload or cardiac decompensation, and this is also related to venous distension. When the vascular pedicle width is increased because of extravascular fluid (as in aortic rupture), then the enlargement occurs principally on the left as the subclavian artery is posteriorly situated and haematoma related to the rupture surrounds it. The clarity of the right side of the superior mediastinum, formed by the SVC, is preserved as it is more anterior and hence remote from the haematoma. Note on the diagram how the right paratracheal stripe and azygos may be effaced and the paraspinal lines displaced (See Figure 2).

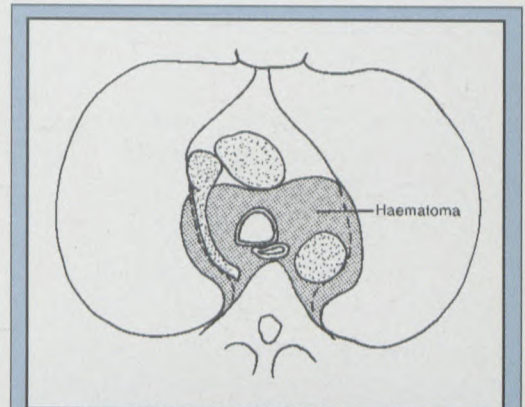


Figure 2: Diagram of mediastinal CT scan showing azygos vein entering SVC, and effacement of the vein and the right paratracheal stripe by haematoma. Note how a haematoma that extends into the superior mediastinum would expand to left around the left subclavian artery, preserving the outline of the right border of SVC, a more anterior structure (see text).

It is important to bear in mind that a focal mediastinal widening above the point of measurement of the vascular pedicle can be an indication of major vascular injury and is therefore an indication for aortography.

Technical aspects

The focus-film distance (FFD) of the radiograph is of little consequence. A lordotic projection as is often obtained in the semi-erect ICU patient may magnify the superior mediastinal structures with loss of definition of the aortic arch and hence may lead to unnecessary angiography.¹²

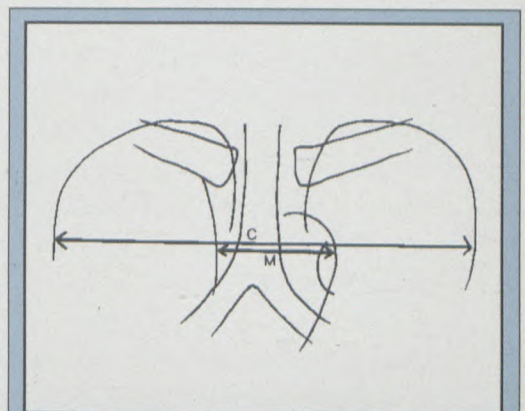


Figure 3: Diagram of chest radiograph to show determination of mediastinal width to chest width ratio (M/C ratio) (see text).

Mediastinal width to chest width ratio (M/C ratio)

Seltzer *et al* described the use of the M/C ratio in the assessment of traumatic aortic rupture in the AJR in 1981.¹³ The greatest width of the mediastinum is taken at the level of the aortic arch i.e. it includes the aortic knuckle and SVC (M) (See Figure 3). It is divided by the internal thoracic diameter from inner rib margin to inner rib margin (C) at the same level. The authors recommended that the maximum M/C ratio be taken as 0.25 and this would identify 95% of cases with aortic rupture and give a false positive rate of 25%. Their study also found little relation between rib fracture and aortic tear.

Technical aspects

Seltzer *et al* found no statistical difference in M/C ratios comparing supine or sitting AP radiographs and postero-anterior (PA) erect films, although the overall trend was that supine AP films had the largest ratios. There is no significant change in M/C ratio with increase or decrease of FFD.¹

Discussion

Woodring and King discuss the limitations of transverse mediastinal width (TMW) and M/C ratio in an important paper.¹ The overall object of their study was to examine the usefulness of precise measurements as against subjective assessment of mediastinal abnormality. They concluded as a result of their own study that excessive mediastinal widening was helpful in determining the need for aortography, but that a normal measurement was not. There was such an extreme overlap of values of mediastinal width and M/C ratio between normals and abnormal, that precise measurement could not reliably separate the two groups. They observed that using an M/C ratio of 0.25 or greater to define abnormality as recommended by Seltzer *et al*¹³ would lead to a false positive rate as high as 99%.

The main reason for this is that mediastinal width includes the aortic arch (as used in M/C ratio) and is related to normal unfolding of the aorta that occurs with age. There is only a modest correlation between increasing patient age and widening of the vascular pedicle.¹ In Woodring and King's experience there were a number of cases of ruptured aorta or brachiocephalic arteries that had a superior mediastinal width of less than 8 cm, the criterion for aortography quoted by Marsh and Sturm.² They suggested modifying the values of transverse mediastinal width and M/C

Table 1: Radiographic associations of aortic rupture

Mediastinal widening
Abnormality of aortic knuckle or descending aorta
Left apical pleural cap
Displacement of trachea to the right
Displacement of naso-gastric tube to the right
Inferior displacement of left main bronchus
Filling-in of aortopulmonary window
Widening of right paratracheal stripe
Effacement of vena azygos
Left haemothorax
R or L paraspinal line displacement
Pulmonary contusions
Rib fractures (no association found by Seltzer <i>et al</i>)

ratio to 7.5 cm and 0.38 respectively to give a more acceptable false positive rate than Marsh and Sturm's 8 cm, and Seltzer *et al*'s M/C ratio of 0.25 would have given. Patients with values above these levels would have aortograms, but would also have angiography performed **below** these levels, in the presence of other signs of mediastinal abnormality (e.g. blurring of aortic arch or aorto-pulmonary window etc). Forty-one per cent of patients with proven arterial injury in their series and using their criteria had TMW within normal limits, and 69% had a normal M/C ratio.

It has been suggested that an erect chest film be done if possible.^{5,14} This may provide optimal assessment of the aortomediastinal contour compared with the supine view, but it is important to be aware that the mediastinal measurements as described in the literature are **designed for the supine view**.

Angiography vs CT

Intra-arterial digital subtraction angiography (IA DSA) is recommended as the procedure of choice by Mirvis *et al*.¹⁵ It has the same accuracy as conventional arteriography with a considerable saving in time and film cost. At Groote Schuur Hospital we perform two views using IA DSA, frontal (postero-anterior) and left anterior oblique, similar to Mirvis *et al*'s technique.

We prefer angiography to computed tomography (CT) in our institution for several reasons: CT is prone to misregistration artefacts, and can be difficult to interpret, although these problems may be overcome with the advent of spiral CT; the patients are often unco-operative leading to major motion image degradation; and our thoracic surgeons request angiography to precisely define the abnormality. If CT was performed first some patients would then require two investigations both with a large contrast load, i.e. a patient whose CT showed a mediastinal haematoma would then go on to angiography. We consider that an arch aortogram is a minimally invasive, quick and relatively easy procedure to perform and to interpret, bearing in mind the usual pitfalls caused by the ductus which are beyond the scope of this article.

The necessity for angiography in patients with a normal chest radiograph

Savastano *et al* state that angiography is not necessary in patients with blunt chest trauma whose chest radiographs show no

Mediastinal Assessment in Traumatic Rupture of the Aorta

signs of left haemomediastinum.¹⁶ White and Mirvis state that a normal radiograph excludes traumatic aortic rupture (TAI) unless there is a compelling clinical reason to suspect the diagnosis, and usually obviates further studies.⁴ They were unaware of any chest film falsely negative for TAI in their institution. Woodring and King however did have two cases with small false aneurysms of the isthmic region with normal radiographs, and four cases with no mediastinal haemorrhage but large false aneurysms visible on the film.¹ They concluded that chest radiography has limitations in detecting vascular injury but

Table II: Learning points

1. Mediastinal measurements are made on a **supine** film
2. Transverse mediastinal width (TMW) is measured **above** the aortic knuckle
3. Maximum TMW can usefully be modified to 7.5 cm
4. M/C ratio is of little value
5. Mediastinal measurements within normal limits **do not** exclude major vascular injury
6. Pay close attention to mediastinal abnormalities, ask advice of a senior colleague if unsure
7. It is acceptable to have a low threshold for performing aortography when there are mediastinal abnormalities
8. A large number of false positives suggesting aortic rupture are to be expected on chest radiography
9. Angiography is not necessary in patients with a normal chest radiograph
10. If aortic rupture is suspected perform aortography not CT

nevertheless have adopted a policy of performing aortography based on specific mediastinal abnormalities and no longer perform precise measurements of TMW and M/C ratio.

It seems reasonable therefore to accept that a normal chest radiograph precludes the need for aortography, but it is important to be aware that mediastinal widening may progress whilst the patient is in hospital. We have observed this phenomenon on occasion at our institution.

Timing of angiography

Does the aortogram have to be performed immediately, or can there be a delay? This is an ethical problem even though current evidence points to a benign immediate course of aortic false aneurysms. These data have been gathered retrospectively, and as stated above more critically ill patients who formerly would have died may present to trauma units, i.e. the potential for early rupture of a false aneurysm still exists. I consider that urgent angiography should still be done, for although the potential for early rupture is small, the consequences of missing such an injury are catastrophic.

The plain radiographic features that suggest or are associated with aortic rupture are well known, and I shall not elaborate on them further. (See Table I). Note the learning points as described in Table II.

Acknowledgement

I am most grateful to Dr Hillel Goodman for his helpful comments.

References

1. Woodring JH, and King JG. Determination of Normal Transverse Mediastinal Width and Mediastinal-width to Chest-width (M/C) Ratio in Control Subjects: Implications for Subjects with Aortic or Brachiocephalic Arterial Injury. *The Journal of Trauma* 1989;29:No 9:1268-1272.
2. Marsh DG and Sturm JT. Traumatic Aortic Rupture: Roentgenographic Indications of Angiography. *The Annals of Thoracic Surgery* April 1976;21:No 4:337-340.
3. Parmley LF, Mattingley TW, Manion WC et al. Nonpenetrating traumatic injury of the aorta. *Circulation* 1958;17:1086-1101.
4. Pais SO. Diagnostic and Therapeutic Angiography in the Trauma Patient. *Seminars in Roentgenology* July 1992;XXVII:No 3:211-232.
5. White CS and Mirvis SE. Pictorial Review: Imaging of Traumatic Aortic Injury. *Clinical Radiology* 1995;50:281-287.
6. Cowley RA, Turney SZ, Hankins FR et al. Rupture of thoracic aorta caused by blunt trauma: A fifteen year experience. *J Thorac Cardiovasc Surg* 1990;100:652-661.
7. Richardson JD, Wilson ME, Miller FB. The widened mediastinum. Diagnostic and therapeutic priorities. *Ann Surg* 1990;211:731-736.
8. Von Opper UO, Thierfelder CF, Beningfield SJ et al. Traumatic rupture of the descending thoracic aorta. *SAMJ* 18 May 1991;79:595-598.

9. Milne ENC, Pistoletti M, Minati M et al. The vascular pedicle of the heart and the vena azygos. Part I: The normal subject. *Radiology* 1984;152:1-8.

10. Pistoletti M, Milne ENC, Minati M et al. The vascular pedicle of the heart and the vena azygos. Part II: Acquired heart disease. *Radiology* 1984;152:9-17.

11. Milne ENC, Imray TJ, Pistoletti M et al. The vascular pedicle and the vena azygos. Part III: In trauma-The "vanishing" azygos. *Radiology* 1984;153:25-31.

12. Hollman AS, Adams FG. The Influence of the Lordotic Projection on the Interpretation of the Chest Radiograph. *Clinical Radiology* 1989;40:360-364.

13. Seltzer SE, D'Orsi C, Kirshner R et al. Traumatic Aortic Rupture: Plain Radiographic Findings. *AJR* November 1981;137:1011-1014.

14. Mirvis SE, Bidwell JK, Buddemeyer EU et al. Value of Chest Radiography in Excluding Traumatic Aortic Rupture. *Radiology* 1987;163:487-493.

15. Mirvis SE, Pais SO, Gens DR. Thoracic Aortic Rupture: Advantages of Intra-arterial Digital Subtraction Angiography. *AJR* May 1986;146:987-991.

16. Savastano S, Felton GP, Miotto D et al. Value of Plain Chest Film in Predicting Traumatic Aortic Rupture. *Ann Radiol* 1989;32:196-200.