

# Laparoscopic deroofing of hepatic cyst

\*Al Kindy N M, Grant C S, Daar A S

## أزالة سقف كيس كبدي بواسطة المنظار

نائل الكندي، كريستوفر غرانت، عبدالله داعر

**المخلص:** عادة ما تكون الأكياس الكبدية اللاطفيلية المعزولة بدون أعراض جانبية ولا تحتاج الى علاج ونادرا ما تؤدي هذه الأكياس الى أعراض وعندها يفضل أستئصالها جراحيا. وأفضل علاج جراحي لهذه الأكياس المسببة للأعراض لايزال موضع جدل. نعرض حالة عالجتها بالمنظار بإزالة سقف الكيس وهذه الطريقة جدليا سليمة ومؤثرة.

**ABSTRACT:** Solitary non-parasitic cysts of the liver are commonly asymptomatic and do not require treatment. Rarely, the cysts become symptomatic and are then best treated surgically. The optimal surgical treatment is debatable. We report a case treated by laparoscopic deroofing which is arguably a safe and effective approach.

**KEY WORDS:** solitary non-parasitic liver cysts; laparoscopic deroofing

**M**ost non-parasitic solitary liver cysts are asymptomatic and need no treatment. Symptoms result from either an increase in the size of the cyst or the development of complications.<sup>1</sup> Symptomatic or large solitary non-parasitic hepatic cysts are best treated surgically, though this in the past meant open surgery with its attendant morbidity and long hospital stay. The minimally invasive laparoscopic approach is of late being reported to be a safe and effective alternative.<sup>2-5</sup> We report the case of a symptomatic large solitary non-parasitic hepatic cyst treated by laparoscopic deroofing of the external part of the cyst wall.

### PATIENT AND METHOD

A 46-year-old Omani woman presented with an 8-month history of progressive right hypochondrial pain. The liver edge was palpable 10 cm below the costal margin. Abdominal ultrasound and CT scan showed a large, solitary smooth-walled unilocular cyst, 17 cm in diameter, located in the right lobe of the liver (Figure 1). The cyst had been aspirated once in another local hospital 6 months prior to her presentation, and cytology of the fluid had been reported as negative. Serological tests for hydatid liver disease were negative and an upper gastrointestinal endoscopy was normal.

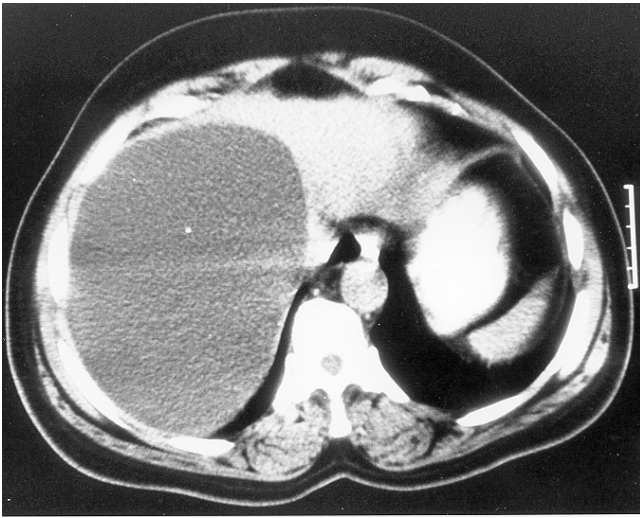
Under general anaesthesia and carbon dioxide pneumoperitoneum, a 30-degree laparoscope was introduced through a 10-mm cannula inserted through a subumbilical incision. The cyst was clearly seen. A second 10-mm cannula was inserted in the epigastrium to the right of the midline and a further 5-mm cannula was inserted in the

right subcostal region just lateral to the midclavicular line. Laparoscopy-guided percutaneous needle aspiration was carried out to decompress the cyst and to avoid leakage of the cystic fluid into the abdominal cavity. A total of 1,200 ml of clear serous fluid was aspirated. Urgent cytology of the cystic fluid showed no malignant cells or scolices. The cyst wall was next widely deroofed using diathermy scissors and hook, excising all of the non-parenchymal cyst wall. Bleeding from the cut edge was minimal and easily controlled with diathermy. The excised cyst wall (6.5 x 9 cm) was then removed through the epigastric port. A small suction drain was inserted through the right subcostal 5-mm cannula, and placed within the cavity of the cyst, after which the pneumoperitoneum was deflated. The instruments were then removed and the wounds closed. Total operating time was 90 minutes. The patient's recovery was rapid and uneventful; the drain was removed on the second postoperative day, and the patient discharged home on the third postoperative day. Twelve months after the operation, she remains asymptomatic with no recurrence. Histology of the cyst wall showed only a dense fibrovascular tissue, lined with cuboidal cells, confirming the benign nature.

### DISCUSSION

Non-parasitic solitary hepatic cysts are considered to be retention cysts, which result from inflammatory hyperplasia and obstruction of congenital aberrant bile ducts.<sup>1</sup> Most are small and remain asymptomatic, though a few cysts occasionally increase in size and eventually cause symptoms. In the absence of complications, symptoms

from solitary non-parasitic liver cysts are almost always the result of a space-occupying effect of the cyst either on the liver itself or on adjacent viscera.<sup>1</sup>



**FIGURE 1.** *Computed tomographic scan showing a large 17 cm diameter solitary unilocular cyst in the right lobe of the liver.*

Non-surgical treatment in the form of percutaneous ultrasound-guided aspiration of the cyst, followed by injection of a sclerosing agent, is associated with an unacceptably high recurrence rate.<sup>6</sup> Current surgical management relies on fenestration or deroofting of the cyst as described by Lin in 1968,<sup>7</sup> with or without placement of an omental flap into the residual cyst cavity to prevent the edges from co-apting. Recently, the laparoscopic approach to this technique has been shown to be feasible and safe.<sup>3-5</sup> Precise preoperative assessment of the location of the cyst with CT scans is necessary as cysts located posteriorly in segments VI and VII of the liver are difficult to approach laparoscopically.<sup>5</sup> Intra-operative localization of the cyst is also crucial as the laparoscopic approach can be limited by the lack of manual palpation. Superficial cysts are obvious or easily localized by aspiration at laparoscopy as in our case. Intra-operative ultrasound should be used to confirm the anatomy, especially where the cyst is not obvious on surface laparoscopy. Laparoscopic ultrasound provides accurate anatomical localization of lesions and identifies adjacent vascular pedicles.<sup>8</sup> The wide deroofting of superficial cysts can be

achieved by using diathermy which is satisfactory for both dissection and haemostasis<sup>3,4</sup> but the ultrasonic coagulating shears may be considered ideal because they provide excellent haemostasis in a relatively smoke-free environment.<sup>8</sup>

With careful selection of cases, laparoscopic deroofting of symptomatic solitary hepatic cysts is safe and effective, and offers all the advantages of minimally invasive surgery.<sup>9,10</sup> Patients with symptomatic polycystic liver disease characterised by a limited number of large cysts mainly located on the liver surface have also been reported to benefit from the laparoscopic technique.<sup>2,3</sup>

#### REFERENCES

1. **Jones WL, Mountain JC, Warren KW.** Symptomatic non-parasitic cysts of the liver. *Br J Surg* 1978, **61**, 118-23.
2. **Paterson-Brown S, Garden OJ.** Laser-assisted laparoscopic excision of liver cyst. *Br J Surg* 1991, **78**, 1047.
3. **Morino M, DeGiuli M, Festa V, Garrone C.** Laparoscopic management of symptomatic non-parasitic cysts of the liver. *Ann Surg* 1994, **219**, 157-64.
4. **Ker CG, Chen JS, Lee KT, Sheen PC.** Laparoscopic fenestration for a giant liver cyst. *Endoscopy* 1994, **26**, 754.
5. **Krahenbuhl L, Baer HU, Renzulli P, Zgraggen K, Frei E, Buchler MW.** Laparoscopic management of nonparasitic symptom-producing solitary hepatic cysts. *J Am Coll Surg* 1996, **183**, 493-8.
6. **Saini S, Mueller PR, Ferrucci JT Jr, Simeone JF, Wittenberg J, Butch RJ.** Percutaneous aspiration of hepatic cysts does not provide definitive therapy. *Am J Roentgenol* 1983, **141**, 559-60.
7. **Lin TY, Chen CC, Wang SM.** Treatment of non-parasitic cystic disease of the liver: a new approach to therapy with polycystic liver. *Ann Surg* 1968, 921-7.
8. **Martin I, Garden OJ.** Laparoscopic radical deroofting of hepatic cysts using the ultrasonic scalpel. *Aust NZ J Surg* 1999, **69**, 743-4.
9. **Klinger PJ, Gadenstatter M, Schmid T, Bodner E, Schwelberger HG.** Treatment of hepatic cysts in the era of laparoscopic surgery. *Br J Surg* 1997, **84**, 438-44.
10. **Martin IJ, McKinley AJ, Currie EJ, Holmes PH, Garden OJ.** Tailoring the management of non-parasitic liver cysts. *Ann Surg* 1998, **228**, 167-72.