

Newly Diagnosed Acute Myeloid Leukemia with Neck Swelling

*Maha Al-Yahyai, Sulayma Al-Lamki, Muhanna Al-Musalhi

ايضاض نخاعي حاد حديث التشخيص مع تورم في الرقبة

مها اليحيائي، سُلَيْمَى اللَمَكِي، مُهَنَّا المصلحي

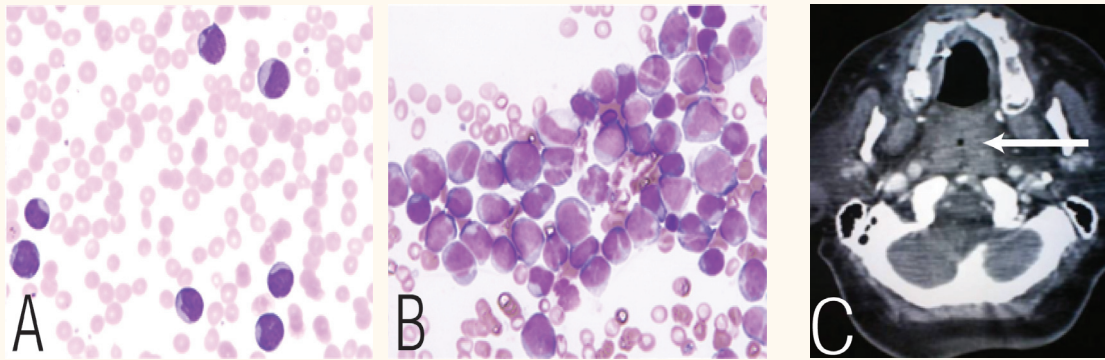


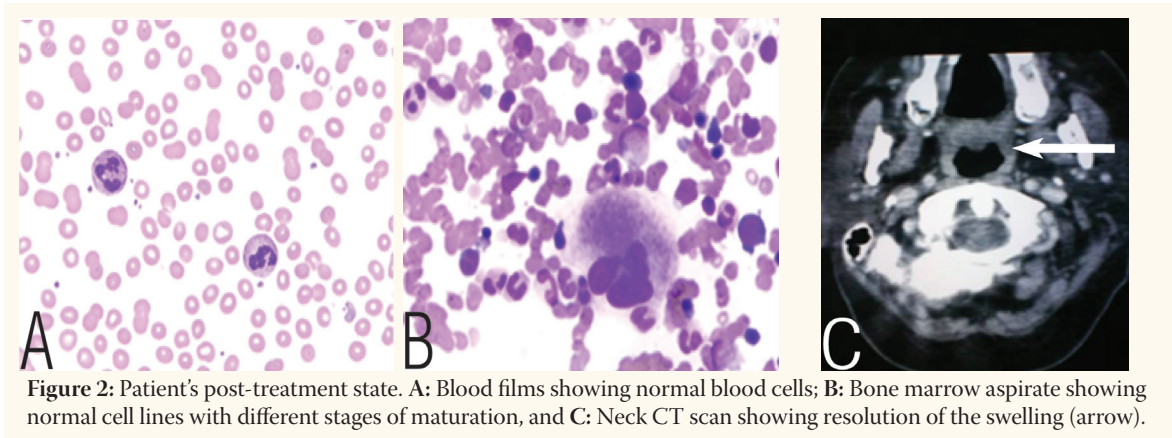
Figure 1: Results of tests showing patient in leukaemic state. **A:** Blood film showing circulating blasts; **B:** Bone marrow aspirate showing loss of normal cells and infiltration of the marrow by blasts, and **C:** Computed tomography scan of neck showing the swelling (arrow), nearly occluding the nasopharyngeal region.

A 62 YEAR-OLD WOMAN, DIAGNOSED WITH and on treatment for hypertension, was referred to the Haematology Department at the Royal Hospital, Oman, with an accidental finding of increased white blood cells (WBC) in her full blood count, a total of $76 \times 10^9/L$. There was history of giddiness, fever and easy fatigability prior to presentation.

A repeat blood work-up showed a haemoglobin level of 10.8 g/dl, with normal mean corpuscular volume (MCV) and mean corpuscular haemoglobin (MCH), a platelet count of $55 \times 10^9/L$ and a WBC count of $103 \times 10^9/L$. All other blood investigations including renal function tests, liver function tests and bone profile, were normal. Viral studies, blood and urine cultures were negative. The blood film showed >90% large sized blasts with abundant cytoplasm and prominent nucleoli [Figure 1A]. The bone marrow aspirate (BMA) [Figure 1B] and flow cytometry findings

were consistent with acute myeloid leukaemia (AML-M1) according to the French-American-British [FAB] classification. Later, cytogenetic investigation revealed a positive FLT-3 mutation. On the second day of admission, she was found to have a neck swelling and developed shortness of breath. An emergency neck computed tomography (CT) scan was done [Figure 1C] which showed a soft tissue thickening (mass) of the nasopharynx and oropharynx encroaching on the airway and almost occluding it. The patient was started on standard induction chemotherapy, (cytarabine once daily for seven days and daunorubicin twice daily for three days intravenously), as well as prophylaxis with antiviral and antifungal medications.

The patient remained stable and afebrile. She was discharged 22 days after the induction of chemotherapy with a haemoglobin level of 9.6 g/dl and platelet count of $44 \times 10^9/L$. A week later she was seen in the day care unit, had a



repeat blood film and BMA done which was consistent with morphologic remission [Figure 2 A & B]. A repeat neck CT scan showed that the previously noted soft tissue thickening in the nasopharynx and oropharynx had disappeared as well [Figure 2C]. A biopsy of the mass was not done earlier due to the location and the high risk of bleeding in this case. However, it disappeared after treatment and this would indicate that it was a leukaemic tissue mass. She received two consolidation chemotherapies followed by allogenic bone marrow transplantation. However, she relapsed after three months and died.

The main presentations in patients with AML include peripheral blood and bone marrow involvement. Extramedullary presentations, such as head and neck swellings, have been reported. In our literature search, we found only a few cases with some resemblance to ours. De Fonseca reported a child with a neck swelling who sought medical attention from a dentist where no odontogenic problem was found; however, he was subsequently diagnosed to have AML.¹ Hayashida *et al.* described a nasopharyngeal mass in a patient diagnosed with acute monocytic leukemia.² Udayakumar and Sundareshan reported a girl with neck swelling who was diagnosed with AML-M6.³ Amin *et al.* mentioned that AML subtypes M4 and M5 have a higher incidence of oral infiltrations and reported one case of AML-M0 which presented with palatal swelling.⁴ An AML case, occurring in the tonsillar fossa as an ulcerating lesion with a neck mass, has also been described.⁵ A patient who achieved remission following the diagnosis of an AML-M0, presented with a mass in the left retropharyngeal and perivertebral regions, a mass in the left vallecula, and a mass infiltrating the right

preepiglottic tissue. He was later diagnosed to have granulocytic sarcoma.⁶ Finally, another study was conducted to summarise the clinical and radiologic presentations including pertinent imaging features of granulocytic sarcoma. The lesions were mainly found in the central nervous system, subcutaneous tissues, and genitourinary system.⁷ No articles were found in the literature mentioning an AML-M1 case with neck swelling or nasopharynx involvement.

References

1. da Fonseca MA. Head and neck extramedullary disease as the initial presentation of acute myelogenous leukemia in a child. *J Dent Child (Chic)* 2007; 74:241–4.
2. Hayashida T, Araki Y, Kawano K, Kamata T, Kawai Y, Takeuchi K, et al. Extramedullary diseases as presenting features of a leukemic acute monocytic leukemia. *Rinsho Ketsueki* 1992; 33:1679–84.
3. Udayakumar AM, Sundareshan TS. Tetrasomy 21 as a sole abnormality in erythroleukemia. *Cancer Genet Cytogenet* 1995; 85:85–7.
4. Amin KS, Ehsan A, McGuff HS, Albright SC. Minimally differentiated acute myelogenous leukemia (AML-M0) granulocytic sarcoma presenting in the oral cavity. *Oral Oncol* 2002; 38:516–19.
5. Zapf B, Carpenter RJ 3rd, Snyder GG 3rd. Ulcerating tumor of tonsil and neck mass as occurrence of acute myelocytic leukemia. *Otolaryngol Head Neck Surg* 1981; 89:560–3.
6. Ozcelik T, Ali R, Ozkalemkaş F, Ozkocaman V, Coşkun H, Erişen L, et al. A case of granulocytic sarcoma during complete remission of acute myeloid leukemia with multiple masses involving the larynx and nasopharynx. *Kulak Burun Bogaz Ihtis Derg* 2003; 11:183–8.
7. Ooi GC, Chim CS, Khong PL, Au WY, Lie AK, Tsang KW, Kwong YL, et al. Radiologic manifestations of granulocytic sarcoma in adult leukaemia. *AJR Am J Roentgenol* 2001; 176:1427–31.