

# Cardiovoal Syndrome

## A rare cause of hoarseness in a patient with a history of pulmonary tuberculosis

\*Rakul Nambiar,<sup>1</sup> Dae Dalus,<sup>2</sup> Anjali Srikumar<sup>3</sup>

### المتلازمة القلبية-الصوتية

سبب نادر من أسباب بحة الصوت عند مريض له تاريخ مرضي بالسل الرئوي

راكول نامبيار، داي دالوس، أنجالي سريكمار

**ABSTRACT:** Hoarseness is a common clinical condition with underlying causes which can vary from reversible and benign to life-threatening and malignant. Cardiovoal syndrome may cause hoarseness secondary to left recurrent laryngeal nerve palsy when the recurrent laryngeal nerve is mechanically affected due to enlarged cardiovascular structures. We report a 28-year-old male who presented to the Government Medical College, Thiruvananthapuram, India, in 2013 with hoarseness. He had undergone irregular treatment for pulmonary tuberculosis (TB) two years previously. Fiber-optic laryngoscopy indicated left vocal cord palsy and a computed tomography scan of the chest revealed features of pulmonary hypertension with extensive enlargement of the pulmonary arteries. An echocardiogram confirmed severe pulmonary arterial hypertension with severe tricuspid regurgitation. He was diagnosed with left recurrent laryngeal palsy secondary to cardiovoal syndrome. Although reports exist of recurrent laryngeal palsy in TB, this case appears to be the first to report cardiovoal syndrome in a patient treated for pulmonary TB.

**Keywords:** Hoarseness; Pulmonary Tuberculosis; Vocal Cord Paralysis; Cor Pulmonale; Pulmonary Hypertension; Case Report; India.

**المخلص:** بحة الصوت هي حالة سريرة شائعة مختلفة الأسباب، ويمكن أن تكون حالات رجوعية وحميدة، ويمكن أن تكون مهددة للحياة وخبيثة. ويمكن أن تسبب المتلازمة القلبية-الصوتية بحة في الصوت كنتيجة ثانوية لشلل العصب الحنجري الأيسر الراجع، نتيجة لإصابة ذلك العصب بسبب ميكانيكي نتيجة لتضخم بنيات الجهاز القلبي الوعائي. ونعرض هنا حالة مريض في 28 من العمر، أحضر لمستشفى الكلية الطبية الحكومية بمدينة تيدوواندابروم في الهند في عام 2013 بسبب بحة في صوته. وكان الرجل يتلقى علاجات غير منتظمة من مرض السل الرئوي قبل عامين. وأثبت الفحص بواسطة منظار الحنجرة البصري الليفي وجود شلل في الحبال الصوتية وأوضح التصوير المقطعي المحوسب لصدر المريض علامات تدل على وجود ارتفاع في ضغط الدم الرئوي، وتضخم كبير في الشرايين الرئوية. وأكد مخطط صدى القلب وجود ارتفاع وخيم في ضغط دم الشريان الرئوي، مصحوبا بقلس الثلاثي الشرف. وتم تشخيص الحالة على أنها شلل في العصب الحنجري الأيسر الراجع نتيجة للمتلازمة القلبية-الصوتية. وعلى الرغم من وجود تقارير منشورة عن حالات لشلل العصب الحنجري الراجع عند مرضى السل، فيبدو أن هذه هي الحالة الأولى عن المتلازمة القلبية-الصوتية في مريض تعالج من السل الرئوي.

**الكلمات المفتاحية:** بحة الصوت؛ السل الرئوي؛ شلل الحبال الصوتية؛ قلب-رئوي؛ ارتفاع ضغط الدم الرئوي؛ تقرير حالة؛ الهند.

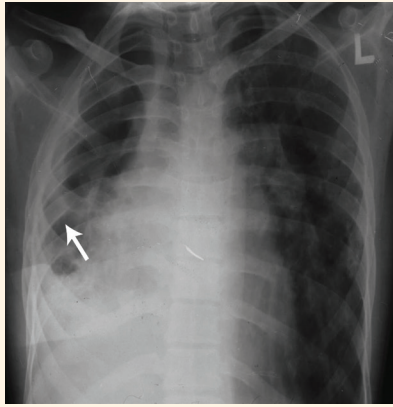
**A**MONG PATIENTS WITH TUBERCULOSIS (TB), hoarseness can occur either due to the tuberculous inflammation of the vocal cord (i.e. tuberculous laryngitis) or recurrent laryngeal nerve palsy as a result of acute lymphadenopathy, caseating granulomatous inflammation or late complications of chronic fibrosis.<sup>1,2</sup> This report describes a 28-year-old male with cardiovoal syndrome who presented with hoarseness and a history of non-compliant treatment for pulmonary TB. To the best of the authors' knowledge, although there are previous reports of recurrent laryngeal palsy in patients with TB, cardiovoal syndrome has never been before reported with pulmonary TB.<sup>3</sup>

## Case Report

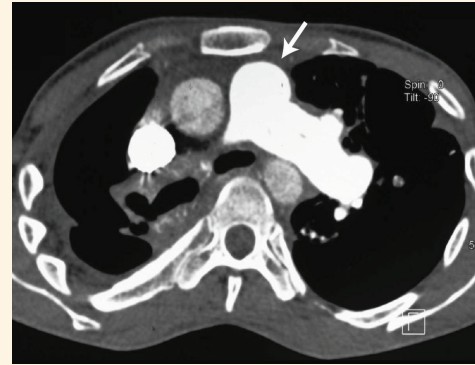
A 28-year-old male was admitted to the Government Medical College, Thiruvananthapuram, India, in 2013 with hoarseness persisting for three months. He also complained of a history of dyspnoea both upon moderate exertion during the last year and at rest over the past two days. He did not report any symptoms of coughing, haemoptysis, difficulty in swallowing, paroxysmal nocturnal dyspnoea, rheumatic fever or previous surgical interventions or trauma to the head and neck region. Two years previously, he had been diagnosed with open pulmonary TB and was prescribed a regimen of antitubercular therapy including isoniazid, rifampicin, pyrazinamide and

<sup>1</sup>Department of Medical Oncology, Regional Cancer Centre, Thiruvananthapuram, Kerala, India; <sup>2</sup>Department of Internal Medicine, Government Medical College, Thiruvananthapuram, Kerala, India; <sup>3</sup>Department of Anaesthesia, Sree Gokulam Medical College & Research Institute, Thiruvananthapuram, Kerala, India

\*Corresponding Author's e-mail: rakulnambiar@yahoo.com



**Figure 1:** Chest X-ray of a 28-year-old male with hoarseness showing extensive fibrosis of the right lung (arrow) with a mediastinal shift to the right and hyperinflation of the left lung.



**Figure 2:** Computed tomography scan of the chest of a 28-year-old male with hoarseness showing extensive central pulmonary artery dilatation (arrow), a mediastinal shift to the right and increased volume in the left lung.

ethambutol. However, due to patient noncompliance, the treatment was discontinued after two months and was only resumed five months later. At this point, the patient completed the treatment regimen and was found to be *sputum* smear-negative for TB.

Upon examination, the patient was emaciated and had bilateral pitting pedal oedema, elevated jugular venous pressure, palpable second heart sounds with a loud pulmonary component, loud right ventricular third heart sounds and a pansystolic murmur with inspiratory increase in the tricuspid area. He also exhibited features of volume loss of the right lung, including drooping shoulders and narrowing of the intercostal spaces with rib crowding on the right side of his chest. Voluntary and reflex movements of the soft palate were present and a neurological examination was essentially normal. The results of repeat *sputum* acid-fast *bacilli* stains and culture tests were negative.

Fiber-optic laryngoscopy confirmed left vocal cord palsy. A chest X-ray showed extensive fibrosis of the right lung with a mediastinal shift to the right and increased aeration of the left lung due to compensating emphysema [Figure 1]. A computed tomography (CT) scan of the chest showed signs of pulmonary arterial hypertension, including extensive dilatation of the central pulmonary artery at 32 mm, abrupt tapering of the peripheral pulmonary vessels, right ventricular hypertrophy and right atrial enlargement [Figure 2]. There was no evidence of any other mediastinal pathology. The left recurrent laryngeal nerve palsy was caused by the compression of the nerve between the aorta and dilated pulmonary artery. An echocardiogram indicated severe pulmonary arterial hypertension with severe tricuspid regurgitation causing gross dilatation of the right atrium, right ventricle and pulmonary artery (tricuspid annular plane systolic excursion: 14 mm; right ventricular systolic pressure: 55 mmHg).

The mitral valve apparatus was normal and there was no sign of aortic dilatation. A CT pulmonary angiogram ruled out a pulmonary embolism; however, arterial blood gas analysis showed hypoxaemia with hypercapnia.

A diagnosis of pulmonary hypertension group III was made according to the classifications of the World Health Organization.<sup>4</sup> As such, the patient was treated with oxygen administration, bronchodilators, a low-salt diet, diuretics (furosemide) and calcium channel blockers (diltiazem). While the symptoms of breathlessness gradually improved over the course of the following week, there was no improvement in the hoarseness. Supplemental oxygen therapy was considered; however, this was not pursued due to financial constraints. The patient was discharged after two weeks of admission and was unfortunately lost to further follow-up.

## Discussion

Also known as Ortner's syndrome, cardiovocal syndrome was first described in 1897 among three patients with severe mitral *stenosis*, wherein it was postulated that left atrial dilatation can cause left recurrent laryngeal nerve palsy due to the compression of the nerve against the aorta.<sup>5</sup> During autopsies, Fetterolf *et al.* found that the normal distance between the aorta and pulmonary artery in the aortic window was 4 mm; as such, compression of the recurrent laryngeal nerve between these structures can cause palsy.<sup>6</sup> Other causes of hoarseness in cardiac disorders include lymphadenitis in the aortic window, pressure from the left *bronchus*, right ventricular hypertrophy, pulmonary artery atherosclerosis, the anatomical position of the *ligamentum arteriosum*, a dilated pulmonary artery, mitral regurgitation, atrial myxoma or a left ventricular aneurysm.<sup>7</sup>

The left *vagus* nerve gives rise to the left recurrent laryngeal nerve at the level of the aortic arch. The recurrent laryngeal nerve then curves around the aorta on the outer side of the *ligamentum arteriosum* and ascends in the groove between the trachea and the oesophagus. This thoracic course makes the recurrent laryngeal nerve vulnerable to injury and it has been suggested that compression of the nerve between the dilated pulmonary artery and the aorta occurs among almost all patients with cardiovascular disease.<sup>7</sup> In the current case, the left recurrent laryngeal nerve palsy was due to the compression of the nerve between the dilated pulmonary artery and thoracic aorta, in which the dilated pulmonary artery was secondary to pulmonary hypertension. Initially, the suspected cause of the recurrent laryngeal nerve palsy was a mediastinal lymph node; however, this was ruled out by the chest CT scan.

Interestingly, pulmonary TB has not yet been included as a cause for the development of pulmonary hypertension in the existing Western literature. In contrast, it is not unusual to find patients in India who have been treated for pulmonary TB to present with features of right heart failure; according to a recent study, the prevalence of *cor pulmonale* among Indian patients with pulmonary TB was 11%.<sup>8</sup> Pulmonary hypertension in TB can be caused by the destruction of the vascular bed due to parenchymal abnormalities, endarteritis or vasculitis leading to the reduced cross-sectional area of the pulmonary vasculature.<sup>9</sup> It has been suggested that recurrent secondary respiratory tract infections also play an important role in the pathogenesis of pulmonary hypertension in previously treated pulmonary TB patients.<sup>10</sup> Commonly, such patients present with dyspnoea to a degree disproportionate to that indicated radiologically or with desaturation present even upon mild exertion. In rare instances, the presentation can also include overt heart failure with pedal oedema, raised jugular venous pressure and tender hepatomegaly.<sup>11</sup> This is consistent with that seen in the current case, whereby the patient presented with features of right heart failure.

Among former TB patients presenting with worsening dyspnoea, the management and diagnosis can be challenging as such cases can be misdiagnosed as a TB relapse. The correct diagnosis and timely management of pulmonary TB can prevent future complications, such as those observed in the patient described in the present case report. Although the patient had

previously received antitubercular therapy, his initial noncompliance with the treatment may have led to further lung damage and resulted in the subsequent development of pulmonary hypertension two years later.

## Conclusion

Clinicians should be aware of cardiovocal syndrome as a cause of left recurrent laryngeal nerve palsy, particularly among patients with a history of TB who may also be at risk of developing pulmonary hypertension. Although reports exist of recurrent laryngeal palsy in TB cases, cardiovocal syndrome has never before been reported among patients with pulmonary TB.

## References

1. Rafay MA. Tuberculous lymphadenopathy of superior mediastinum causing vocal cord paralysis. *Ann Thorac Surg* 2000; 70:2142–3. doi: 10.1016/S0003-4975(00)01193-0.
2. Springford LR, Ramdoo K, Nair D, Taghi A. Hoarse voice: A rare presentation of tuberculosis lymphadenitis. *BMJ Case Rep* 2016; 2016. doi: 10.1136/bcr-2016-216022.
3. Rajasekaran V, Srividhya G. A clinical study on laryngeal manifestations of tuberculosis. *Int J Otorhinolaryngol Head Neck Surg* 2017; 3:845–8. doi: 10.18203/issn.2454-5929.ijohns.20173121.
4. Simonneau G, Gatzoulis MA, Adatia I, Celermajer D, Denton C, Ghofrani A, et al. Updated clinical classification of pulmonary hypertension. *J Am Coll Cardiol* 2013; 62:D34–41. doi: 10.1016/j.jacc.2013.10.029.
5. Ortner N. [Recurrence of mitral stenosis]. *Wien Klin Wochenschr* 1897; 10:753–5.
6. Fetterolf G, Norris GW. The anatomical explanation of the paralysis of the left recurrent laryngeal nerve found in certain case of mitral stenosis. *Am J Med Sci* 1911; 141:637.
7. Subramaniam V, Herle A, Mohammed N, Thahir M. Ortner's syndrome: Case series and literature review. *Braz J Otorhinolaryngol* 2011; 77:559–62. doi: 10.1590/S1808-86942011000500004.
8. Kotresh N, Raghavendra, Kadappa J. Study of prevalence of *cor pulmonale* in patients with pulmonary tuberculosis with reference to ECG, echocardiographic changes and radiological extent of the disease. *Int J Med Res* 2016; 1:27–9.
9. Fishman AP. State of the art: Chronic *cor pulmonale*. *Am Rev Respir Dis* 1976; 114:775–94. doi: 10.1164/arrd.1976.114.4.775.
10. Kapoor SC. *Cor pulmonale* in pulmonary tuberculosis: A preliminary report on 66 patients. *Indian J Tuberc* 1959; 6:50–64.
11. Ahmed AE, Ibrahim AS, Elshafie SM. Pulmonary hypertension in patients with treated pulmonary tuberculosis: Analysis of 14 consecutive cases. *Clin Med Insights Circ Respir Pulm Med* 2011; 5:1–5. doi: 10.4137/CCRP.M.S6437.