

Efficacy of OK-432 Therapy for the Incisionless Treatment of Head and Neck Cystic Masses

Case series

*Hesham Y. A. Hasan and Muhammad A. Rizwan

فعالية العلاج بالبيسيبانييل (OK-432) للإزالة الغير جراحية لأورام منطقة الرأس والرقبة التكيسية سلسلة حالات

هشام يوسف علي حسن و محمد عامر رضوان

ABSTRACT: Head and neck masses can present in different pathologies that usually vary according to the age of the patient. We report five cases of benign head or neck masses occurring among patients of different ages who were managed at the Bahrain Defence Force Royal Medical Services Hospital, Ar-Rifaa, Bahrain, between 2005–2014. All of the patients were treated using the sclerotherapeutic agent OK-432. Although surgical removal is usually considered optimal treatment in the management of such cases, OK-432 appears to be a promising alternative.

Keywords: Sclerotherapy; OK-432; Lymphatic Abnormalities; Branchial Cyst; Thyroglossal Cyst; Cystic Hygroma; Case Series; Bahrain.

المخلص: تظهر أورام الرأس والرقبة بسبب أمراض مختلفة تختلف أنواعها عادةً حسب عمر المريض، نستعرض هنا خمس حالات أصيبت بأورام حميدة في منطقة الرأس أو الرقبة ينتمون لأعمار مختلفة وتم علاجهم في مستشفى الخدمات الطبية الملكية التابع لقوة دفاع البحرين، منطقة الرفاع، مملكة البحرين في الفترة من عام، 2005–2014. وتم علاج جميع الحالات باستخدام الدواء المحفز للتصلب من نوع OK-432، وبالرغم من أن الإزالة الجراحية تعتبر الأفضل في علاج مثل هذه الحالات، إلا أن العلاج التصلبي باستخدام OK-432 قد يوفر بديلاً مناسباً وناجحاً.

الكلمات المفتاحية: العلاج التصلبي؛ OK-432؛ عيوب الجهاز اللمفاوي؛ التكيس الخيشومي؛ التكيس الدرقي اللساني؛ الورم المائي الكيسي؛ سلسلة حالات؛ البحرين.

A MIXTURE OF BACTERIA IN A HEAT-attenuated form was first used to treat inoperable malignancies in 1891.¹ Subsequently, in 1967, a *Streptococcus pyogenes* strain was found to have a positive anticancer effect.² These experiments led to the development of OK-432, a freeze-dried product prepared from the Su strain of the group A *Streptococcus pyogenes* species. Upon exposure to benzylpenicillin and heat treatment, the toxin-producing capacity of the bacterium is eliminated and its anticancer properties are enhanced.³ This process involves heating the Su strain in the presence of benzylpenicillin at 37 °C for 20 minutes and then 45 °C for 30 minutes. At this stage, the product is known as PC-B-45 or OK-431, before becoming OK-432 after being freeze-dried.³ The product contains an intact bacterial cell wall devoid of its toxin-producing properties, consequently eliminating its ability to cause infection and proliferate. Each dose is measured in Klinische Einheit (KE), of which one KE equals 0.1 mg

of freeze-dried *Streptococci* containing approximately 1×10^8 cells.³

Cystic neck masses can be either congenital or acquired. Branchial cleft cysts, thyroglossal duct cysts, cystic lymphangiomas, dermoid cysts, *ranulae* and laryngoceles are common congenital neck masses, while acquired neck cysts include laryngoceles, cystic schwannomas and parotid cysts.⁴ A provisional diagnosis can be made based on the age and clinical presentation of the patient, which can subsequently be confirmed using radiological and pathological investigations. In general, benign cystic neck masses such as branchial cleft cysts, lymphangiomas and plunging *ranulae* are usually amenable to surgical excision; however, the lesions may recur due to the technically-challenging nature of the surgical intervention or inadequate excision to avoid nerve or vessel injury.⁵ Classically, residual disease and subsequent recurrence is more commonly encountered with lymphatic malformations and branchial cystic masses.⁶

Alternative non-surgical modalities—including cryotherapy, diathermy, radiofrequency ablation and laser treatment—have been employed in the treatment of cystic head and neck lesions, with varying degrees of success.⁷ A more appealing alternative is sclerotherapy, including bleomycin, ethanol and sodium tetradecyl sulphate.⁸ In 1986, Ogita *et al.* first noted that OK-432 injections were effective in reducing or even completely resolving unresectable paediatric lymphangiomas.⁹ Since then, OK-432 has been investigated to determine its potential benefits in treating head and neck cystic masses in both children and adults.¹⁰ Patients who fail to respond to surgical management are often successfully treated with OK-432, with even more promising results in conjunction with surgery.¹¹ Overall, OK-432 has proven effective in the treatment of malignant *ascites*, pleural effusion and lymphatic malformations.¹² This case series describes five patients with cystic head or neck lesions who were successfully treated with OK-432 therapy at the Bahrain Defence Force Royal Medical Services Hospital, Ar-Rifaa, Bahrain.

Case One

A 54-year-old woman presented in 2014 with a recurrent branchial cyst following a previous surgical excision at another hospital. Postoperatively, she had suffered from temporary palsy of the marginal mandibular branch. At presentation, the cyst measured 3.9 x 1.5 cm and was located in the left lateral region of the upper neck [Figure 1]. The patient feared undergoing a second, potentially more difficult surgery with an increased risk of complications. For this reason, intralesional OK-432 treatment was initiated. After two sessions, the cyst had regressed and was no longer visible or palpable. The patient experienced no complications. She was followed up for two years after the treatment, with no evidence of recurrence. Unfortunately, longer-term follow-up was not possible as the patient moved abroad.

Case Two

A two-year-old male child presented in 2012 with a three-month history of a cyst in the left upper neck, measuring 5.2 x 3.5 cm [Figure 2]. The patient underwent nine sessions of OK-432 sclerotherapy, with no complications, resulting in complete resolution of the lesion. The patient was followed up for four years with no evidence of recurrence.

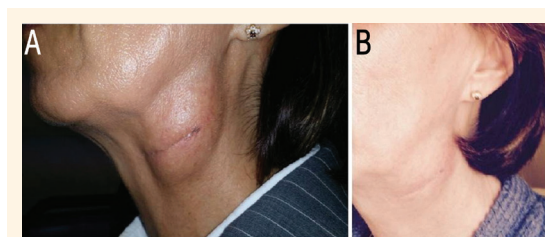

Figure 1: Photographs of a 54-year-old woman with a left branchial cyst which had (A) recurred following surgery but (B) resolved following OK-432 treatment.

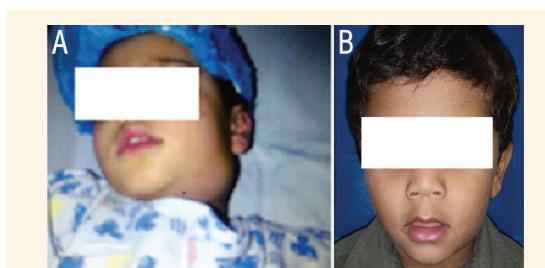


Figure 2: Photographs of a two-year-old male child with a left branchial cyst (A) before and (B) after treatment with OK-432 sclerotherapy.

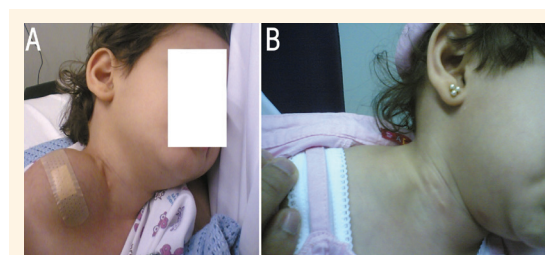


Figure 3: Photographs of an eight-month-old female child with a cystic hygroma (A) before and (B) after treatment with OK-432 sclerotherapy.

Case Three

An eight-month-old female child presented in 2005 with a congenital mass measuring 6.21 x 4.52 x 3.92 cm in the right supraclavicular *fossa* [Figure 3]. Clinically and radiologically, the mass appeared consistent with a cystic hygroma. Three sessions of OK-432 sclerotherapy resulted in the total dissolution of the cyst. The patient had no complications and was followed up for nine years with no recurrence.

Case Four

A 30-year-old woman presented in 2011 with a five-month history of a midline neck swelling that moved upon swallowing or extension of the tongue. Computed tomography of the neck showed a cystic mass measuring 2.5 x 1.5 x 2.7 cm, consistent with a thyroglossal cyst.

Table 1: Summary of five cases of benign cystic head or neck masses treated with OK-432 sclerotherapy

Case	Diagnosis	Age in years	Size in cm	Number of treatment sessions	Outcome
1	Branchial cyst	54	3.9 x 1.5	2	Resolved
2	Branchial cyst	2	5.2 x 3.5	9	Resolved
3	Cystic hygroma	0.6	6.21 x 4.52 x 3.92	3	Resolved
4	Thyroglossal cyst	30	2.5 x 1.5 x 2.7	4	Resolved
5	Benign parotid cyst	44	6.0 x 1.4	1	Resolved

As the patient did not wish to undergo a surgery which might potentially cause scarring, OK-432 treatment was her preferred option. She completed a total of four sessions of OK-432 sclerotherapy uneventfully, with no subsequent recurrence over the next three years.

Case Five

A 44-year-old man presented in 2013 with a left parotid cystic swelling that had persisted for a year. Ultrasound-guided fine needle aspiration cytology confirmed the benign nature of the cystic mass, with a final diagnosis of an idiopathic benign cyst. The patient was given a single dose of intralesional OK-432 under ultrasound guidance and the swelling resolved completely without any complications.

None of the five patients demonstrated any allergic reactions to the treatment or untoward side-effects. In addition, all of the patients were compliant with the planned treatment and participated in each session as scheduled. A summary of the cases is provided in Table 1.

Discussion

Overall, the outcome of OK-432 treatment for all five patients reported in the current case series was positive, with no undue adverse reactions observed. Several previous reports have indicated the effectiveness of OK-432 sclerotherapy as treatment for a variety of cystic neck lesions, usually resulting in total or near complete resolution of the lesion with no recurrence.¹⁰⁻¹² In their original research, Ogita *et al.* reported an overall cure rate of 91.3%.⁹ In the current case series, all five of the patients were cured as a result of OK-432 sclerotherapy; moreover, the treatment was able to resolve the postoperative recurrence of a branchial cyst in case one. Differences in the patients' ages at the time of treatment did not seem to affect the efficacy of the treatment. Additionally, none of the patients reported any skin discoloration or local scarring during or after OK-432 treatment. This is consistent with the findings of Ohta *et al.*¹³

During embryological development, the failed closure of the branchial cleft can lead to the formation of either a branchial cyst (75%) or a sinus *fistula* (25%).¹⁴ In the current case series, two patients (cases one and two) had unilocular branchial cysts. Interestingly, the first case involved an adult who had previously undergone surgical excision and subsequent recurrence of the lesion. Neither cases had residual masses after treatment, yielding a 100% response rate to OK-432 sclerotherapy alone. Kim *et al.* reported that 60.8% of patients with unilocular branchial cysts experienced total regression following OK-432 treatment, with no or partial response in cases of multilocular cysts.⁷ In another study, Roh *et al.* found that seven out of 12 patients with branchial cysts experienced full resolution following OK-432 treatment, while three patients exhibited a partial response and the treatment failed in two patients.¹⁵ In both of the aforementioned studies, patients who did not respond to OK-432 treatment subsequently underwent surgical excision, thus indicating that this may be a potential salvage option in such cases.^{7,15}

Lymphatic malformations are classified into microcystic, macrocystic and combined types. In 50% of cases, the malformations are present at birth, with another 40% emerging by the age of two years.¹⁶ The spontaneous resolution of cystic hygromas is rare and occurs in less than 12.5% of cases.¹⁷ Surgical management is complicated by the high risk of injury to the surrounding neurovascular structures, scarring and recurrence. Various sclerotherapy agents have been used to treat macrocystic lymphatic malformations, including alcoholic solution of zein, pure ethanol, bleomycin A5, doxycycline, acetic acid and polidocanol.¹⁸ In the third case reported in the present series, the patient responded well to OK-432 therapy with no residual mass or recurrence of the cystic hygroma after three doses. In their study of massive macrocystic lymphatic malformations, Chen *et al.* observed excellent outcomes with a combination of fibrin glue, OK-432 and bleomycin in 53% of patients, in comparison to good and partial outcomes in 33% and 13% of cases, respectively.¹⁹ None of the patients required surgical excision.¹⁹

Thyroglossal duct cysts account for 70% of congenital neck masses; these lesions have a bimodal age distribution in which 90% of patients present by the age of 10 years, with a second peak in young adulthood.⁴ Surgery in the form of a classic Sistrunk procedure is the preferred method of management.²⁰ Kim *et al.* reported reduction in the volume of the cyst in 81.3% of patients undergoing ethanol sclerotherapy ablation.²¹ The same authors reported that 41.4% of thyroglossal duct cysts treated with OK-432 showed complete regression.²² Ohta *et al.* reported that OK-432 therapy had better results for patients with thyroglossal cysts compared to branchial cysts.²³ However, in the current case series, there was complete regression in both cases one and four, regardless of the type of cyst.

Cystic lesions in the parotid gland can be either bilateral or unilateral and congenital or acquired. Congenital cysts can present at birth but most often reveal themselves in adulthood.⁴ Occasionally, systemic diseases such as Sjögren's syndrome and HIV may present with bilateral benign parotid cysts.²⁴ While benign parotid cysts are usually managed surgically, there has been recent evidence supporting the use of sclerotherapy. For example, Monama *et al.* reported the complete resolution of parotid cysts without morbidity in three adult patients following bleomycin sclerotherapy.²⁵ In the current case series, the fifth patient underwent aspiration of a parotid cyst under ultrasonic guidance in order to exclude malignancy before commencing OK-432 treatment. This resulted in complete regression with no recurrence within the subsequent follow-up period.

Conclusion

Sclerotherapy is the optimal therapeutic choice for a variety of benign cystic neck masses. The safety, effectiveness and economic and cosmetic advantages of the sclerotherapeutic agent OK-432 make this modality a favourable alternative to surgery in the management of various otolaryngological cystic head and neck masses, including lymphatic cystic lesions as well as thyroglossal duct and branchial cysts. Furthermore, surgery can be reserved as a salvage procedure following OK-432 treatment in cases of postsurgical recurrence or residual disease.

References

1. Wiemann B, Starnes CO. Coley's toxins, tumor necrosis factor and cancer research: A historical perspective. *Pharmacol Ther* 1994; 64:529–64. doi: 10.1016/0163-7258(94)90023-X.

2. Okamoto H, Shoin S, Koshimura S, Shimizu R. Studies on the anticancer and streptolysin S-forming abilities of hemolytic streptococci. *Jpn J Microbiol* 1967; 11:323–36. doi: 10.1111/j.1348-0421.1967.tb00350.x.
3. Okamoto H, Shoin S, Koshimura S. Streptolysin S-forming and antitumor activities of group A streptococci. In: Jeljaszewicz J, Wadstrom T, Eds. *Bacterial Toxins and Cell Membranes*. New York, USA: Academic Press Inc., 1978. P. 259.
4. Mittal MK, Malik A, Sureka B, Thukral BB. Cystic masses of neck: A pictorial review. *Indian J Radiol Imaging* 2012; 22:334–43. doi: 10.4103/0971-3026.111488.
5. Bloom DC, Perkins JA, Manning SC. Management of lymphatic malformations. *Curr Opin Otolaryngol Head Neck Surg* 2004; 12:500–4. doi: 10.1097/01.moo.0000143971.19992.2d.
6. Kim KH, Sung MW, Roh JL, Han MH. Sclerotherapy for congenital lesions in the head and neck. *Otolaryngol Head Neck Surg* 2004; 131:307–16. doi: 10.1016/j.otohns.2004.02.018.
7. Kim MG, Lee NH, Ban JH, Lee KC, Jin SM, Lee SH. Sclerotherapy of branchial cleft cysts using OK-432. *Otolaryngol Head Neck Surg* 2009; 141:329–34. doi: 10.1016/j.otohns.2009.05.022.
8. Bajpai H, Bajpai S. Comparative analysis of intralesional sclerotherapy with sodium tetradecyl sulfate versus bleomycin in the management of low flow craniofacial soft tissue vascular lesions. *J Maxillofac Oral Surg* 2012; 11:13–20. doi: 10.1007/s12663-011-0325-7.
9. Ogita S, Tsuto T, Deguchi E, Tokiwa K, Nagashima M, Iwai N. OK-432 therapy for unresectable lymphangiomas in children. *J Pediatr Surg* 1991; 26:263–8. doi: 10.1016/0022-3468(91)90500-5.
10. Smith MC, Zimmerman MB, Burke DK, Bauman NM, Sato Y, Smith RJ, et al. Efficacy and safety of OK-432 immunotherapy of lymphatic malformations. *Laryngoscope* 2009; 119:107–15. doi: 10.1002/lary.20041.
11. Kim SY, Lee S, Seo JM, Lim SY. Postoperative adjuvant OK-432 sclerotherapy for treatment of cervicofacial lymphatic malformations: An outcomes comparison. *Int J Pediatr Otorhinolaryngol* 2015; 79:570–5. doi: 10.1016/j.ijporl.2015.01.030.
12. Kitsuki H, Katano M, Ikubo A, Morisaki T, Annan K, Tanaka M, et al. Induction of inflammatory cytokines in effusion cavity by OK-432 injection therapy for patients with malignant effusion: Role of interferon-gamma in enhancement of surface expression of ICAM-1 on tumor cells in vivo. *Clin Immunol Immunopathol* 1996; 78:283–90. doi: 10.1006/clin.1996.0040.
13. Ohta N, Fukase S, Watanabe T, Ito T, Aoyagi M. Effects and mechanism of OK-432 therapy in various neck cystic lesions. *Acta Otolaryngol* 2010; 130:1287–92. doi: 10.3109/00016489.2010.483480.
14. Deane SA, Telander RL. Surgery for thyroglossal duct and branchial cleft anomalies. *Am J Surg* 1978; 136:348–53. doi: 10.1016/0002-9610(78)90292-1.
15. Roh JL, Sung MW, Hyun Kim K, Il Park C. Treatment of branchial cleft cyst with intracystic injection of OK-432. *Acta Otolaryngol* 2006; 126:510–4. doi: 10.1080/00016480500437443.
16. Mulligan PR, Prajapati HJ, Martin LG, Patel TH. Vascular anomalies: Classification, imaging characteristics and implications for interventional radiology treatment approaches. *Br J Radiol* 2014; 87:20130392. doi: 10.1259/bjr.20130392.
17. Kennedy TL. Cystic hygroma-lymphangioma: A rare and still unclear entity. *Laryngoscope* 1989; 99:1–10. doi: 10.1288/00005537-198910001-00001.
18. Farnoosh S, Don D, Koempel J, Panossian A, Anselmo D, Stanley P. Efficacy of doxycycline and sodium tetradecyl sulfate sclerotherapy in pediatric head and neck lymphatic malformations. *Int J Pediatr Otorhinolaryngol* 2015; 79:883–7. doi: 10.1016/j.ijporl.2015.03.024.

19. Chen WL, Huang ZQ, Chai Q, Zhang DM, Wang YY, Wang HJ, et al. Percutaneous sclerotherapy of massive macrocystic lymphatic malformations of the face and neck using fibrin glue with OK-432 and bleomycin. *Int J Oral Maxillofac Surg* 2011; 40:572–6. doi: 10.1016/j.ijom.2011.01.009.
20. Al-Thani H, El-Menyar A, Sulaiti MA, El-Mabrok J, Hajaji K, Elgohary H, et al. Presentation, management, and outcome of thyroglossal duct cysts in adult and pediatric populations: A 14-year single center experience. *Oman Med J* 2016; 31:276–83. doi: 10.5001/omj.2016.54.
21. Kim SM, Baek JH, Kim YS, Sung JY, Lim HK, Choi H, et al. Efficacy and safety of ethanol ablation for thyroglossal duct cysts. *AJNR Am J Neuroradiol* 2011; 32:306–9. doi: 10.3174/ajnr.A2296.
22. Kim MG, Kim SG, Lee JH, Eun YG, Yeo SG. The therapeutic effect of OK-432 (picibanil) sclerotherapy for benign neck cysts. *Laryngoscope* 2008; 118:2177–81. doi: 10.1097/MLG.0b013e3181864acf.
23. Ohta N, Fukase S, Suzuki Y, Ishida A, Aoyagi M. Treatments of various otolaryngological cystic diseases by OK-432: Its indications and limitations. *Laryngoscope* 2010; 120:2193–6. doi: 10.1002/lary.21141.
24. Shanti RM, Aziz SR. HIV-associated salivary gland disease. *Oral Maxillofac Surg Clin North Am* 2009; 21:339–43. doi: 10.1016/j.coms.2009.04.002.
25. Monama GM, Tshifularo MI. Intralesional bleomycin injections in the treatment of benign lymphoepithelial cysts of the parotid gland in HIV-positive patients: Case reports. *Laryngoscope* 2010; 120:243–6. doi: 10.1002/lary.20577.