

Nodular Fasciitis and Myxolipoma of the Larynx

A rare case report with brief literature review

*Ahmad Al Omari,¹ Wisam Qarqaz,¹ Rasha A. Alrhman,¹ Ra'ed Al-Ashqar,¹ Samir Al Bashir,² Mohammed Alorjani²

ABSTRACT: Nodular fasciitis (NF) is a peculiar, rapid-growing soft tissue lesion, typically appearing in subcutaneous tissue. Approximately 20% of NF occurs in the head and neck region, where they can involve any anatomic site. Laryngeal involvement, however, is quite rare. Lipoma is recognised as a slow growing, benign mesenchymal tumour; myxolipoma is a rare variant which has a prominent myxoid background. Laryngeal lipoma is infrequent, accounting for only 0.6% of all benign laryngeal lesions. We report a 61-year-old male patient with laryngeal nodular fasciitis coexisting with myxolipoma who presented to a tertiary care hospital in Ar Ramtha, Jordan, in 2020. Radiological and histological findings were indicative of laryngeal nodular fasciitis and myxolipoma was incidentally diagnosed. Following trans-oral debulking of the lesion the mass enlarged rapidly and the patient underwent a tracheostomy with complete mass excision and right partial laryngectomy through an open surgical approach. The patient had an uneventful recovery with no evidence of recurrence. The purpose of this report is to broaden the differential diagnosis of rapid-growing laryngeal masses that cause airway obstruction and to stress the significance of integrative interdisciplinary collaboration to establish an accurate diagnosis, thereby allowing proper management for benign pathologies and avoid futile aggressive treatment.

Keywords: Nodular Fasciitis; Larynx; Stridor; Neck; Case Report; Jordan.

NODULAR FASCIITIS (NF), A SUBTYPE OF benign mesenchymal spindle cell tumor-like lesions, is a non-cancerous, reactive fibrous proliferation which makes up almost 11% of all benign soft tissue tumours.¹

Although Konwaler *et al.* first described this condition as 'pseudosarcomatous fasciitis' in 1955, it was not until 1961 that Shuman used the term 'nodular fasciitis' for the first time and since then it has been broadly adopted by authors.²

NF arises mostly in the extremities and trunk, with the larynx being a very rare location;³ diagnosis of NF is challenging in this region. In most cases, the patient presents with a painless, rapidly expanding subcutaneous mass. However, unlike other locations, laryngeal NF may cause life-threatening symptoms by obstructing the respiratory tract.

In contrast, lipoma is a common slow developing benign mesenchymal tumour, with approximately 15% of lipomas being found in the head and neck.⁴ Due to the presence of scant amounts of adipose tissue in the larynx, laryngeal occurrence is infrequent.⁵ Myxolipoma is a rare variant which has prominent myxoid areas. To the best of the authors' knowledge, only four cases of laryngeal myxolipomas, one of them being juvenile, have been reported in the English literature.^{6–9} This case report describes a patient with laryngeal nodular fasciitis coexisting with myxolipoma.

Case Report

A 61-year-old male patient, who is a heavy smoker, presented to the ENT outpatient clinic of a tertiary care hospital in Ar Ramtha, Jordan, in 2020, complaining of a change in his voice, which had started few months earlier, associated with dysphagia, intermittent dyspnoea and choking. His surgical history was unremarkable except for a laparoscopic cholecystectomy one year ago. There was no history of trauma and head and neck examination was unremarkable. A large right supraglottic mass was identified by flexible nasolaryngoscopy. Radiological findings were suggestive of a locally advanced laryngeal cancer measuring 5.1 × 3.8 × 3.7 cm [Figure 1]. Biopsy was taken by suspension microlaryngoscopy for precise diagnosis and the results were suggestive of a benign/borderline spindle cell neoplasm.

Due to its benign nature, the lesion was debulked trans-orally via laser and histologic diagnosis was in favour of laryngeal NF. Shortly after surgery, the mass rapidly enlarged. A tracheostomy was performed and he underwent complete mass excision with right partial laryngectomy through an open surgical approach [Figure 2]. Repeated pathological examination of microscopic sections and an immunohistochemistry study revealed the same findings which were in agreement with the aforementioned diagnosis of laryngeal NF, along with incidental myxolipoma

¹Department of Special Surgery, Faculty of Medicine, Jordan University of Science and Technology, Irbid, Jordan; ²Department of Pathology and Laboratory Medicine, Jordan University of Science and Technology, Irbid, Jordan

*Corresponding Author's e-mail: aialomari@just.edu.jo

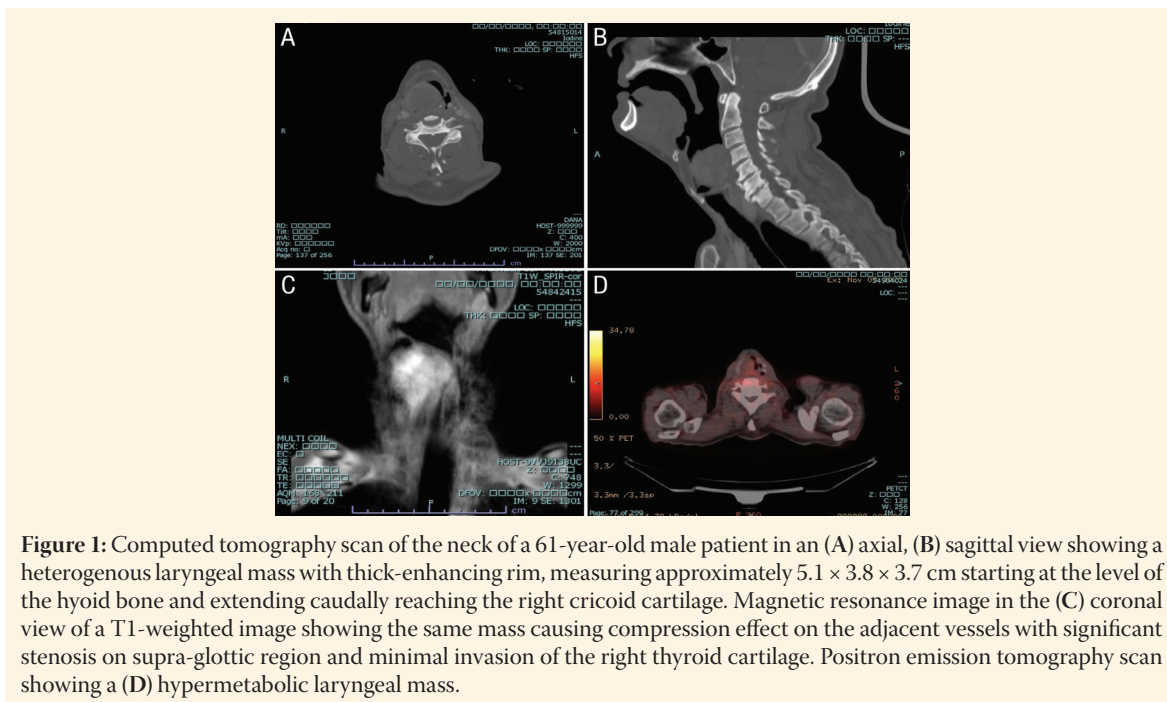


Figure 1: Computed tomography scan of the neck of a 61-year-old male patient in an (A) axial, (B) sagittal view showing a heterogenous laryngeal mass with thick-enhancing rim, measuring approximately $5.1 \times 3.8 \times 3.7$ cm starting at the level of the hyoid bone and extending caudally reaching the right cricoid cartilage. Magnetic resonance image in the (C) coronal view of a T1-weighted image showing the same mass causing compression effect on the adjacent vessels with significant stenosis on supra-glottic region and minimal invasion of the right thyroid cartilage. Positron emission tomography scan showing a (D) hypermetabolic laryngeal mass.

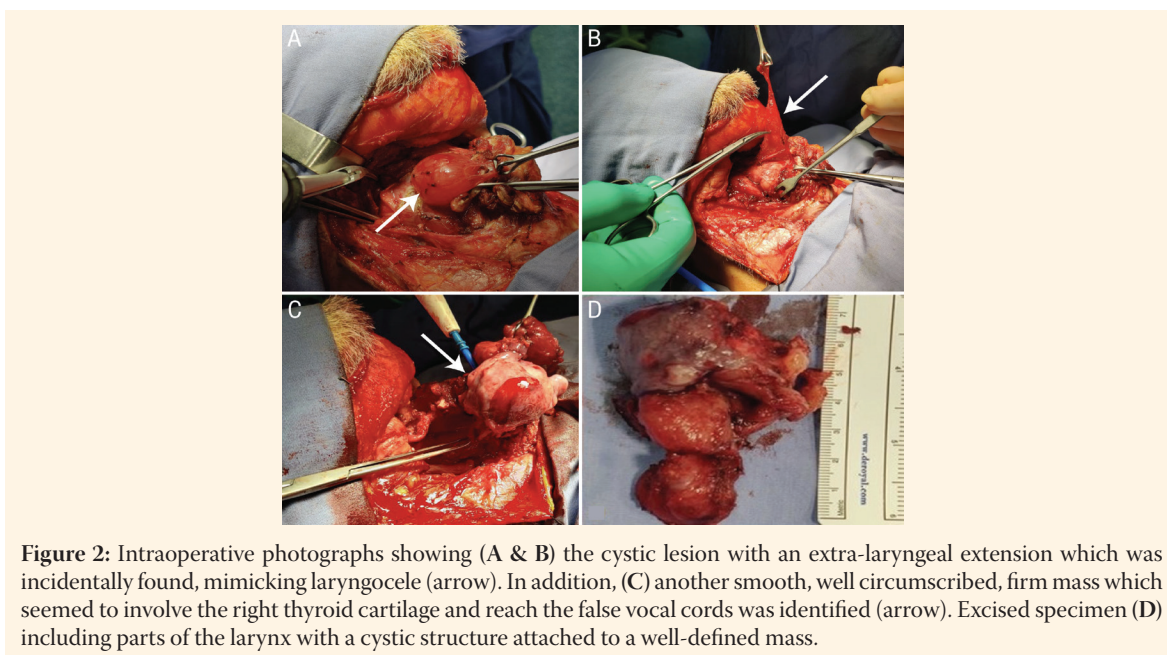


Figure 2: Intraoperative photographs showing (A & B) the cystic lesion with an extra-laryngeal extension which was incidentally found, mimicking laryngocele (arrow). In addition, (C) another smooth, well circumscribed, firm mass which seemed to involve the right thyroid cartilage and reach the false vocal cords was identified (arrow). Excised specimen (D) including parts of the larynx with a cystic structure attached to a well-defined mass.

[Figures 3 and 4]. Postoperatively, the patient recovered uneventfully with no evidence of recurrence. His health improved and he is currently under regular follow-up. Written informed consent was obtained from the patient for publication purposes.

Discussion

NF is a rare, but distinct, benign self-limited mesenchymal neoplasm of fibroblastic/myofibroblastic derivation that resembles soft tissue sarcoma. The aetiology is still not fully understood. Although not documented in the vast majority of patients, traumatic insult may

trigger this reactive inflammatory response.³ While occurring at all ages, this condition is most often diagnosed in adults 20–40 years of age, with no gender predilection.⁵ Clinically, when appearing in the larynx, the main presenting symptoms are related to the degree of laryngeal obstruction. This may include hoarseness of voice, foreign body sensation, dysphagia, as well as dyspnoea and stridor that may require urgent medical attention. Despite most of the lesions being less than 2 cm in its greatest dimension at the time of diagnosis, the size can vary from 0.5–10 cm.⁶

Lipoma is a benign tumor consisting of adipose tissue. It is considered the most common mesenchymal

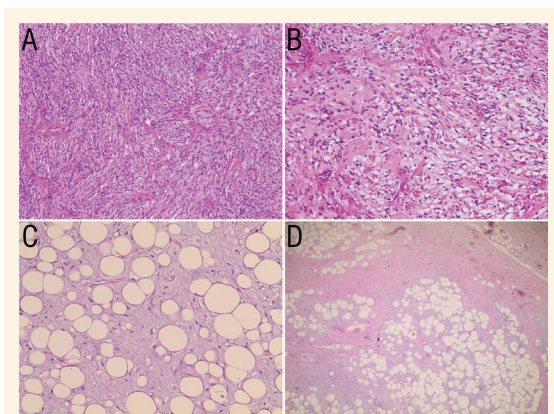


Figure 3: Haematoxylin and eosin stains at (A) ×20 magnification showing spindled and plump cells exhibiting fascicular arrangement in myxofibrotic background (lesional cells demonstrate storiform architecture); at (B) ×40 magnification showing benign-looking, uniform, stellate fibroblasts resembling a tissue culture-like appearance and; at (C) ×40 and (D) ×10 magnification showing mature-appearing adipocytes with prominent myxoid areas. No evidence of atypia, plexiform vascular network or lipoblasts.

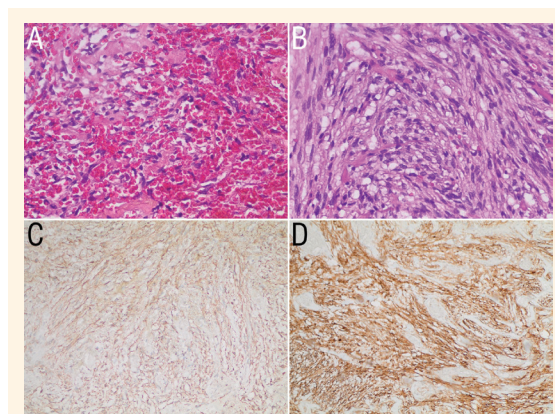


Figure 4: Haematoxylin and eosin stains at ×40 magnification showing (A) numerous extravasated red blood cells and scattered chronic inflammatory cells and (B) lesional cells of nodular fasciitis which typically have ovoid nuclei and prominent nucleoli. Immunohistochemistry study showing diffuse expression of smooth muscle antibody immunohistochemical marker in the (C) lesional cells and (D) cluster of differentiation 10 positive immunostaining of nodular fasciitis.

tumor, constituting 16% of soft tissue tumours.⁶ Lipoma of larynx can be subdivided according to the site of origin into intrinsic (endolaryngeal) type, or more commonly the extrinsic type. It has a male predominance and occurs over a wide age range (mean age: 40 years) with a supraglottic predisposition.⁴ The aetiology of laryngeal lipomas is unclear. Unlike other locations, laryngeal lipomas may occasionally cause fatal airway obstruction with dyspnoea and dysphonia being the most frequent presenting symptoms. Grossly, it can be sessile or pedunculated, usually appearing as a smooth, well-encapsulated mass. The size typically ranges from 1–3 cm, but sometimes it may exceed 10 cm.⁷

On CT scan most NF lesions appear as a well-defined homogeneous mass with low or isodensity and show moderate to strong enhancement. On MRI, lesions will exhibit hypointense or isointense signals on T1-weighted sequences and show heterogeneous intermediate-to-high signal on T2-weighted sequences.^{8,9} For lipomas, imaging serves a vital role in diagnosis. On CT scan, it mostly simulates fatty tissue characteristics, thus lipomatous lesions appear as a homogenous mass with low attenuation. On MRI, lipoma has predominantly low signal intensity on T1-weighted images and markedly high signal intensity on T2-weighted images.¹⁰

Lesions of NF are often composed of undulating short, intersecting fascicles of haphazardly arranged plump, immature fibroblasts and myofibroblasts in a loose myxoid and/or fibrous stroma which resembles the feathery or tissue culture-like appearance. The

cells have uniform, elongated non-pleomorphic nuclei with pale, fine chromatin and small but prominent nucleoli. Some typical mitotic activity is commonly seen. Numerous extravasated red blood cells, scattered lymphocytes, chronic inflammatory cells and multinucleated osteoclast-like giant cells are also present within the background.¹¹

Likewise, lipomas have some distinctive histological features, being generally composed of mature adipocytes bound by thin fibrous capsules. Myxolipoma demonstrates similar features, but with abundant extracellular mucoid matrix.¹²

Myofibroblasts often stain for smooth muscle actin, muscle-specific actin and vimentin. Meanwhile, none of lesional cells express S100 protein, β -catenin, cluster of differentiation 34, keratin, caldesmon and desmin. The proliferation index with Ki67 can be high in reactive lesions such as NF.¹³ It should be noted that immunohistochemistry is not of much help in diagnosing myxolipoma.

In regard to the post-genomic era and cytogenetic tests, few studies have established the molecular and cytogenetic abnormalities or proven the neoplastic nature of NF. For example, Erikson-Johnson *et al.* described the USP6 rearrangement with the formation of the fusion gene *MYH9-USP6*, which is commonly observed in these lesions, and referred to NF as “transient neoplasia” due to its self-limiting nature.¹⁴

Given the paucity of cases of NF involving the larynx, their natural course is not fully understood. However, assuming that the behaviour would be similar to NF in other anatomic sites and as this lesion

has neither a high local recurrence propensity nor metastatic potential, adequate surgical excision of the lesion with negative margins could be sufficient as was seen in the current patient.

Yet, due to anatomical factors and critical structures, laryngeal NF lesions can be unamenable to simple complete laryngoscopic local excision. Hence, a partial laryngectomy, whether endoscopic or open (based on the lesion, surgeon's skills and patient factors) could be an appropriate choice in favour of vocal function preservation. Total laryngectomy should be performed in selected cases with advanced diseases or reserved as salvage surgery.

Other controversial conservative methods such as intralesional corticosteroid injection can be considered when there are no substantial symptoms and spontaneous regression is expected. Surgical excision is recommended in the case of laryngeal lipoma. Depending on the size, endoscopic approach is preferred in small lipomas, whereas open surgical approach must be used if the lesion's dimension is greater than 2 cm. As for benign lesions, the prognosis for laryngeal lipoma is very good. Recurrence is rare and is mostly due to hidden malignancy or inadequate excision; because of this, long-term follow-up is recommended.¹⁵

Conclusion

NF of the larynx can mimic malignant tumors, thus reaching an exact diagnosis is very challenging. Although it has a favorable prognosis compared to other aggressive laryngeal lesions, simple lesional resection in this unique location might be difficult and laryngectomy could be unavoidable. Laryngeal myxolipoma is rare but must be considered in the differential diagnosis of laryngeal masses.

AUTHOR'S CONTRIBUTION

AO and RAA performed the literature review. All authors contributed to the drafting of the manuscript. All authors approved the final version of the manuscript.

References

- Kransdorf MJ. Benign soft-tissue tumors in a large referral population: Distribution of specific diagnoses by age, sex, and location. *AJR Am J Roentgenol* 1995; 164:395–402. <https://doi.org/10.2214/ajr.164.2.7839977>.
- Price EB Jr, Silliphant WM, Shuman R. Nodular fasciitis: A clinicopathologic analysis of 65 cases. *Am J Clin Pathol* 1961; 35:122–36. <https://doi.org/10.1093/ajcp/35.2.122>.
- Dickson BC. Nodular fasciitis. From: <https://www.pathologyoutlines.com/topic/softtissueenf.html> Accessed: Jun 2021.
- de Bree E, Karatzanis A, Hunt JL, Strojjan P, Rinaldo A, Takes RP, et al. Lipomatous tumours of the head and neck: A spectrum of biological behaviour. *Eur Arch Otorhinolaryngol* 2015; 272:1061–77. <https://doi.org/10.1007/s00405-014-3065-8>.
- Azandaryani AR, Eftekharian M, Taghipour M. Large laryngeal lipoma with extra laryngeal component mimics mixed form laryngocele: A case report. *Adv J Emerg Med* 2019; 3:e45. <https://doi.org/10.22114/ajem.v0i0.196>.
- Singhal SK, Virk RS, Mohan H, Palta S, Dass A. Myxolipoma of the epiglottis in an adult: A case report. *Ear Nose Throat J* 2005; 84:728,730,734. <https://doi.org/10.1177/014556130508401117>.
- Rozas Aristy F, Espino Durán M, Zapateiro J. [Myxoid lipoma of the larynx]. *Rev Med Panama* 1991; 16:33–8. <https://doi.org/10.22206/cys.1991.v16i4.pp359-75>.
- Verma R, Sardana N, Verma RR. Multiple Myxoid Lipomas Supraglottic Region, *Int J Phonosurg Laryngology* 2011; 1:88–90. <https://doi.org/10.5005/jp-journals-10023-1023>.
- Dinsdale RC, Manning SC, Brooks DJ, Vuitch F. Myxoid laryngeal lipoma in a juvenile. *Otolaryngol Head Neck Surg* 1990; 103:653–7. <https://doi.org/10.1177/019459989010300423>.
- Çelik SY, Dere Y, Çelik ÖL, Derin S, Şahan M, Dere Ö. Nodular fasciitis of the neck causing emergency: A case report. *Oman Med J* 2017; 32:69–72. <https://doi.org/10.5001/omj.2017.13>.
- Razek AA, Huang BY. Soft tissue tumors of the head and neck: Imaging-based review of the WHO classification. *Radiographics* 2011; 31:1923–54. <https://doi.org/10.1148/rg.317115095>.
- Ma Y, Zhou B, Wang S. Large lipoma in the subglottic larynx: A case report. *J Int Med Res* 2020; 48:300060520928786. <https://doi.org/10.1177/0300060520928786>.
- Khuu A, Yablon CM, Jacobson JA, Inyang A, Lucas DR, Biermann JS. Nodular fasciitis: characteristic imaging features on sonography and magnetic resonance imaging. *J Ultrasound Med* 2014; 33:565–73. <https://doi.org/10.7863/ultra.33.4.565>.
- Lu L, Lao IW, Liu X, Yu L, Wang J. Nodular fasciitis: A retrospective study of 272 cases from China with clinicopathologic and radiologic correlation. *Ann Diagn Pathol* 2015; 19:180–5. <https://doi.org/10.1016/j.anndiagpath.2015.03.013>.
- Gupta P, Potti TA, Wuertzer SD, Lenchik L, Pacholke DA. Spectrum of fat-containing soft-tissue masses at MR Imaging: The common, the uncommon, the characteristic, and the sometimes confusing. *Radiographics* 2016; 36:753–66. <https://doi.org/10.1148/rg.2016150133>.