

## **A Rare Primary Location of Echinococcal Disease: Report of a Case**

Baris Zulfikaroglu, Mahmut Koc, Necdet Ozalp,  
M Mahir Ozmen,

*Department of Surgery Ankara Numune Teaching and Research Hospital, 06100-Ankara, Turkey*

### **ABSTRACT**

A case of primary hydatid disease, a rare location, is presented. The patient was a 20 year old female who presented with complaining of painful mass in the right hypochondrium 2 months before presentation. This cyst was strongly adherent to the two layers of m.rectus abdominis fascias. It was completely removed. No other site of hydatid disease was found and the patient remained well postoperatively.

### **INTRODUCTION**

Human hydatid disease is caused by the larvae of the genus echinococcus. The four species known to infect man are *E.granulosus*, *E.multilocularis*, *E.oligarthrus*, *E.vogeli* (1, 2). *E.granulosus* is by far the most common cause of disease, followed by *E.multilocularis*, which causes the alveolar form of the disease. Primary hydatid cysts usually localize in the liver (80%), and lungs (15%), but they can affect other organs and body tissues (2, 3, 4).

We present a case with a rare location of primary hydatid cyst, located at the intrafascial location of the abdominal wall.

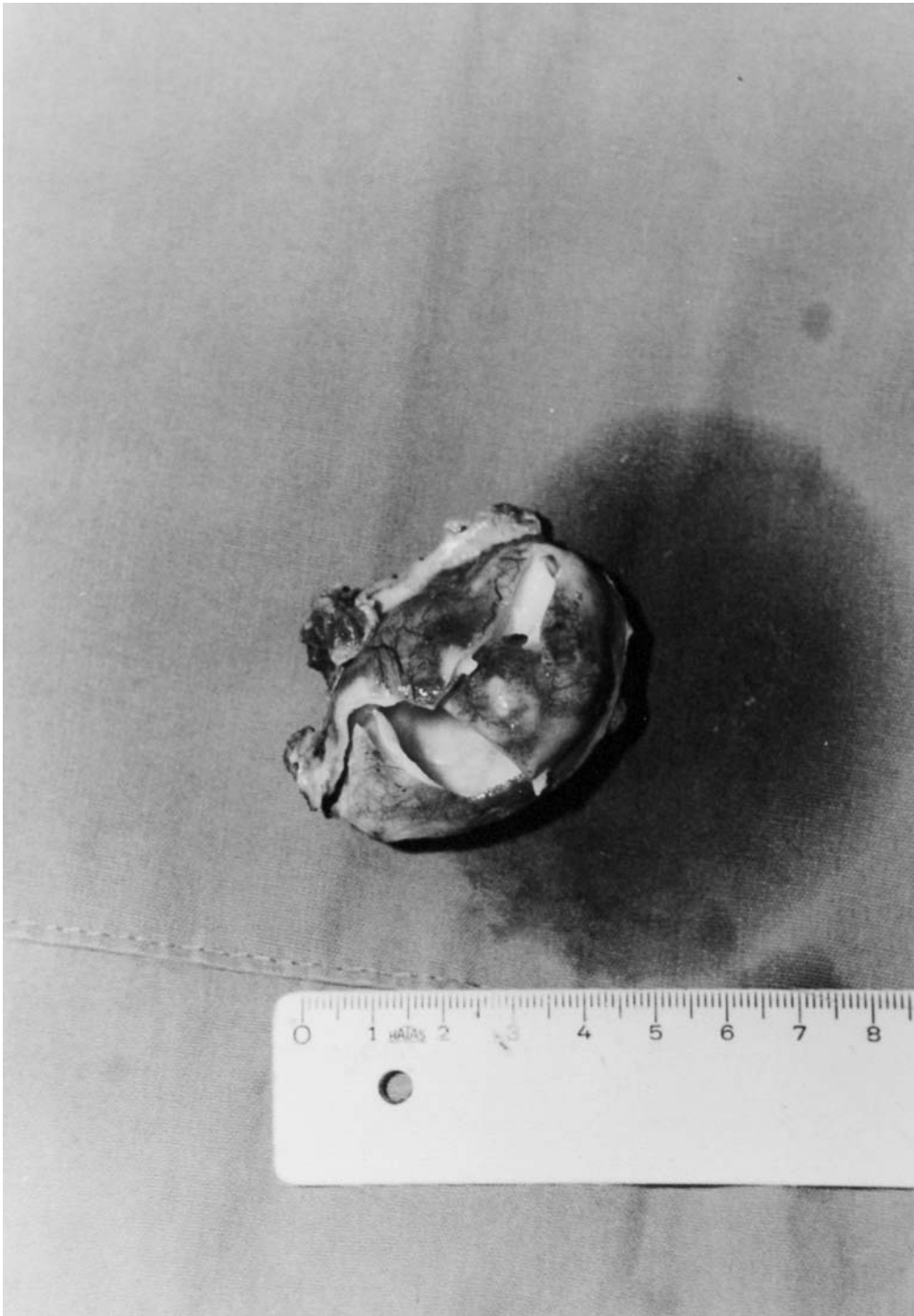
### **CASE REPORT**

A 20 year-old woman was admitted to our clinic, with the complain of painful mass in the right hypochondrium noticed two months before presentation. On physical examination, the mass was firm, smooth, tender, not fixed to the overlying skin but fixed to deeper tissue. There was no history of trauma. Laboratory studies showed a total leukocyte count of  $6.8 \times 10^9$ /liter, and eosinophil count of  $620/\text{mm}^3$ ; all other biochemical parameters of serum and urine were in the normal range. Serological tests for *Echnicoccus* were positive (1:64 by Latex test and 1:2560 by Indirect

---

Received 1 November 2004  
Accepted 21 December 2004

*Key words:* Hydatid disease, Rare location, Primary



*Fig. 1.* The cyst was completely excised.

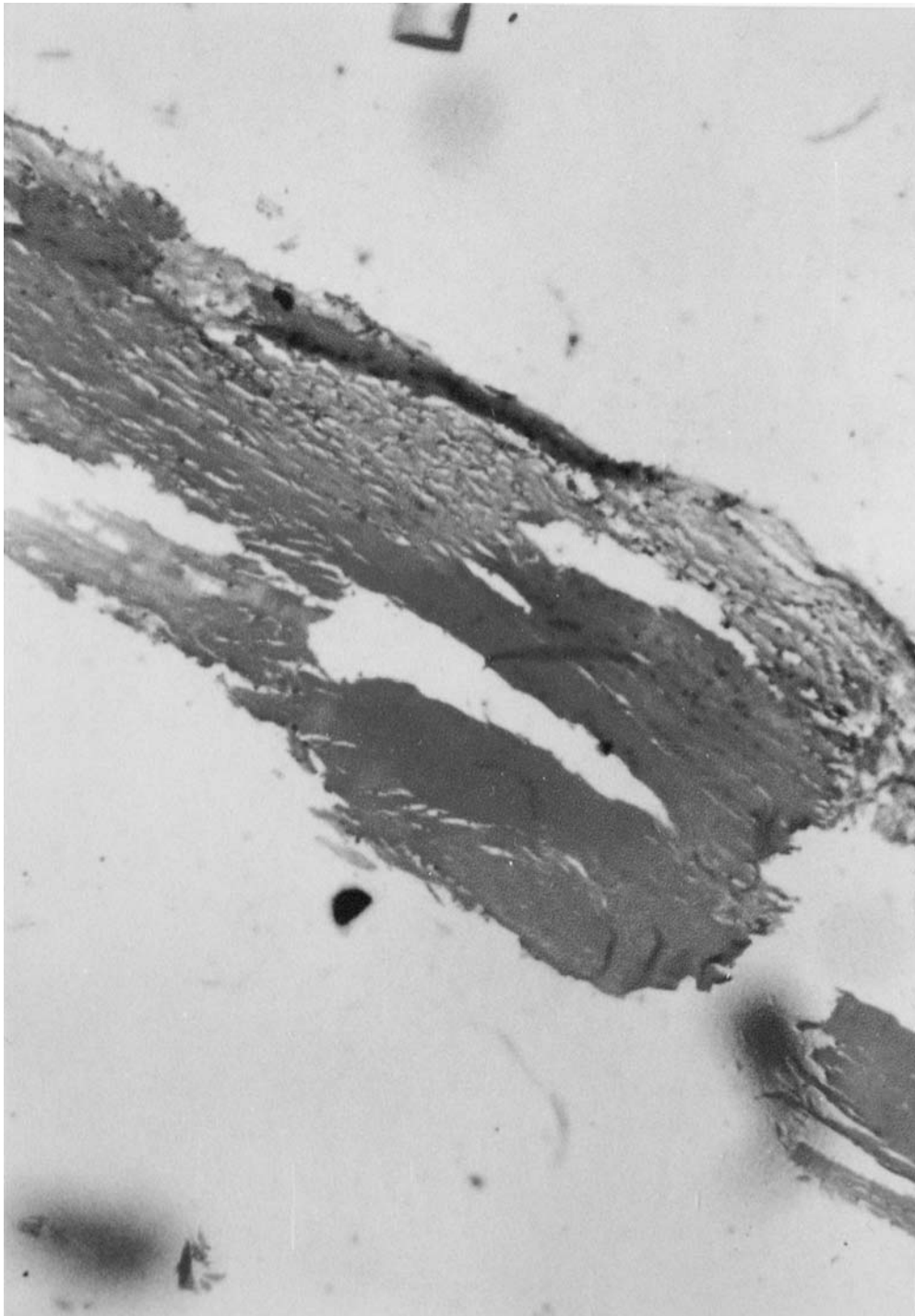


Fig. 2. Pathologic study of the specimen confirmed the *Echinococcus*.

hemagglutination). Ultrasonography and a computed tomography scan showed a cyst of 5 cm in the right rectus abdominis muscle. Laparotomy was performed via a right subcostal incision on the presumptive diagnosis of hydatid cyst. A cystic mass of 40×50×30 mm was found between the two fascial layers of m.rectus abdominis. Routine abdominal exploration was carried out, but no other cyst or abnormality was found in the abdominal cavity. The cyst was completely excised (Photograph 1) and soft tissue was washed with 0.5% silver nitrate solution. Pathologic study of the specimen confirmed the *Echinococcus* (photograph 2). Abdominopelvic ultrasonography, intravenous pyelography, lung tomography, whole body skeletal scanning, and cranial CT performed postoperatively. There was no evidence of any other foci of hydatid disease. The patient was discharged on the 10<sup>th</sup> postoperative day in a satisfactory condition. Patient was administered 10 mg/kg per day oral albendazole therapy 1 week before surgery. Albendazole therapy was continued for three sessions, each lasting 4 weeks separated by fourteen days intervals postoperatively (5). Follow-up at 3 years, after yearly repeat examination showed no recurrence of hydatid disease. The patient was informed about the case report.

## DISCUSSION

These are the first reported cases of intrafascial involvement with *E.granulosus*. Hydatid disease is a parasitic infection caused by several species of the cestode echinococcus, but the most common is *Echinococcus granulosus*. *Echinococcus* is endemic to many parts of the world, in most sheep- and cattle-raising areas, including Australia, South America, Middle East, South Africa, Eastern Europe, and the Mediterranean region. Although hydatid cysts were known commonly to affect the liver, lung, spleen, it also affects the brain, heart, kidney, ureter, uterus, fallopian tube, mesentery, pancreas, diaphragm, and muscles (3, 4).

The clinical presentation of hydatid disease depends on the size and site of the lesion and the accessibility of the organ involved for clinical examination. As it has been studied previously, the most important factor in diagnosing hydatid disease in unusual localizations is the awareness of its possibility and any growing mass in a patient coming from an endemic region should arise the suspicion of hydatid disease (6).

Diferent serologic tests are being carried out for the diagnosis, screening and post-operative follow-up for recurrence. These include the hydatid immunoelectrophoresis, enzyme-linked immunosorbent assay (ELISA), latex agglutination and indirect haemagglutination (IHA) test (7).

Preoperative diagnosis of hydatid cysts could be made by imaging methods (8). In this case, as well as others, ultrasonography was the most helpful investigations.

The best therapeutic option of hydatid cysts is principally surgical. However, medical therapy with mebendazole or albendazole should be considered in order to sterilize the cyst, decrease the chance of anaphylaxis, decrease the tension in the cyst wall and to reduce the recurrence rate post-operatively (9). Intra-operatively,

the use of hypertonic saline or 0.5% silver nitrate solutions before opening the cavities tends to kill the daughter cysts and therefore prevent further spread or anaphylactic reaction.

Although we made all necessary laboratory investigations postoperatively, there was no other cyst or abnormality in the abdomen or in any other system of the body in our patient. We assumed that the cyst was primary. We believe that embryo has reached the fascia from the systemic circulation after leaving the intestine and passing through two filters: the liver and the lungs.

Detailed investigation is essential in any patient with hydatid disease in an unusual site in order to determine whether the cyst is primary or secondary.

Location of hydatid disease between the two fascial layers of m.rectus abdominis is extremely rare. Although hydatid cyst can rarely be found in subcutaneous tissue (1%), to the best of our knowledge, an intrafascial localization of hydatid cyst has never been reported. If the cyst is found in this location, it should be totally excised.

## REFERENCES

1. Ammann RW, Eckert J (1996) Parasitic diseases of the liver and intestines-Echinococcus. *Gastroenterol Clin North Am* 25: 655–689.
2. Hadni SB, Humbert P, Paintaud G, Auer H, Miguet JP (1996) Skin localization of alveolar echinococcus of the liver. *J Am Aca Derm* 34: 873–877.
3. Saracho JO, Zarza LP, Sanchez J (1998) An unusual cause of pulmonary artery thrombosis. *Chest* 114: 309–311.
4. Cangiotti L, Muisean P, DeCesare V, Pouché A, Giulini SM, Tiberio G (1994) Unusual localizations of hydatid disease: a 18 year experience. *Giorn Chir* 15: 83–86.
5. Ozmen MM, Coskun F (2002) New technique for finding the ruptured bile duct into the liver cysts: scope in the cave technique. *Surg Lap Endosc Perc Tech* 12(3): 187–189.
6. Enamy H, Asadian A (1976) Unusual presentation of hydatid disease. *Am J Surg* 132: 403–405.
7. Abu-Eshy SA (1998) Some rare presentations of hydatid cyst (*Echinococcus granulosus*): Case report. *J R Coll Surg Edinb* 43: 347–352.
8. Brown RA., Millar AIW, Steiner Z, Krige JEJ, Burkimsher D, Cywes S (1995) Hydatid cyst of the pancreas: a case report in child. *Eur J Pediatr Surg* 5: 121–124.
9. Goel MC, Agarwal MR, Misra A (1995) Percutaneous drainage of renal hydatid cyst: early results and follow-up. *Br J Urol* 75: 724–728.

*Corresponding author:* Baris Zulfikaroglu MD  
7.Cadde 70 A /14,  
06490-Bahcelievler Ankara-Turkey  
Tel: +90-312-2158652  
Fax: +90-312-3103460  
E-mail: zbaris61@hotmail.com