

Evaluation of Urinary Stones Ex Vivo With Micro-Computed Tomography

Preliminary Results of an Investigational Technique

Emre Huri,^{1,2} İlkan Tatar,² Cankon Germiyanoglu,¹ Tolga Karakan,¹
Hakan Hamdi Çelik,² Orkun Ersoy³

Purpose: To evaluate the ultrastructural features of the urinary stones removed with endoscopic stone surgery, using micro computed tomography (micro-CT).

Materials and Methods: Patients who had endoscopic surgery for renal or ureteral stones removal were included in this study. After surgery, the stones were classified into three groups and investigated with Skyscan 1174 micro-CT. Group I underwent percutaneous nephrolithotomy (PNL) with ultrasonic lithotripsy; group II had ureteroscopic stone surgery (USS) with pneumatic lithotripsy; and group III (the control group) had stone removal with USS or PNL without lithotripsy. Stone homogeneity, voids, and the internal structure of the stones were evaluated. Chi-square test was used to evaluate the difference statistically. *P* values less than .05 were considered statistically significant.

Results: A total of 24 “calcium oxalate monohydrate” stones from 24 patients were scanned with micro-CT. Stones treated with ultrasonic lithotripsy (group I) were more fragile, fragmented, and cracked than those treated with the pneumatic lithotripsy (group II; *P* = .01). Stones in group II were more homogeneous and smooth than those in group I and resembled those of the control group (*P* = .02). Homogeneous, non-fragile stones and heterogeneous, fragile calculi were seen in all groups.

Conclusion: The stone fragility could be confirmed by micro-CT investigation. Ultrasonic lithotripters increase the stone fragility, which is demonstrated with increased heterogeneity by micro-CT.

Keywords: urinary calculi, micro-CT scan, radiographic image interpretation, calcium oxalate

Urol J. 2011;8:185-90.
www.uj.unrc.ir

¹Second Urology Clinic, Ministry of Health,
Ankara Training and Research Hospital,
Ankara, Turkey

²Department of Anatomy, Medical School,
Hacettepe University, Ankara, Turkey

³Department of Geological Engineering,
Hacettepe University, Ankara, Turkey

Corresponding Author:
Emre Huri, MD, FEBU
Associate Professor of Urology
Department of Second Urology Clinic,
Ankara Training and Research Hospital;
Department of Anatomy, Medical School,
Hacettepe University, Ankara, Turkey
Tel: +90 312 595 3720
E-mail: dremrehuri@yahoo.com

Received July 2010
Accepted April 2011

INTRODUCTION

The treatment of choice for large renal and proximal ureteral stones (> 2 cm) is usually percutaneous nephrolithotomy (PNL). Ureteroscopic stone surgery (USS) is also applied for ureteral stones larger than 1 cm.⁽¹⁾ In these operations, stone removal is generally achieved following breaking of stones. To accomplish this, laser, ultrasonic,

and pneumatic lithotripters are used according to the availability of surgical equipment.

After surgery, clinical laboratory assessment of the urinary stones is typically conducted. Laboratory assessment is geared to identify stones by their primary mineral content, using methods destructive to the stones. Knowing the mineral composition of a patient's stones

has obvious value in determining a treatment plan. It has long been appreciated that there is variability in stone fragility to shock waves in lithotripsy, and that stones of a given mineral type do not all break in the same way.⁽²⁾ Apart from mineral composition, we have limited information regarding the postoperative stone analysis that determines the stone structure.

The purpose of this study was to use micro-computed tomography (micro-CT) as a potential method for observing ultrastructural characteristics of stones removed by PNL and USS. Therefore, the effects of ultrasonic or pneumatic lithotripters on the stone structure will be evaluated.

MATERIALS AND METHODS

Study Design

Patients with renal or ureteral stone diagnosis that were recommended one of the endoscopic stone surgery techniques were included in this study. The patients who had previous urinary stone history, previous stone therapy, urinary tract infection, or active hematuria were excluded from the study.

Disease-specific history, physical and urogenital examinations, and pre-operative blood and urine tests were performed in all the patients. The urinary system was evaluated by ultrasonography, intravenous pyelography, and stone sequence spiral CT without contrast when necessary.

Renal stones were treated with PNL using the ultrasonic lithotripsy, and ureteral stones were treated with USS using the pneumatic lithotripsy. The EMS Swiss Lithoclast[®] Master device (A.K.A. Swiss Lithoclast Ultra, Natick, US) was used for ultrasonic and pneumatic lithotripsy. Simultaneous application of ultrasonic and pneumatic lithotripsy was not performed. The number and location of the stones were recorded. The stone removal technique was standardized for each group. The grouping was done with respect to lithotripsy technique. The power of ultrasonic lithotripsy and frequency of pneumatic lithotripsy were standardized in each group. Ultrasonic or pneumatic probes were touched

on the stone surface up to achieving the stone fragmentation in each group. The complete stone fragmentation by lithotripters was defined as destruction of the stone up to 2 to 3 mm.

After removal of the stones, the stones were divided into three groups and investigated by micro-CT: Group I, PNL and ultrasonic lithotripsy; group II, USS and pneumatic lithotripsy; group III (control group), USS or PNL without lithotripsy.

After operations, the mineral composition was analyzed by micro-CT, following the stone mineral analysis for each stone. Calcium oxalate monohydrate stones were just included to provide homogeneous groups. Therefore, the homogeneous stone composition was provided to compare the effect of each lithotripsy technique. The other types of mineral compositions were excluded from the study. Chi-square test was used to evaluate the difference statistically ($P < .05$).

Investigation Technique

All samples were scanned using a desktop x-ray microfocus CT scanner (SkyScan 1174, SkyScan, Aartselaar, Belgium) at Hacettepe University, Faculty of Medicine, Department of Anatomy (Figure 1). Micro-CT scanning technique was applied to the stones extracorporeally. Scanning time was 60 to 120 minutes. The scanning procedure was completed using 50 kV x-ray tube voltages, 800 μ A anode current. There were 120 panoramic .tiff images with 3 degree rotation step, resulting in a pixel size of 10 to 18 μ m. These digital data were further elaborated by a

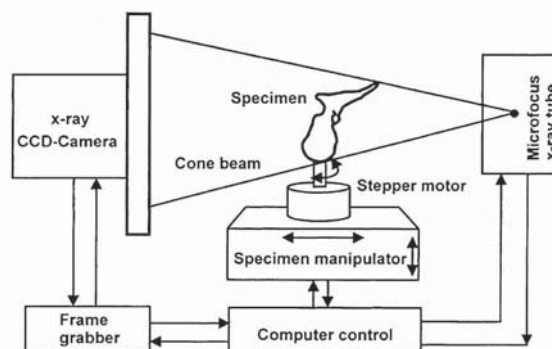


Figure 1. X-ray microfocus CT scanner (SkyScan 1174, SkyScan, Aartselaar, Belgium).

reconstruction software (NRecon) for attenuation measurement and 3D model creative software (CTan) for surface rendering. SkyScan 1174 has a spatial resolution of 6 to 30 μm (voxel size). The images were averaged over 3 to 4 frames.

The terminology of the results were criticized in accordance with the study by Zarse and colleagues.⁽²⁾ The evaluated parameters with micro-CT were presence or absence of homogeneity, heterogeneity, fragility, and internal voids in ultrastructural body of stones. Homogeneous pattern was accepted as a smooth type, which could be broken difficult, while heterogeneous pattern was accepted as a rough type that could be broken easily. Therefore, heterogeneity was accepted as a predictor of fragility.

RESULTS

There were a total of 24 “calcium oxalate monohydrate” stones from 24 patients scanned with micro-CT. The mean age of the patients for groups I, II, and III was 55, 48, and 44 years, respectively. The stone number in each group was 8. Mean stone volume was 22, 9, and 4 mm for groups I, II and III, respectively.

Each stone was completely fragmented before removal from the collecting system. The analyzed stone volume was similar in each group. Six renal stones were in the lower, 3 in the middle, and 2 in the upper calyceal system. Of ureteral stones, 5 were in the upper, 4 in the middle, and 4 in the

lower ureter. In ultrasonic lithotripsy, sudden fragmentation of stones was seen during surgery while in pneumatic lithotripsy, stepwise split of stones was seen.

We observed that heterogeneity might be a predictor of stone fragility because of apatite crystals and radiolucent voids, and it facilitated stone comminution. The number of heterogeneous stones was significantly higher in group I than group II ($P = .02$). Therefore, the stones treated with ultrasonic lithotripsy (group I) might be more fragile, fragmented, and cracked than those treated with pneumatic lithotripsy (group II; $P = .01$). Stones treated by pneumatic lithotripters were more homogeneous and smooth than those in group I, while they were similar to control group ($P = .02$). CTAn software showed homogeneous and visible voids in stones (Figure 2) and heterogeneous and rough calculi (Figure 3).

DISCUSSION

Recently, treatment of urinary stones with minimally invasive technology, including extracorporeal shock wave lithotripsy and ureteroscopic and percutaneous procedures, has been gaining popularity. For renal stones larger than 1 cm, intracorporeal lithotripsy using ultrasonic and pneumatic lithotripters is performed.⁽³⁾ Ultrasonic lithotripsy through a rigid scope is used for large renal stones. It has been shown that ultrasonic lithotripsy is preferred by urologists when using rigid scopes because of

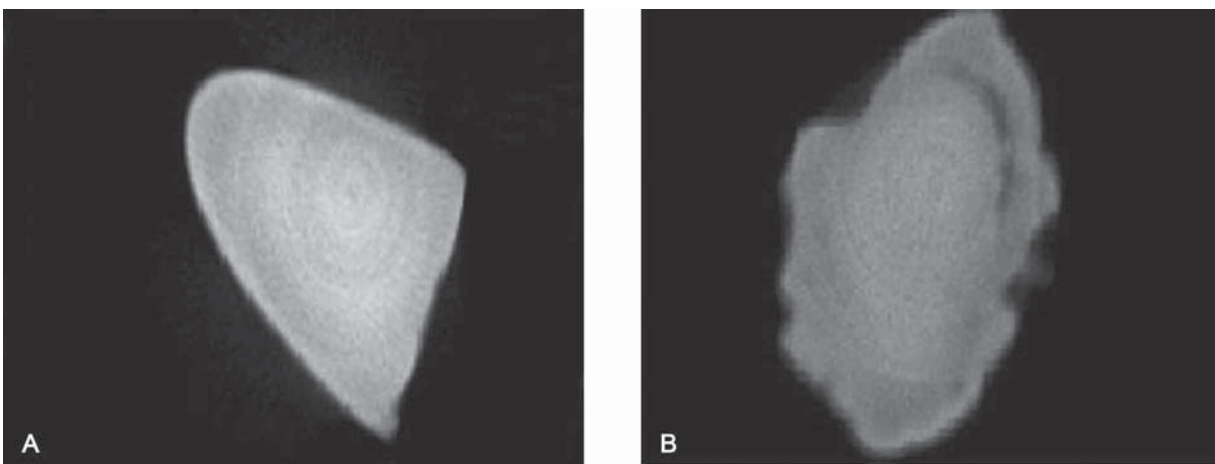


Figure 2. Homogeneous pattern (A) and visible voids (B) in stone piece: CTAn software.

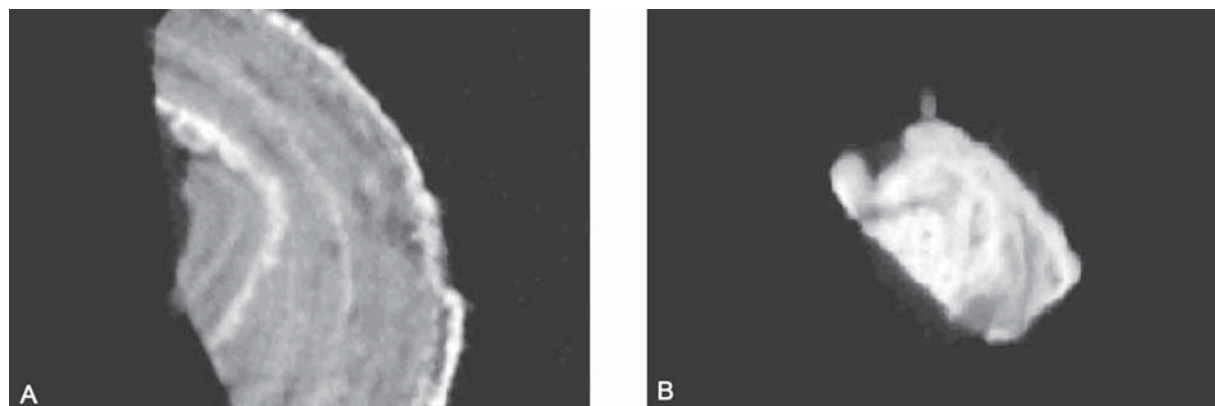


Figure 3. Heterogeneous (A) and rough (B) stone pieces: CTAn software.

its high fragmentation rate and 94% postoperative stone-free rate.⁽⁴⁾ However, pneumatic lithotripsy yields the minimum amount of urothelial injury, and is considered amongst most competent forms of intracorporeal fragmentation.⁽³⁾ In our clinic, we generally prefer to use the ultrasonic lithotripter during the PNL and pneumatic lithotripter during USS. Therefore, procedure selection was done according to our clinical application.

Many studies have been performed regarding the efficacy of intracorporeal lithotripsy during urinary stone surgery. Gurbuz and colleagues demonstrated that pneumatic lithotripsy was highly effective in the treatment of impacted ureteral stones.⁽⁵⁾ Zhu and associates compared the efficacy and safety of PNL with different intracorporeal lithotripters for proximal ureteral stones in patients with severe hydronephrosis. They demonstrated superior outcomes with shorter operation time using the Swiss Lithoclast Master (dual modality of ultrasonic and pneumatic lithotripsy) compared with pneumatic lithotripsy.⁽⁶⁾ Lowe and Knudsen also demonstrated that dual-modality lithotripters offered superior efficiency compared to separate ultrasonic and pneumatic lithotripters.⁽⁷⁾

During our research in PubMed, we did not find any articles regarding the evaluation of the ultrastructural effect of lithotripters on the urinary stones with micro-CT. Micro-CT produces high resolution in vitro imaging of the urinary tract calculi for nondestructive stone analysis. Fine resolution together with

the 2D and 3D reconstruction capabilities of micro-CT produces diagnostic studies with outstanding images of surface and internal stone structure.⁽²⁾ Mineral deposition pattern presents the type of stone with non-overlapping ranges of attenuation value, while the regions of potential structural weakness, such as voids, demonstrate the ultrastructural physical features inside the stone.⁽²⁾ The use of micro-CT for determination of mineral composition of stones is an important step toward the use of helical CT to provide similar analysis and help the urologist evaluate appropriate treatment options.⁽⁸⁾ We standardized the mineral composition among the groups; therefore, the evaluation was just focused on the stone structures.

Today, micro-CT could be just used in extracorporeal fashion after the operation. Hence, this feature limits the effectiveness pre-operatively. However, according to the aim of our study, pre-operative application of micro-CT is not necessary. In our study, we determined the difference in stone fragility among groups which had the same mineral composition. The degree of stone fragility triggered by intracorporeal lithotripsy was significantly greater using ultrasonic rather than pneumatic lithotripsy, as detected by micro-CT.

Bhatta and colleagues reported that cystine stones with a “rough” morphology (having large, blocky crystals on their surface) broke more easily with shock waves than those with “smooth” morphology (smaller crystals on the surface).

⁽⁹⁾ It has been stated that the roughness of the

surface cannot be evaluated at diagnosis.⁽¹⁰⁾ Kim and associates showed that rough cystine stones possess void regions within them that make them distinctive by helical CT.⁽¹¹⁾ Consistent with the literature, we confirmed increased stone fragility in group I, with highly relevant radiolucent void and heterogeneous rough surface on micro-CT. In pre-operative evaluation with helical CT, to obtain accurate attenuation measurements, narrow slice widths must be used, and bone view should be used to show minor components and apparent homogeneity.⁽⁸⁾ However, parallel to this knowledge, we increased the scanning period up to 2 hours to examine detailed ultrastructural features of the stones with micro-CT.

Zarse and coworkers demonstrated that calcium oxalate monohydrate stones that showed visibly heterogeneous structure on CT were more fragile to shock waves than calcium oxalate monohydrate stones that appeared to be homogeneous in their structure.⁽¹⁾ Irregularities in the structure of the stone could act as sites for focusing of shock waves energy;⁽¹²⁾ hence, the stone might break easily. In our study, the criteria of stone fragility related with homogeneity or heterogeneity was based on these parameters, which were in accordance with the literature. Up to now, the effect of shock waves on urinary stones was studied in vitro or in vivo by micro-CT or helical CT. To the best of our knowledge, this is the first report regarding ultrastructural analysis of stones applied to evaluate the use of ultrasonic or pneumatic lithotripsy in endoscopic stone surgery.

Micro-CT yields excellent high resolution analysis of the stone structure. It is a relatively fast method, taking approximately 1 to 2 hours for a complete 6 to 12 μm slice scan of a urinary stone that is 1 cm in diameter.⁽²⁾ Furthermore, micro-CT allows nondestructive mapping of the internal and surface structure of urinary stones and permits identification of mineral composition based on x-ray attenuation values. Six common stone minerals were found to occupy non-overlapping ranges of attenuation value, allowing identification of mineral types using micro-CT alone.⁽²⁾

The main target in urinary stone surgery is to break and remove the stone from the urinary system. The variability in stone fragility may be

related to the differences in stone structure.^(13,14) To support this hypothesis, Leger and colleagues reported that stones that were highly organized in their crystalline structure broke more easily than those that were less organized.⁽¹⁵⁾ Additionally, Williams and coworkers hypothesized that the presence of voids and/or apatite regions could correlate with altered matrix protein content on micro-CT evaluation.⁽¹⁶⁾ We detected apatite crystal significantly higher in group I, which may be related with increased fragility.

The stone size could not be optimized for this study. In our clinical practice, we used the ultrasonic power for high volume stones during PNL and pneumatic lithotripsy in ureteroscopic surgery. The optimized stone may give standard results comparing these two techniques.

This study seems to be the first basic research regarding the use of micro-CT in the urinary stones which were removed by endoscopic stone surgery. The clinical pre-operative application of micro-CT is not possible; however, two types of lithotripters were considered with micro-CT regarding their effects on the stone structure basically. We observed that ultrasonic lithotripters increase the stone fragility. However, further randomized controlled studies are required to evaluate exact effect of lithotripters on the stones located in each part of the urinary tract.

CONCLUSION

Intracorporeal lithotripsy is a very important tool to deal with urinary stones during endoscopic stone surgery. Micro-CT is a simple, easy, and feasible method to evaluate stone structure. Ultrasonic lithotripsy might be a predictor of stone fragility, as can be proven by heterogeneity; however, the stones which are destroyed by pneumatic lithotripsy have a homogeneous and smooth surface. Our future goal is to verify the micro-CT findings of the stones surface and internal structure with the material analysis probe of scanning electron microscope.

CONFLICT OF INTEREST

None declared.

REFERENCES

1. Zarse CA, Hameed TA, Jackson ME, et al. CT visible internal stone structure, but not Hounsfield unit value, of calcium oxalate monohydrate (COM) calculi predicts lithotripsy fragility in vitro. *Urol Res.* 2007;35:201-6.
2. Zarse CA, McAteer JA, Sommer AJ, et al. Nondestructive analysis of urinary calculi using micro computed tomography. *BMC Urol.* 2004;4:15.
3. Hanson K. Minimally invasive and surgical management of urinary stones. *Urol Nurs.* 2005;25:458-65.
4. Leveillee RJ, Lobik L. Intracorporeal lithotripsy: which modality is best? *Curr Opin Urol.* 2003;13:249-53.
5. Gurbuz ZG, Gonen M, Fazlioglu A, Akbulut H. Ureteroscopy and pneumatic lithotripsy, followed by extracorporeal shock wave lithotripsy for the treatment of distal ureteral stones. *Int J Urol.* 2002;9:441-4.
6. Zhu Z, Xi Q, Wang S, et al. Percutaneous nephrolithotomy for proximal ureteral calculi with severe hydronephrosis: assessment of different lithotriptors. *J Endourol.* 2010;24:201-5.
7. Lowe G, Knudsen BE. Ultrasonic, pneumatic and combination intracorporeal lithotripsy for percutaneous nephrolithotomy. *J Endourol.* 2009;23:1663-8.
8. Zarse CA, McAteer JA, Tann M, et al. Helical computed tomography accurately reports urinary stone composition using attenuation values: in vitro verification using high-resolution micro-computed tomography calibrated to fourier transform infrared microspectroscopy. *Urology.* 2004;63:828-33.
9. Bhatta KM, Prien EL, Jr., Dretler SP. Cystine calculi—rough and smooth: a new clinical distinction. *J Urol.* 1989;142:937-40.
10. Kim SC, Burns EK, Lingeman JE, Paterson RF, McAteer JA, Williams JC, Jr. Cystine calculi: correlation of CT-visible structure, CT number, and stone morphology with fragmentation by shock wave lithotripsy. *Urol Res.* 2007;35:319-24.
11. Kim SC, Hatt EK, Lingeman JE, Nadler RB, McAteer JA, Williams JC, Jr. Cystine: helical computerized tomography characterization of rough and smooth calculi in vitro. *J Urol.* 2005;174:1468-70; discussion 70-1.
12. Cleveland RO, Tello JS. Effect of the diameter and the sound speed of a kidney stone on the acoustic field induced by shock waves. *Acoustics Research Letters Online.* 2004;5:37-43.
13. Dretler SP. Stone fragility—a new therapeutic distinction. *J Urol.* 1988;139:1124-7.
14. Dretler SP, Polykoff G. Calcium oxalate stone morphology: fine tuning our therapeutic distinctions. *J Urol.* 1996;155:828-33.
15. Leger P, Daudon M, Magnier M. [In vitro test of piezoelectric lithotripsy with ultrasound detection using an EDAP LT 01 lithotripter]. *J Urol (Paris).* 1990;96:353-64.
16. Williams JC, Jr., Zarse CA, Jackson ME, Witzmann FA, McAteer JA. Variability of protein content in calcium oxalate monohydrate stones. *J Endourol.* 2006;20:560-4.