

A New Anatomical and Surgical Landmark in Internal Abdominal Oblique Muscle

Fat Triangle

Kazem Madaen,¹ Behrooz Niknafs²

¹ Department of Urology, Faculty of Medicine, Tabriz University of Medical Sciences, Tabriz, Iran

² Department of Anatomical Sciences, Faculty of Medicine, Tabriz University of Medical Sciences, Tabriz, Iran

Corresponding Author:

Behrooz Niknafs, Anatomical PhD
Department of Anatomical Sciences, School of Medical Sciences, Tabriz University of Medical Sciences, Tabriz, Iran

Tel: +98 411 386 2062
Fax: +98 411 334 2086
E-mail: niknafsbeh@yahoo.com

Received April 2011
Accepted August 2011

Purpose: To determine the anatomical landmark within the internal oblique muscle.

Materials and Methods: In a prospective study, the abdominal wall was examined for internal oblique muscle landmarks in 900 patients undergoing laparotomy.

Results: There was a fat line at anterior superior iliac spine level to access the underlying layers and then to the abdominal cavity.

Conclusion: A fat triangle within the internal oblique muscle provides a suitable region of surgical incision at the lower part of the abdominal wall.

Keywords: abdominal muscles, abdominal wall, adult, diagnosis

INTRODUCTION

Internal oblique muscle is one of the abdominal layers, which is located deep to the external oblique muscle, and leads to intra-abdominal cavity. The internal oblique muscle must be incised to approach the abdominal cavity either through intra-peritoneal or retro-peritoneal spaces.

Repair of the abdominal wall is important after a surgery. Current anatomy and surgery textbooks put little or no emphasis on a landmark or a particular region for incision through the internal oblique muscle.⁽¹⁻⁴⁾ The incision must be made without cutting any muscle fibers or damaging the nerves and vessels.

The aim of this study was to determine the anatomical landmark within the internal oblique muscle based on the identifiable bony landmark, the anterior superior iliac spine (ASIS). This surgical site is an easy way to go underneath the abdominal layers and can be used in different surgical applications. This landmark can be used in the repairs and incisions of the internal oblique muscle

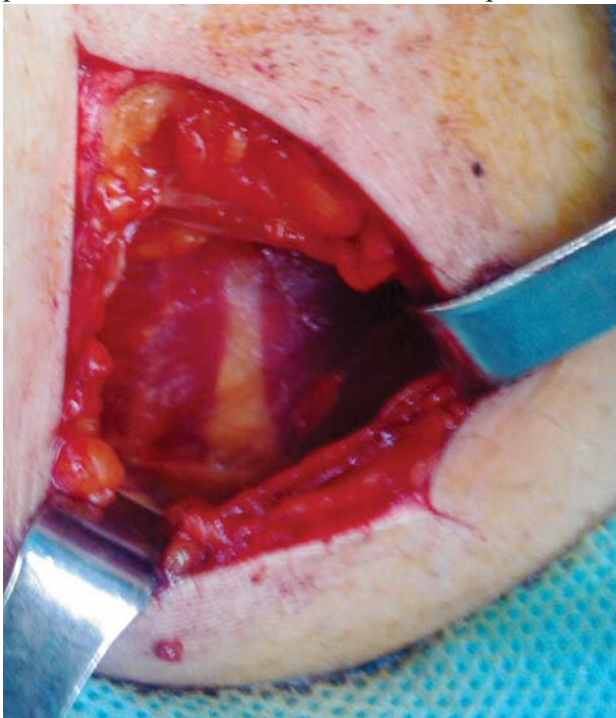


Figure 1. Anterior abdominal wall showing the external surface of internal oblique muscles. The fat triangle is seen at the anterior superior iliac spine level.

with little damage.

MATERIALS AND METHODS

The abdominal wall was exposed by dissection in 900 patients undergoing laparotomy. Transverse or para-umbilical incisions were made on 1/4 of the lower anterior abdominal wall at the ASIS level. The skin, subcutaneous fat, and external oblique aponeurosis were incised on the line between ASIS and midline. Thereafter, the muscle was dissected easily through the fat triangle. Deep to the fat triangle, the transverse abdominis and other layers were incised to approach abdominal cavity. The margins of the fat triangle were ligated after completing the surgery.

The surgical dissection exposed the underlying internal oblique muscle, which was precisely studied.

RESULTS

Within the internal oblique muscle, a fat line was identified at ASIS level to approach the underlying layers and then to the abdominal cavity. The line was extended from ASIS at lateral to lateral border of the rectus abdominis sheath in a triangle shape. The base of the fat triangle was located adjacent to the lateral border of the sheath. The fat triangle was observed on both the left and right sides of the subjects.

The width and size of the fat triangle were more prominent in obese patients than the thin ones. Furthermore, no blood vessels and nerves were identified within the fat triangle (Figures 1 and 2).

DISCUSSION

In this study, a fat triangle was found within the internal oblique muscle as a new landmark. This triangle can be recognized by bony landmark at ASIS level and used to access the abdomen without any severe damage to the abdominal wall. To the best of our knowledge, the fat triangle as anatomical or surgical landmark has not been addressed previously. This anatomical landmark has attracted more attention from surgeons than

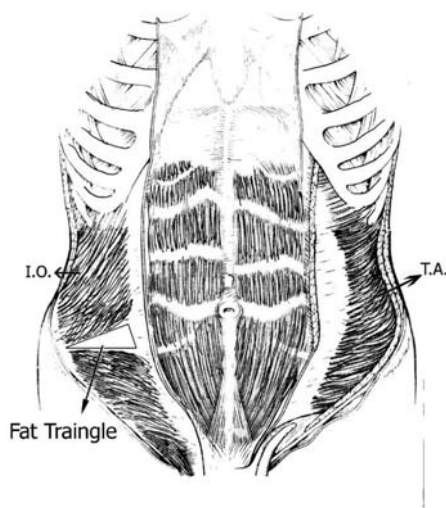
anatomists.

According to insertion point of the muscle, the internal oblique muscle can be divided into three parts; cranial, middle, and caudal parts. The cranial part is inserted into the inferior border of the last three ribs. The middle part continues transversally and medially to become aponeurotic, and then reach the linea alba. The caudal part ends on inguinal ligament.⁽⁵⁾ It seems that the fat triangle was constructed by a space between the caudal and middle parts of the internal oblique muscle, which was filled by the fat tissue. This gap naturally appeared between fleshy fibers of the internal oblique muscle.

There are three requirements for proper abdominal incision: 1) accessibility; 2) extensibility; and 3) security. The incision should be long and wide enough for a good exposure.⁽⁶⁾ This fat triangle has enough length and provides safe dissection plan. Furthermore, surgeons must take care to split muscles in the direction of their fibers rather than transect them.⁽⁶⁾ This splitting can be done bluntly through the fat triangle. In addition, the abdominal wall consists of eight layers, below the level of the ASIS, which are important in surgical preparations and repairs. The fat triangle as a critical guidance might prevent the damage to the layers.⁽²⁾

Since the fat triangle was devoid of any nerves and blood vessels, it was supposed to be an ap-

Figure 2. Schematic illustration of the position of the fat triangle. IO indicates internal oblique muscle; and TA, transversus abdominis.



propriate region to cut the muscle and get to the deep layers without any damage to the nerves. For instance, the iliohypogastric nerve innervates caudal part of the internal oblique muscle except cremasteric part.⁽³⁾ Surgical care must be taken not to sever the nerve as this causes motor paralysis in the segments of the abdominal muscle that they innervate, and subsequently weakness in the abdominal wall. Therefore, manipulating the fat triangle was safe to sever the probable nerves.

CONCLUSION

We concluded that the fat triangle within the internal oblique muscle as a landmark provides a good region of surgical incision at lower part of the abdominal wall. Surgical significances of the fat triangle include no muscle fiber cut, no bleeding, and no vessels and nerves injury. Furthermore, the surgical approach is easy through the internal oblique muscle.

CONFLICT OF INTEREST

None declared.

REFERENCES

1. Healy JC, Borley NR. Aboman and Pelvis In: Standing S, ed. *Gray's anatomy: The anatomical basis of clinical practice*. 39 ed. London: Elsevier Inc; 2005:1108-9.
2. Ramasastry SS, Futrell JW. Surgical anatomy of the internal oblique muscle: a practical approach. *Am Surg*. 1987;53:278-81.
3. Yang D, Morris SF, Geddes CR, Tang M. Neurovascular territories of the external and internal oblique muscles. *Plast Reconstr Surg*. 2003;112:1591-5.
4. Mahadevan V. Anatomy of the anterior abdominal wall and groin. *Surgery (Oxford)*. 2006;24:221-3.
5. Platzer W. Locomotor system In: Kahle W, Leonhardt H, Platzer W, eds. *Color Atlas and Textbook of Human Anatomy*. Vol 1. 3 ed. New York: Thieme; 1986:86-7.
6. Skandalakis JE, Skandalakis PN, Skandalakis LJ. *Surgical Anatomy and technique: a pocket manual*. 2 ed: Springer Verlag; 2000:156-63.