

## Response to Cabazitaxel Beyond 20 Cycles in A Patient with Penile Metastasis of Prostate Cancer: A Case Report

Elif Atag<sup>1</sup>, Huseyin Salih Semiz<sup>1</sup>, Seher Nazli Kazaz<sup>1</sup>,  
Emine Burcin Tuna<sup>2</sup>, Ozhan Ozdogan<sup>3</sup>, Ozan Bozkurt<sup>4</sup>, Omer Demir<sup>4</sup>, Aziz Karaoglu<sup>1</sup>

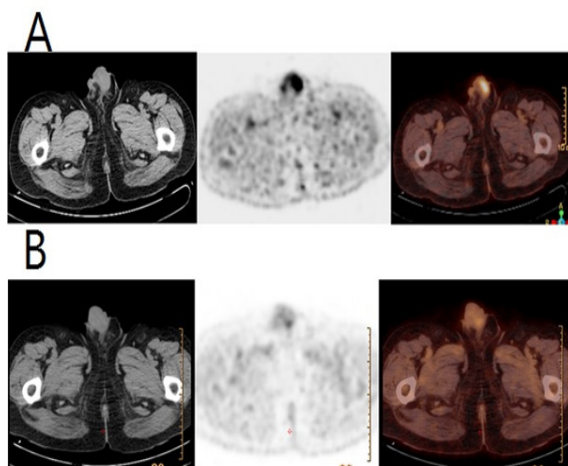
Penile metastases are extremely rare events and generally occurs at a late stage of primary disease. They mostly originate from prostate and bladder in the genitourinary tract. Penile metastases have a dismal prognosis and very low survival rates. We report a case of penile metastasis in 70-year-old geriatric male patient with prostatic adenocarcinoma who was treated with cabazitaxel chemotherapy beyond 20 cycles with a good response and acceptable minimal toxicity.

**Keywords:** cabazitaxel; penile metastasis; prostate cancer.

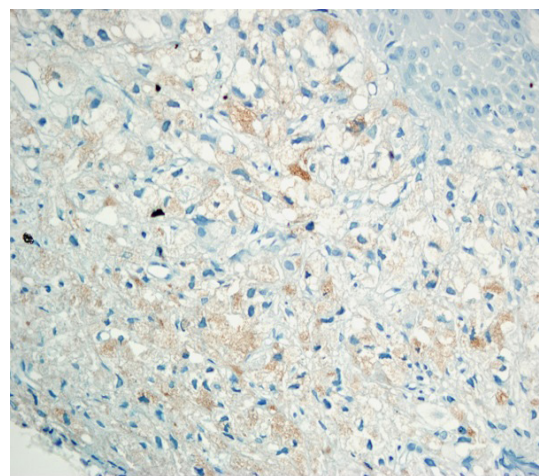
### INTRODUCTION

Despite the rich and complex vascularization of the penis, metastasis to the penis is a very rare event<sup>(1)</sup>. About 75% of the secondary penile tumors originate from the organs of the genitourinary tract. The most common primary malignancies which metastasize to penis are prostate and bladder carcinomas, followed by the rectosigmoid and renal carcinomas<sup>(2,3)</sup>.

Despite various treatment options, prostate cancer patients with penile metastasis still have a poor prognosis<sup>(4)</sup>. Median survival has been reported 6 months in patients with penile metastasis of prostatic cancer in the literature<sup>(1-3)</sup>. However in the last decade, treatment options for metastatic castration-resistant prostate cancer (mCRPC) have expanded with promising many new therapeutic agents. In this report, we present a case of prostate carcinoma spreading to the penis, who was treated with 21 cycles of cabazitaxel and had a good response with minimal toxicities.



**Figure 1. 1A:** Axial images of an Fluorine-18 FDG PET/CT show penile metastases before cabazitaxel treatment; **1B:** Axial images of an Fluorine-18 FDG PET/CT show response after 6 cycles of cabazitaxel treatment. (FDG PET/CT: Fluoro-deoxy glucose positron emission tomography-computed tomography)



**Figure 2.** Histopathological specimen of the penile skin. Tumor cells show PSA reactivation (x400)

<sup>1</sup>Dokuz Eylul University, Faculty of Medicine, Department of Medical Oncology, Izmir, TURKEY.

<sup>2</sup>Dokuz Eylul University, Faculty of Medicine, Department of Pathology, Izmir, TURKEY.

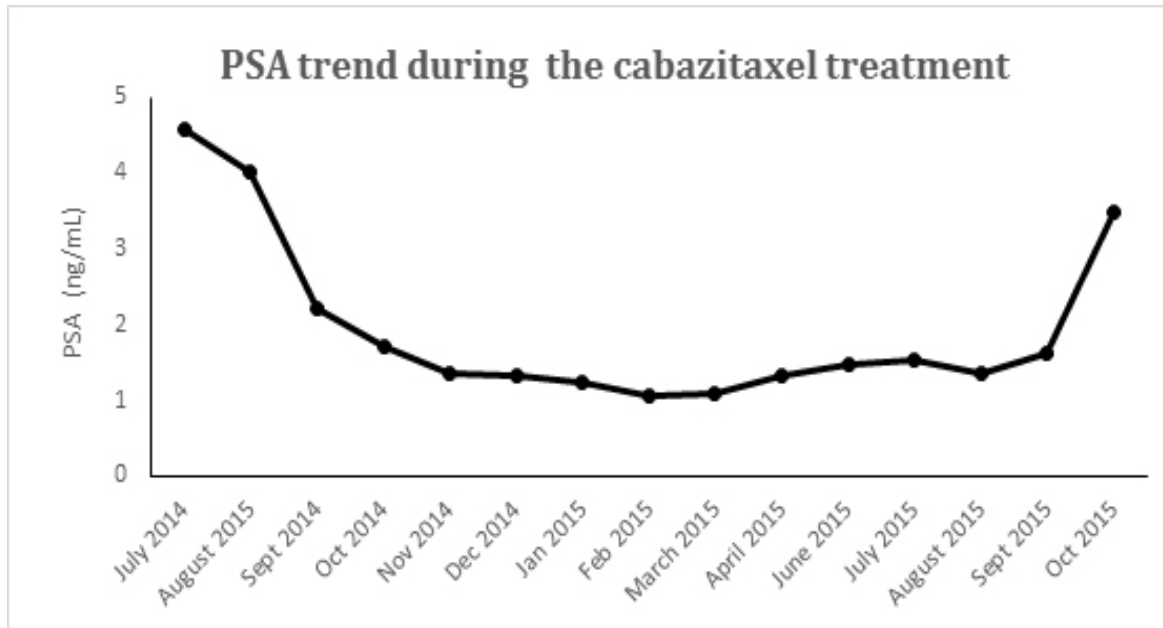
<sup>3</sup>Dokuz Eylul University, Faculty of Medicine, Department of Nuclear Medicine, Izmir, TURKEY.

<sup>4</sup>Dokuz Eylul University, Faculty of Medicine, Department Urology, Izmir, TURKEY.

\*Correspondence: Dokuz Eylul University, Faculty of Medicine, Department of Medical Oncology, 35210, Balcova, Izmir, TURKEY.

Tel: +90 232 412 48 01. Fax: +90 232 277 23 03. E-mail: elifatag@gmail.com.

Received September 2016 & Accepted December 2016



**Figure 3.** PSA levels during the cabazitaxel treatment.

### CASE REPORT

A 70-year-old man was diagnosed with stage 2A (pT1c-N0M0) prostate adenocarcinoma in 2001. Gleason score was 3+3 and serum prostate specific antigen (PSA) level was 14.2 ng/mL at that time. The patient was treated with definitive radiation therapy (RT) to the prostate-bed. After the RT, disease was stable for 4 years. In 2005, serum PSA level increased and anti-androgen therapy was started with bicalutamide 50 mg/day. PSA levels reduced below to the normal range (0-4 ng/mL). However, in January 2011 serum PSA level increased from 2.1 ng/mL to 6.7 ng/mL. Bicalutamide dose was increased to 150 mg/day. In January 2012, multiple bone metastases occurred and serum PSA level was 23.15 ng/mL. The patient was treated with intermittent subcutaneous injections of a luteinising hormone-releasing hormone agonist (goserelin 10.8 mg every 3 months), anti-androgen (bicalutamide 150 mg/day), and zoledronic acid (4 mg every 28 days). In November 2012, bone metastases progressed. The patient was diagnosed with mCRPC and docetaxel (75 mg/m<sup>2</sup> every 3 weeks) plus prednisone (10 mg/day) were started. Serum PSA level was decreased to 0.79 ng/mL and bone metastases were stable with six cycles of therapy. We gave three more cycles of docetaxel regimen and it was stopped at the ninth cycle due to adequate disease control. After the chemotherapy, bilateral orchiectomy was performed upon the patient's requisition in December 2013. In May 2014, PSA level was increased to 4.48 ng/mL and bone metastases progressed. Abiraterone acetate, a selective inhibitor of CYP17 enzyme was started. After two months, the patient was applied to the our clinic with painless reddish solitary nodules on the penis and mons pubis. Serum PSA level was increased to 4.57 ng/mL. 18F-Fluoro-deoxy glucose positron emission tomography-computed tomography (FDG PET/CT) scan revealed a linear line F-18 FDG uptake on the penis (SUV max: 5.8) and metastatic lesions on the bilateral pubic bones, right acetabulum, left ischial bone

(**Figure 1A**). A magnetic resonance imaging (MRI) showed a 3.5x6.5 mm dermal nodule on the dorsolateral region of the penis and a mass throughout the corpus spongiosum. He underwent to the skin biopsy from the lesion on the glans penis. Histological analysis revealed a poorly differentiated adenocarcinoma. Diffuse staining of the neoplastic cells with keratin and PSA at the immunohistochemistry demonstrated that the origin of the metastasis was prostate adenocarcinoma (**Figure 2**). The patient's Karnofsky performance status was 90 and cabazitaxel (25 mg/m<sup>2</sup> iv every 21 days) plus prednisone (10 mg/day) were started in July 2014. Patient also received primary granulocyte colony stimulating factor (G-CSF) prophylaxis after each cycle of cabazitaxel. PSA level was decreased to 1.33 ng/ml and most of the skin lesions disappeared after 6 cycles (**Figure 3**). FDG PET/CT scan showed a good partial response to therapy (SUV max: 3.1) (**Figure 1B**). Bone metastases were stable. The patient tolerated the cabazitaxel regimen with minimal toxicities. We decided to continue the cabazitaxel regime until progression or intolerable toxicity. After 12th cycle, PSA decreased to a nadir of 1.05 ng/mL and all skin lesions were disappeared. The treatment was well tolerated through 21 cycles. After 21 cycles, PSA level increased to 3.48 ng/mL, his imaging evaluations showed a progression of bone metastases, new pelvic metastatic lymph nodes and two skin lesions on the penis. Cabazitaxel therapy was stopped and a salvage chemotherapy regimen with weekly paclitaxel (80 mg/m<sup>2</sup>) was started, because patient still had a good performance status.

### DISCUSSION

In prostate cancer, penile metastasis is extremely rare, with an incidence of less than 0.3%<sup>(4)</sup>. Possible mechanisms of metastasis to the penis are direct invasion, implantation, dissemination through the blood stream or dissemination through the lymphatic ducts<sup>(5)</sup>. Typically, penile metastasis of prostate adenocarcinoma

presents a painless nodule as in our case. Kotake et al. have reported 25 cases with penile metastasis of prostate carcinomas and in their series, the main complaint of penile tumors were reported as penile nodule (80%), priapism (20%), painful erection (8%) and dysuria (4%). In the same study, penile metastasis appeared in castration-resistant period in 15 cases (60%) as in our case<sup>(6)</sup>. In the literature, there is also incidentally diagnosed penile metastasis with PET-CT in patients with no complaints. PET CT imaging was recommended as a noninvasive imaging technique for detection of the penile metastasis<sup>(7)</sup>. PSA is a reliable tumor marker that widely used in both diagnosis and follow-up for prostate cancer and typically correlate with tumor activity. However, patients with penile metastasis without PSA increase has been reported in the literature<sup>(8-10)</sup>. In this case serum PSA level was elevated when admitted with penile metastasis.

Current treatment options include local excision, partial or total penile amputation, androgen blockage therapy, radiotherapy and chemotherapy. Penile amputation is an undesirable option due to its negative psychological effects for the loss of sexual organ and operative complications. Therefore surgical therapy is generally recommended as an option after other treatments have failed. Radiotherapy is another effective treatment option reducing a lesion's size as well as improving patient's symptoms with limited side effects; however, it can cause ulceration of the glans penis and urethral strictures<sup>(2,6,7)</sup>.

Many systemic chemotherapeutic agents and regimens have used for treatment of penile metastases from primary prostate cancer until now. Vinorelbine, cyclophosphamide, estramustine, gemcitabine, mitomycin, carboplatin-based combinations have showed minimal efficacy without any survival benefit<sup>(7,9,11)</sup>. Despite all of these agents and treatment modalities, prognosis is poor in these patients and median survival time has been reported only 6 months<sup>(1,6,9,12)</sup>. To our knowledge, this case report is the first manuscript in the literature that showed a good response with systemic chemotherapy in penile metastasis from prostate cancer. In addition, this report describe firstly the role of cabazitaxel in this metastasis site. Cabazitaxel, a semisynthetic antimicrotubule agent derived from taxanes, is the first FDA-approved agent for second-line chemotherapy in mCRPC after treatment with docetaxel. In the phase III TROPIC trial, median survival was 15.1 months who received cabazitaxel arm compared with 12.7 months in mitoxantrone arm ( $P < .001$ )<sup>(13)</sup>. In our case, time to progression (TTP) was 14 months and overall survival was 25 months from July 2014 until June 2016 on the cabazitaxel therapy. In addition, we report a good tolerance to the cabazitaxel through the 21 cycles. Although our case was in geriatric age group, he reported minimal toxicities (grade 1 or 2) through cabazitaxel cycles. We didn't detected any neutropenic fever. Pivotal Tropic trial reported a high rate neutropenia (grade  $\geq 3$  82%) and neutropenic fever (8%). However the study had been allowed to use of prophylactic growth factor. Ozguroglu et al. reported that the appropriate and timely use of G-CSF reduces the occurrence of neutropenia in men receiving cabazitaxel<sup>(14)</sup>. Especially patients who have high risk factors need primary G-CSF prophylaxis. Therefore our patient received primary G-CSF prophylaxis.

In the Tropic study, the cabazitaxel chemotherapy duration was limited to 10 cycles because of a comparable exposure with mitoxantrone arm. But some small series and case reports suggested that beyond to 10 cycles of cabazitaxel chemotherapy can be given until progression with minimal toxicities. We administered 21 cycles of cabazitaxel chemotherapy without any severe myelosuppression or other toxicities. Pal SK et al. reported a 73-year-old prostate cancer patient could be received cabazitaxel therapy for a total of 24 cycles and they reported no toxicity in association with therapy<sup>(15)</sup>. In a case series, the toxicity profile of four CRPC patients who have been used over 10 cycles of cabazitaxel was reported. In this trial, Noronha et al. found that peripheral neuropathy was the only clinically significant toxicity associated with cumulative doses. Clinically significant neuropathy occurred after 15-17 cycles and it was partially reversible. Another remarkable case was recently reported by Lorenzo GD et al.<sup>(16)</sup> A patient who has metastatic CRPC had refused continuation of cabazitaxel beyond the 10th cycles despite showing response to treatment. Rapidly aggressive progression was developed and the patient died with hepatic failure two months after discontinuation cabazitaxel chemotherapy. Although there is no conclusive trial investigating the optimal duration of cabazitaxel therapy, it seems safe. In conclusion, penile metastasis of prostate cancer is very rare and it is associated with a poor prognosis. We report a successful treatment, using cabazitaxel chemotherapy in mCRPC with penile metastasis. The importance of our report is highlighting a few points. Firstly, a patient who has penile metastasis from prostate cancer was successfully treated. PSA decreased to a nadir of level and all skin lesions were disappeared. Secondly, we could use prolonged cabazitaxel chemotherapy with a good response until 21 cycles. Thirdly, we showed that cabazitaxel chemotherapy can be used for a long time with acceptable and manageable toxicities. Extended using of cabazitaxel chemotherapy has no increased toxicity profile. Lastly, our report suggested that extended cycles of cabazitaxel chemotherapy can be also used effectively and safely in geriatric patients.

## REFERENCES

1. Ansari H, Prashant R, Franks A. Prostatic carcinoma metastasis to the penis – an uncommon site. *Lancet Oncol* 2003;4:705-6.
2. Cante D, Franco P, Sciacero P, et al. Penile metastasis from prostate cancer: a case report. *Tumori*. 2014;100:14-6.
3. Chaux A, Amin M, Cubilla AL, Young RH. Metastatic tumors to the penis: a report of 17 cases and review of the literature. *Int J Surg Pathol*. 2011;19:597-606.
4. Tu SM, Reyes A, Maa A, et al. Prostate carcinoma with testicular or penile metastases. Clinical, pathologic, and immunohistochemical features. *Cancer*.2002;94:2610-7.
5. Abeshause BS, Abeshause GA. Metastatic tumors of the penis: A review of the literature and a report of two cases. *J Urol*. 1961;86:99-112.
6. Kotake Y, Gohji K, Suzuki T, et al. Metastases

- to the penis from carcinoma of the prostate. *Int J Urol*. 2001;8:83-6.
7. Spinapolice EG, Fuccio C, Rubino B, et al. Penile Metastases From Bladder and Prostate Cancer Detected by PET/CT: A Report of 3 Cases and a Review of Literature. *Clin Genitourin Cancer*. 2014;12:e155-9.
  8. Cai T, Salvadori A, Nesi G, et al. Penile metastasis from a T1b prostate carcinoma. *Onkologie*. 2007;30:249-52.
  9. Pierro A, Cilla S, Digesù C, Morganti AG. Penile Metastases of Recurrent Prostatic Adenocarcinoma without PSA Level Increase: A Case Report. *J Clin Imaging Sci*. 2012;2:44.
  10. Kobashi-Katoh R, Tanioka M, Takahashi K, Miyachi Y. Skin metastasis of prostate adenocarcinoma to glans penis showing no correlation with serum prostate-specific antigen level. *J Dermatol*. 2009;36:106-8.
  11. Powell FC, Venencie PC, Winkelmann RK. Metastatic prostate carcinoma manifesting as penile nodules. *Arch. Dermatol*. 1984;120:1604-6.
  12. Ghosh B, Dorairajan LN, Kumar S, Basu D. Penile nodule with inguinal lymphadenopathy: Prostatic adenocarcinoma masquerading as penile cancer. *Indian J Urol*. 2013;29:56-8.
  13. de Bono JS, Oudard S, Ozguroglu M, et al. Prednisone plus cabazitaxel or mitoxantrone for metastatic castration-resistant prostate cancer progressing after docetaxel treatment: a randomised open-label trial. *Lancet*. 2010;376(9747):1147-54.
  14. Ozguroglu M, Oudard S, Sartor A. O, et al. Effect of G-CSF prophylaxis on the occurrence of neutropenia in men receiving cabazitaxel plus prednisone for the treatment of metastatic castration-resistant prostate cancer (mCRPC) in the TROPIC study. *J Clin Oncol* 29: 2011 (suppl 7; abstr 1443).
  15. Pal SK, Stein CA. Prolonged therapy with cabazitaxel in an octogenarian with metastatic castration-resistant prostate cancer. *Clin Genitourin Cancer*. 2012;10:274-6.
  16. Di Lorenzo G, Buonerba C, de Placido S. Rapidly progressive disease in a castration-resistant prostate cancer patient after cabazitaxel discontinuation. *Anticancer Drugs*. 2015;26:236-9.
  17. Noronha V, Joshi A, Prabhash K. Beyond ten cycles of cabazitaxel for castrate-resistant prostate cancer. *Indian J Cancer*. 2014;51:363-5.