

Laser Treatment for Urethral Hemangiomas: Report of Three Cases

Mohammad Javad Soleimani, Pejman Shadpour*, Kaveh Mehravaran, Amir H Kashi

Keywords: hemangioma; laser; blood coagulation; urethra; recurrence

To present our experience with coagulation/laser treatment of urethral hemangiomas. Three cases with small to medium sized urethral hemangiomas in penile and posterior urethra presented with hematuria or urethral bloody discharge. All patients were male. They were treated with thermal or Holmium-YAG laser coagulation in the first session. Recurrence of hematuria/bloody discharge happened in two patients within one month from the first treatment that was managed with a second session of laser coagulation. No third session of intervention for hematuria/bloody discharge was required in any patient during 10-39 months of follow up. In cases of relapse after thermal or laser coagulation of small to medium sized urethral hemangiomas, after appropriate consultation with the patient, a second session of laser coagulation can be successful before contemplating more invasive measures like open surgery.

INTRODUCTION

Genitourinary hemangiomas are among the less common causes of hematuria or hematospermia⁽¹⁾. Urethral hemangiomas are very rare and most cases have been described in male patients⁽²⁾. By the end of 2008, the total number of reported cases was less than 30⁽³⁾. Most patients have presented in the second or third decade of life^(4,5). Until a decade ago, the advocated treatments for urethral hemangiomas were thermal or laser coagulation in case of small lesions and open surgery in case of large lesions or recurrence after initial endoscopic intervention^(1,5). Recently, transurethral resection and laser ablation of larger male urethral hemangiomas have been reported⁽²⁾. We report on our 3 patients with moderate sized urethral hemangioma who were endoscopically managed with coagulation and/or laser treatment.

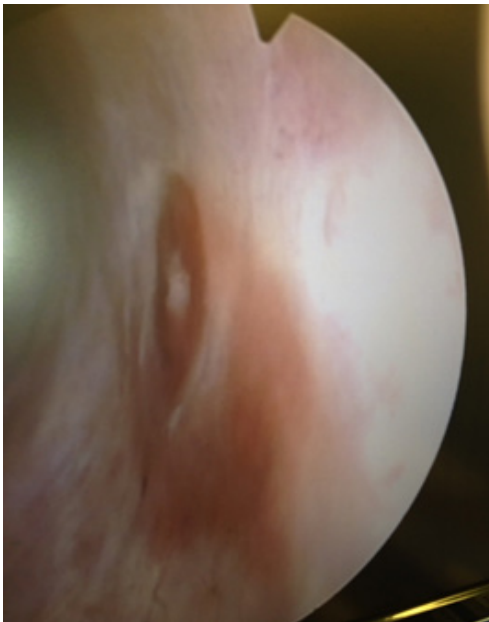


Figure 1. Hemangiomatous lesion in distal penile urethra.

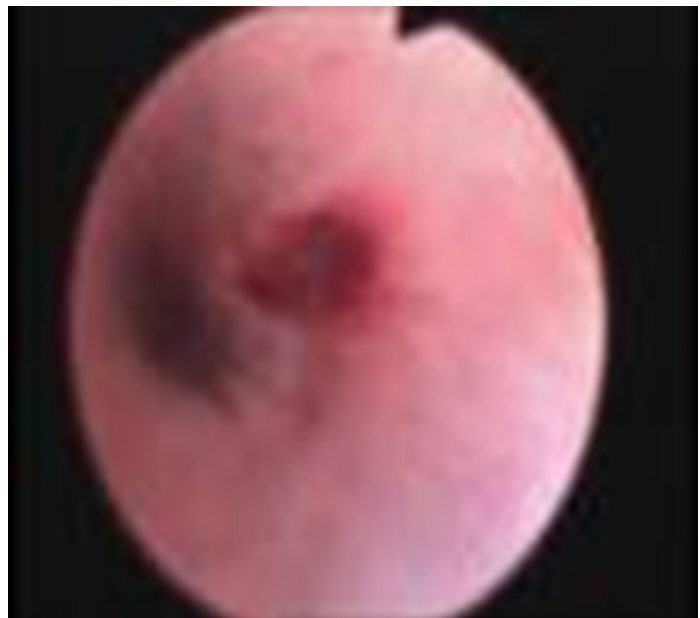


Figure 2. Hemangioma at 12 o'clock position (indented black arrow indicates 12 o'clock position)

Hasheminejad Kidney Center (HKC), Iran University of Medical Sciences (IUMS), Tehran, Iran. VanakSq, Tehran 19697, Iran.

*Correspondence: Hasheminejad Kidney Center (HKC), Iran University of Medical Sciences (IUMS), Tehran, Iran.

VanakSq, Tehran 19697, Iran .

Tel: 98 21 88644444. Fax: 98 21 88644447. pshadpour@gmail.com and shadpour.p@iums.ac.ir.

Received September 2016 & Accepted May 2017

CASE 1

A 41 year-old man presented with a 10 day history of hematuria and painless urethral bleeding. His physical examination was unremarkable, and prostate was less than 20 g in digital rectal examination. Laboratory examinations were normal except for isolated hematuria. Ultrasonographic evaluation of the urinary tract was normal. He was scheduled for cystoscopy during which, a 5 mm hemangioma was observed in the proximal penile urethra. (**Figure 1**) The lesion was coagulated using pin-point low-power monopolar electrocautery and the patient was discharged the day after surgery. He presented one month later with recurrent urethral bleeding. He underwent a second cystoscopy, blood clots were evacuated from urethra and the same hemangioma lesion was coagulated again with Holmium-YAG laser at 3 watts of energy. The patient was discharged on the first postoperative day and bleeding episodes have not recurred during 39 months of follow up.

CASE 2

A 22 year-old man presented with intermittent post-erection hematuria since 1 year before admission which had increased in severity within the preceding 1 month. Physical examination was unremarkable. Normal hemoglobin was observed in laboratory examinations. Other laboratory examinations were normal except for periodic hematuria. Ultrasonographic examination of the urinary tract was unremarkable. He underwent cystoscopy at which, a 10 mm hemangioma was observed in penile urethra at the 12 o'clock position. (**Figure 2**) The lesion was coagulated with Holmium-YAG laser at 2 watts. An 18 F urethral catheter was inserted to assist for temporary tamponade which was removed 2 days later. After 2 month, the patient was scheduled for cystoscopy because of recurrence in our previous case. During cystoscopy, no lesion was observed and the patient has not experienced hematuria during 19 months of follow up.

CASE 3

A 14 year-old male adolescent presented with chief complaint of painless bloody discharge from urethra lasting 5 days. Bloody discharge was occasionally massive leading to serum hemoglobin level below 7. The patient had unremarkable medical history including absence of lower urinary tract symptoms, urolithiasis, or flank pain. Physical examination was also unremarkable. Laboratory examinations were normal. Transrectal ultrasonography had been performed elsewhere which revealed normal prostate and seminal vesicles. He underwent cystoscopy which revealed a 1 cm hemangioma in the distal third of penile urethra from 3 to 5 o'clock positions and a 1.5 cm hamartomatous lesion 2-3 cm distal to the hemangioma. Both lesions were coagulated with laser at 3 watts energy. Two weeks later, the patient presented with hematuria recurrence. He was scheduled for cystoscopy and two small hemangiomatous lesions were observed obviously distal to the previously treated ones were coagulated at the second session with laser coagulation at 2 watts. A 16 F urethral catheter was inserted after coagulation which was removed on the 1st postoperative day. The patient has not experienced recurrent bleeding during 10 month

follow up.

DISCUSSION

The most common presentation for of urethral hemangioma is intermittent hematuria which is typically painless and sometimes massive⁽¹⁾. Bloody urethral discharge and hematospermia has been rarely reported. The classical diagnostic method for urethral hemangioma is cystoscopy, however this modality may underestimate the presence or extent of disease and pelvic MRI has been suggested to better delineate the extent of disease^(4,6,7). Cattolica et al. suggested that cystoscopy during penis flaccidity may miss these lesions which enlarge and become more visible during erection⁽⁸⁾. Saito and colleagues proposed that endoscopy immediately after ejaculation with reduced irrigation flow will increase the probability of diagnosing these lesions⁽⁹⁾. Currently, thermal or laser ablation has been reported for urethral hemangiomas which can be associated with incomplete ablation and relapse in some cases.⁽²⁾ Open surgery with urethral reconstruction has been advocated cases that have relapsed^(1,5). We presented a series of 3 patients managed by laser ablation of urethral hemangiomas. The laser device used in these patients was a pulsed low power Holmium-YAG laser device. The interesting point is that the majority of patients (2 out of 3) presented with recurrent bleeding after a first session of coagulation or laser treatment. Therefore, it seems wise to consult patients about the possibility of relapse as indicated by previous reports when laser or thermal coagulation is planned for urethral hemangiomas. Nevertheless, all patients in this series responded to a second session of laser coagulation with no subsequent substantial bleeding observed during follow up. No patient needed any further intervention after the second session of laser coagulation during a medium term follow-up (10 To 39 months). We performed follow up cystoscopy in cases of gross or microscopic hematuria or bloody discharge form the urethra.

There is the possibility of urethral stricture after any sort of urethral interventions. Patients should be consulted about this possibility and follow up be scheduled accordingly.

We think that as previously reported by Saito et al., the real prevalence of urethral hemangiomas can be higher than previously thought⁽⁹⁾. Careful examination of urethra during cystourethroscopy can reveal small easily overlooked lesions. This point will be of utmost importance when confronting a relapse of hematuria or urethral bloody discharge in a patient previously treated for urethral hemangiomas. Thorough investigation of the urethra is advised to identify any previously missed or newly surfaced hemangiomatous lesions.

CONCLUSIONS

In cases of relapse after thermal or laser coagulation of urethral hemangiomas there can be a choice of trying a second session of laser coagulation before resorting to open surgery after appropriate consultation with the patient.

CONFLICT OF INTERESTS

None declared.

REFERENCES

1. Parshad S, Yadav SP, Arora B. Urethral hemangioma. An unusual cause of hematuria. *Urol Int.* 2001;66:43-5.
2. Ongun S, Celik S, Aslan G, Yorukoglu K, Esen A. Cavernous hemangioma of the female urethra: a rare case report. *Urol J.* 2014;11:1521-3.
3. Han H, Zhou XG, Fan DD, Tian L, Zhang XD. An Unusual Etiology for Hematospermia and Treatments That Were Successful. *Urology.* 2015;86:740-3.
4. Manuel ES, Seery WH, Cole AT. Capillary hemangioma of the male urethra: case report with literature review. *J Urol.* 1977;117:804.
5. Roberts JW, Devine CJ, Jr. Urethral hemangioma: treatment by total excision and grafting. *J Urol.* 1983;129:1053-4.
6. Hayashi T, Igarashi K, Sekine H. Urethral hemangioma: case report. *J Urol.* 1997;158:539-40.
7. Stewart SB, Leder RA, Inman BA. Imaging tumors of the penis and urethra. *Urol Clin North Am.* 2010;37:353-67.
8. Cattolica EV. Massive hemospermia: a new etiology and simplified treatment. *J Urol.* 1982;128:151-2.
9. Saito S. Posterior urethral hemangioma: one of the unknown causes of hematuria and/or hematospermia. *Urology.* 2008;71:168.e11-4.