

Current Management of Advanced and Metastatic Renal Cell Carcinoma

M Hammad Ather,¹ Nehal Masood,² Tahmeena Siddiqui³

Introduction: Unresectable renal cell carcinoma (RCC) is a technically incurable condition. Historically, RCC is resistant to chemotherapy and radiotherapy. Cytokine therapy was until recently considered the mainstay of treatment. However, responses are modest. Improvement in the understanding of the biology of RCC, particularly the hereditary types, is providing the basis for novel therapeutic targets. Our aim was to review the clinical utility of various systemic agents and surgery in the management of advanced RCC and suggest practice guidelines in the light of current literature.

Materials and Methods: Evidence was collected by review of current literature, guidelines of the American and European associations and the national comprehensive cancer network.

Results: Treatment of advanced RCC has recently undergone a major change with the development of targeted agents and potent angiogenesis inhibitors. Small-molecule multikinase inhibitors that target vascular endothelial growth factor receptors have a favorable toxicity profile and can prolong time to progression and preserve quality of life when used in newly diagnosed or previously treated patients; bevacizumab enhances the response rate and prolongs disease control when added to interferon- α . Temsirolimus, a mammalian target of rapamycin inhibitor, prolongs the survival duration of patients with poor-risk disease. All currently available agents have variable toxicity profile and they, at best, improve survival by a few months. Surgery still has a significant role in the management of stage IV RCC.

Conclusion: Supportive care and surgery remain the mainstay of treatment even in the management of advanced and metastatic RCC. Systemic therapeutic agents are showing promising results.

Keywords: renal cell carcinoma, neoplasm metastasis, cytokines, vascular endothelial growth factor receptors

*Urol J. 2010;7:1-9.
www.uj.unrc.ir*

INTRODUCTION

The current estimate of renal cancer incidence is about 200 000 cases, making it the 3rd most common urogenital cancer worldwide.⁽¹⁾ In the United States, an estimated 51 190 patients were diagnosed with renal cell carcinoma (RCC) in 2007, and 12 890 would die of the disease.⁽¹⁾ Renal cell carcinoma comprises a histologically diverse group of solid tumors, together

making up about 3% of all adult neoplasms.⁽¹⁾ About one-third of patients have metastatic disease at presentation, a median survival of 7 to 11 months, and a 5-year survival of 10%. Its incidence has been increasing, a phenomenon for which wider use of imaging procedures alone cannot account.⁽²⁾

Renal cell carcinoma, if detected early, is potentially curable by

¹Department of Surgery, Aga Khan University, Karachi, Pakistan

²Department of Medicine, Aga Khan University, Karachi, Pakistan

³Department of Biochemistry, Karachi University, Karachi, Pakistan

Corresponding Author:
M Hammad Ather, FCPS (Urol), FEBU
Department of Surgery, PO Box: 3500
Stadium Road, Karachi 74800

Fax: +92 21 493 4294/2095
Tel: +92 21 486 4778
E-mail: hammad.ather@aku.edu

surgery; however, about one-third present with metastases and one-third of organ-confined cancers treated by nephrectomy develop metastases during the follow-up.⁽³⁾ If surgical extirpation alone for all tumor deposits is not possible, tumor nephrectomy remains a palliative therapy, considered for symptomatic control and as part of multimodality treatment (eg, in conjunction with immunotherapy or experimental therapies). Metastatic RCC is a difficult disease to manage, as it is resistant to chemotherapy and radiotherapy. Patients with metastatic disease have a median survival time of less than 12 months. However, survival can be quite variable, depending on several prognostic factors, including performance status; lactate dehydrogenase (LDH), hemoglobin, and calcium levels; and the absence of prior nephrectomy.⁽⁴⁾

Recent advances in immunotherapy protocols, development of targeted therapy with small-molecule kinase signal transduction inhibitors, vascular endothelial antibodies, and combination treatment modalities have shown promising trends. Rising incidence, improved imaging and other diagnostic procedures, and emerging role of multimodality therapeutic concepts justify the need for evidence-based guidelines for treatment of RCC. Particularly, the challenging aspect is the management of locally advanced and metastatic RCC. In the current review, we have tried to define patient selection, efficacy, and safety of some of the newer agents in the light of best evidence in the current literature.

PATHOGENIC PATHWAY

Renal cell carcinoma exists in 4 distinct histological subtypes. These include clear cell, papillary, chromophobe, and collecting duct tumors. The majority of cases (75%) are clear-cell RCC. These are characteristically associated with loss of function of the von Hippel-Lindau (*VHL*) gene. Latif and associates⁽⁵⁾ reported in a study of 221 *VHL* kindred a linkage analysis to identify the *VHL* gene on the short arm of chromosome 3p. The *VHL* gene product forms a complex with elongin C and B, which further binds to cul-2. This results in upregulation of the α -fragment of hypoxia inducible factor (HIF) subunits, HIF-

1 and HIF-2.⁽⁶⁾ The HIF activation results in upregulation of HIF target genes, such as vascular endothelial growth factor (*VEGF*), transforming growth factor, hepatocyte growth factor receptor (*MET*), stromal cell-derived factor-1, and others.⁽⁷⁾ The HIF plays an important role in RCC oncogenesis, but besides HIF deregulation, there are many other mechanisms and HIF alone is probably not sufficient to cause oncogenesis.⁽⁸⁾

A different histological subtype of RCC, ie, papillary type, is not associated with *VHL* gene at 3p, but with *MET* proto-oncogene at chromosome 7q31. The *MET* gene encodes a cell membrane receptor specific for hepatocyte growth factor. Studies have indicated that hepatocyte growth factor stimulation leads to mitogenesis, cellular migration, and morphogenesis.⁽⁹⁾

PROGNOSTIC INDICATORS

Renal cell carcinoma is a heterogeneous disease that is recognized based on differences in morphology, genetic alterations, and clinical behavior. In view of variable biological behavior and poor results of most therapies for advanced and metastatic RCC, it is important to have a universally acceptable prognostic model. Currently, some pathological factors are not covered by the TNM classification. The nonpathological factors such as performance status, thrombocytosis, and neutrophilia are also important. The predictors of short survival include serum LDH levels higher than 1.5 times upper limit of normal, low hemoglobin levels, corrected serum calcium levels higher than 10 mg/dL (2.5 mmol/L), a time interval of less than 1 year from original diagnosis to the start of systemic therapy, the Karnofsky performance score of 70 or lower, and 2 or more sites of organ metastases.⁽¹⁰⁾

Angiogenesis is a critical step in the growth, invasive progression, and metastatic spread of solid tumors. Recently, Minardi and coworkers⁽¹¹⁾ assessed the importance of tumor necrosis, microvessel density, vascular endothelial growth factor (VEGF), and HIF-1 α immunohistochemical expression in a large series of clear-cell RCCs treated with radical nephrectomy and assessed the prognostic value of their expression in terms

of patient survival in long-term follow-up. They noted that tumor necrosis, microvascular invasion and renal capsular infiltration are more likely to occur in higher stages and grades of RCC; cytoplasmic HIF-1 α is highly expressed in high-grade RCC. Survival is dependent upon tumor stage and grade, the presence of vascular invasion and capsular infiltration, and tumor necrosis. Microvessel density also resulted as being an important prognostic factor. Generally, VEGF and HIF-1 α correlate with prognosis in high-stage tumors and VEGF is the most important independent prognostic factor for cancer-specific death. The histological and immunohistochemical parameters considered here can influence disease recurrence and survival in RCC.

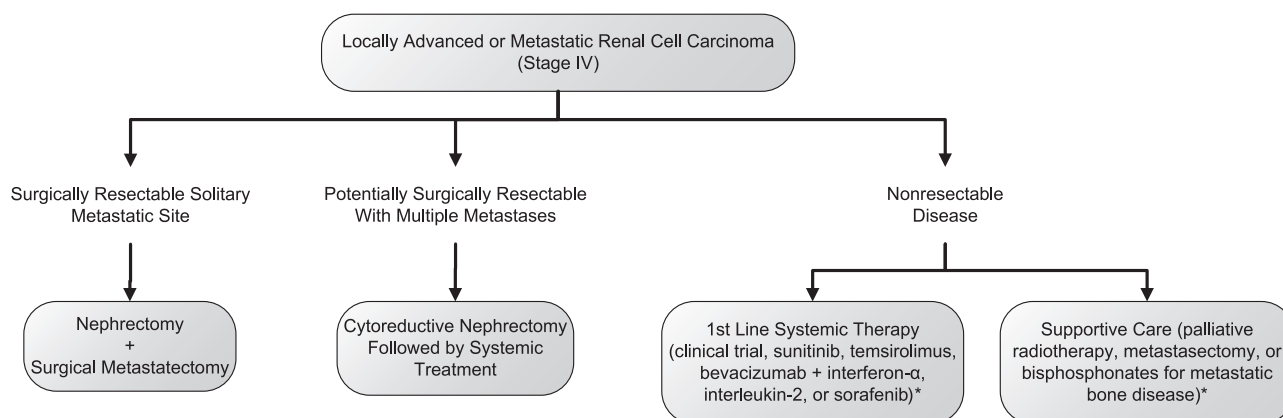
TREATMENT

Role of Surgery in Management of Advanced and Metastatic Renal Cell Carcinoma

Surgery has a significant role in the overall management of advanced RCC (Figure). Regional lymph node involvement on imaging may be reactive or hyperplastic only; therefore, surgical resection and pathological evaluation become important. In a recent report, Margulis and coworkers⁽¹²⁾ noted that true pathologic involvement of adjacent organs by RCC cannot be predicted from pre-operative or intra-operative parameters. A significant proportion of patients clinically suspected of having T4

RCC are downstaged and benefit from aggressive surgical resection with en bloc removal of the involved organs. Moshrafa and associates⁽¹³⁾ demonstrated that radical nephrectomy in the setting of metastatic RCC has a low morbidity and acceptable recovery in these patients with advanced primary tumors and poorer performance status. Patients with primary renal tumor and isolated metastatic site or with isolated metastatic recurrence benefit from surgical extirpation.⁽¹⁴⁾ Complete resection of either synchronous or metachronous solitary metastases from RCC is justified and can contribute to a long-term survival in this selected group of patients.

Nephrectomy in patients with advanced RCC prior to the introduction of effective systemic therapy was a palliative procedure without significant improvement in overall survival. With the introduction of immunotherapy, and more recently, molecularly targeted therapy, nephrectomy has shown to improve survival when performed before interferon (IFN) therapy in a selected group of patients. There is, however, lack of high level of evidence as to whether to remove the primary tumor prior to the targeted therapy or following it up. The initiation of a phase 3 study should be considered to compare the survival of patients treated by nephrectomy plus targeted therapy with the survival of patients treated by targeted therapy alone, with nephrectomy reserved for clinical indications, in order to answer these questions. Until evidence



Management algorithm of locally advanced and metastatic renal cancer (stage IV).

*The National Comprehensive Cancer Network practice guidelines for kidney cancer. 2008. Available from: <http://www.nccn.org>

from such a study becomes available to guide physicians, and without evidence to the contrary, cytoreductive nephrectomy should be considered, as it has shown a survival benefit, and should be used in appropriately selected patients with metastatic RCC receiving postsurgical systemic therapies.⁽¹⁵⁾ The Southwest Oncology Group trial on 8949 patients and the European Organization for the Research and Treatment of Cancer trial on 30 947 are two remarkable studies on the issue.⁽¹⁶⁻¹⁸⁾ Using an identical treatment protocol (designed by the former group), these trials provide the best information to date regarding the use of cytoreductive nephrectomy. Both trials demonstrated significantly longer overall survival in the groups randomized to nephrectomy before immunotherapy, and this benefit persisted across all study stratifications, including performance status, site of metastasis, and measurable versus nonmeasurable disease.

Immunotherapy for Metastatic Renal Cell Carcinoma

Renal cell carcinoma evokes immune response that occasionally results in spontaneous tumor regression.⁽¹⁹⁾ Spontaneous regression of metastatic RCC is a rare but well-documented event, most often involving pulmonary metastases; however, its incidence is about 0.1%.⁽²³⁾ Over the past several decades, in order to duplicate, an accentuated response of various immunomodulations have been attempted. These include specific and nonspecific stimulation of the immune system. Most of these therapies have shown antitumor activity; however, the most consistent results have been observed only with interleukin-2 (IL-2) and with IFN- α . These agents target various inherent immune defects in RCC. Particularly important are the qualitative and quantitative defects in dendritic cell function in RCC,⁽²⁰⁾ which result in inherent immune deficiency and tumor progression. Renal cell carcinoma also alters body's antitumor immunity by altering the T-cell function in cytokine production by T helper cells.⁽²¹⁾

Interferon- α Trials. Interferon- α is a glycoprotein produced in response to viral infections and foreign antigens. The postulated mechanisms

of action in RCC include immunomodulation, antiproliferative, and anti-angiogenic activities. Interferon- α is produced by macrophages and lymphocytes and induces several biological effects including immunomodulation, antiproliferation, and enhanced expression of cell surface antigens.

In phase 2 studies, recombinant IFN- α is reported to induce response to treatment of RCC in up to 29% of cases.⁽²²⁾ In a randomized controlled trial by the Medical Research Council renal cancer collaboration,⁽²³⁾ 335 patients were randomized into two groups to receive either IFN- α or medroxyprogesterone. In this intention-to-treat analysis, there was a significant advantage in overall survival for patients treated with IFN- α ($P = .02$). The median survival was 2.5 months more in this group. In another trial, 160 patients were randomized to receive a chemotherapeutic agent, vinblastine, or IFN- α versus vinblastine alone.⁽²⁴⁾ The authors noted a significant overall survival advantage of 7 months ($P = .005$) in the IFN- α arm. There was also a significant difference in the overall response rate (16.5% versus 2.4%; $P = .003$), complete response rate (8.9% versus 1.2%), and median time to disease progression (3 months versus 2 months; $P < .001$), all favoring IFN- α . Coppin and colleagues⁽²⁵⁾ performed a meta-analysis of 53 randomized controlled trials with over 6000 patients treated over a decade between 1995 and 2004. They noted that compared to control patients, those who received IFN- α had a 3.8 months of median improvement in survival ($P = .007$).

Interestingly, IFN- α , in spite of being one of the most commonly used agents until recently and often adopted as the control arm in comparative trials with new drugs, has never been approved in the United States for treatment of RCC.

Interleukin-2 Trials. Interleukin-2, a glycoprotein, produced in response to infections, is important in identifying self and foreign antigens. The antitumor action of IL-2 is not completely understood; however, it is postulated to have direct killing action by activated T cells and natural killer cells.⁽²⁶⁾

Various modes of delivery for IL-2, including intravenous and subcutaneous, have also been

studied, attempting to maximize efficacy and decrease the significant toxicities that can be associated with high-dose IL-2 therapy. The importance of dose intensity of IL-2 for patients with metastatic RCC was clarified in a National Institutes of Health trial that randomized patients to receive high-dose IL-2 (156 patients) or a dose that was 10 times lower (150 patients). There was a significantly higher response rate with high-dose IL-2 than with low-dose intravenous IL-2 (21% versus 13%), but no overall survival difference, and a higher morbidity, as anticipated.⁽²⁷⁾ This was confirmed in a multi-institutional phase 3 trial involving 192 patients with metastatic RCC randomized to receive intravenous high-dose IL-2 or subcutaneous low-dose IL-2 plus IFN- α . The response rate was significantly greater in patients treated with high-dose IL-2 (23.2% versus 9.9%). While there was no significant difference in overall survival (17 months versus 13 months), 7% of the patients were reported alive and disease free after 3 years of follow-up in the high-dose IL-2 arm versus none in the control arm. As expected, there were more grade 3 and 4 toxicities in the high-dose IL-2 arm, although treatment-related mortality was rare.⁽²⁸⁾ The authors concluded that high-dose IL-2 was an acceptable therapy for patients with little or no comorbidities and excellent performance status, for whom the possibility of long-term complete response is worth the complexity, risk, and acute toxicity of the treatment. How to best sequence or combine IL-2 with newer drugs is unknown.

Overall, in most reported series, toxicity is worse with IL-2-based therapy than with non-IL-2 therapy; however, most studies described IL-2 regimens as moderately to well tolerated by most patients.⁽²²⁾ Specific to IL-2, hypotension, cardiac toxicity, diarrhea, and fatigue increased when compared with IFN- α or other treatment arms. None of the trials studied in the meta-analysis by Hotte and colleagues⁽²⁹⁾ reported toxic deaths or quality-of-life changes. It is, however, important to understand that IL-2-based regimens are associated with significant toxicity, and the magnitude of this toxicity may be underestimated in clinical trials because of patient selection factors. Specialized centers have the expertise to manage and minimize the impact of these

toxicities.

In a meta-analysis of trials on IL-2 versus non-IL-2,⁽²⁹⁾ Hotte and colleagues noted that the response rates were higher in patients receiving IL-2-based regimens (range, 6.5% to 39%), compared with non-IL-2 controls (zero to 20%). All 6 trials that they included in their analysis reported mortality data, and when the 6 trials were pooled in a meta-analysis, mortality at 1 year was not significantly different between IL-2-based regimens and non-IL-2 regimens. Hotte and colleagues⁽²⁹⁾ concluded that non-high-dose IL-2 containing regimens do not provide superior treatment efficacy over non-IL-2-based regimens, with added toxicity, and therefore, should not be used as standard treatment for patients with unresectable or metastatic RCC. Rosenberg⁽³⁰⁾ showed that IL-2 is the only systemic treatment currently available that is capable of curing patients with metastatic RCC, albeit in smaller number of patients with unmaintained complete response.

Multikinase Inhibitors

Deregulation of HIF is an important aspect of RCC development. Thus, agents that affect HIF target genes, especially those encoding VEGF and VEGF receptors, may be particularly useful. Small-molecule kinase inhibitors that have more than one target (multikinase inhibitors) like sorafenib and sunitinib malate are being currently evaluated in many clinical trials. These agents have potent activities against specific kinases; however, the true biologic targets responsible for tumor regression are not precisely known.

The ability of solid tumors to invade and develop metastasis depends on angiogenesis. Targeted therapies, like multikinase inhibitors and anti-angiogenic antibodies, reduce tumor vascularity and induce tumor necrosis before a change in tumor size or volume is observed.⁽³¹⁾ Standard response end points based on unidimensional and bidimensional measurements, such as the Response Evaluation Criteria in Solid Tumors or the World Health Organization criteria, originally designed to evaluate cytotoxic drugs, do not accurately reflect changes in tumor volume, and therefore, often fail to accurately register

responses to targeted agents, which are typically cytostatics.⁽³²⁾ Imaging techniques that provide morphologic and functional perfusion data, such as Doppler ultrasonography with contrast agent injection,⁽²³⁾ may be combined with standard criteria to better assess the efficacy of targeted agents.

Sunitinib. Sunitinib malate is an orally administered inhibitor of a number of tyrosine kinases, including VEGF receptor and the platelet-derived growth factor receptor,⁽³³⁾ which are known to play a significant role in the pathogenesis of RCC through their involvement with the *VHL* gene. A recently published phase 3 randomized trial⁽³⁴⁾ reported the superior efficacy of sunitinib malate over IFN for patients with locally advanced unresectable or metastatic RCC who had had no previous systemic therapy. These results were based on the pooled analysis of 2 phase 2 studies of sunitinib for patients who had undergone previous cytokine therapy and had a response rate of 42%.⁽³⁵⁾

In a phase 3 study,⁽³⁶⁾ using IFN as a control for advanced RCC, 750 patients with clear cell histology without prior systemic therapy were randomized to receive either sunitinib or IFN. None of the patients had complete response, partial responses were observed for 31% of patients treated with sunitinib and 6% of those treated with IFN. The median progression-free survival was 11 months for patients in the sunitinib arm and 4 months for those in the IFN arm (hazards ratio, 0.42; 95% confidence interval, 0.33 to 0.52). All differences were highly significant. Subgroup analyses suggested that patients with various risk factors seemed to have similar benefits with sunitinib. When divided into good-, intermediate-, or poor-risk categories according to the Motzer criteria, patients in all the three categories that received sunitinib fared better than those who received IFN.⁽²⁵⁾ Although few patients were categorized in the poor-risk group (23 patients in the sunitinib group and 25 in the IFN group), the trend was toward improvement in median progression-free survival (4 months versus 1 month, respectively; hazards ratio, 0.53; 95% confidence interval, 0.23 to 1.23). Health-related quality of life measured in this

study was better in the sunitinib group than in the IFN group ($P < .001$). The results of this large phase 3 trial convincingly demonstrated that sunitinib was significantly better than IFN for previously untreated patients with advanced RCC and should be considered the new standard of care for first-line treatment of this disease.

Diarrhea and fatigue were the most commonly reported treatment-related adverse events of sunitinib, and other adverse events included stomatitis, hand-foot syndrome (characterized by painful lesions on the palms and soles), and hypertension.⁽³⁷⁾ Neutropenia was reported, but there were no reports of associated fever or sepsis.⁽³⁵⁾ Elevated serum concentrations of lipase were not associated with clinical signs or symptoms of pancreatitis.⁽³⁷⁾

Sorafenib. Sorafenib is an orally administered multikinase inhibitor that targets Raf kinase and receptor tyrosine kinases, including VEGF receptor-2 and platelet-derived growth factor receptor- β .⁽³⁶⁾ Sorafenib's antitumor activity is by targeting the tumor or tumor endothelium to inhibit proliferation and angiogenesis.^(38,39) In phase 2/3 trials, sorafenib significantly prolonged progression-free survival versus placebo and showed good tolerability in advanced RCC patients.⁽³⁷⁾ Based on these phase 2/3 RCC trial findings, sorafenib was approved recently for the treatment of advanced RCC. Sorafenib may be acting through inhibition of angiogenesis in RCC, but the precise mechanism of action by which sorafenib exerts its clinical effects, and the etiologic role of the Raf/MEK/ERK pathway, is undergoing further investigation in this tumor type.

In the Treatment Approaches in Renal Cancer Global Evaluation Trial, 903 previously treated patients with metastatic clear-cell RCC of low or intermediate risk, according to the Memorial Sloan-Kettering Cancer Center classification,⁽³⁹⁾ were randomized to receive sorafenib or placebo. The median progression-free survival times were 5.5 months in the sorafenib group and 2.8 months in the placebo group, and the objective response rates were 10% in the sorafenib arm and 2% in the placebo arm. Although the difference in survival favoring sorafenib was not significant, it may have

been because of early crossover allowed shortly after an interim analysis showed a difference in progression-free survival. Discontinuation of treatment because of side effects occurred in 10% of patients receiving sorafenib, and 13% required dose reductions because of toxicity. The most important side effects were diarrhea (43%), hypertension (17%), skin rash (40%), and hand-foot syndrome (30%).⁽⁴⁰⁾

Unlike the results for sunitinib, results for sorafenib do not justify its use as adjuvant in patients at high risk of recurrence following nephrectomy. Potential patients should be referred to centers participating in such trials.

Anti-angiogenic Therapy in Metastatic Renal Cell Carcinoma

The majority of RCCs have upregulation of the HIF and the resultant upregulation of target gene *VEGF*. Bevacizumab is a humanized recombinant anti-VEGF antibody that binds all types of VEGF-A isoforms.⁽⁴¹⁾ Bevacizumab was tested in a phase 2 trial of 116 patients with metastatic clear-cell RCC who were randomized to receive placebo or low-dose (3 mg/kg) or high-dose (10 mg/kg) bevacizumab, given every 2 weeks. There was a 10% objective partial response rate, which was confined to the high-dose arm. Compared with placebo, there was also a significantly longer time to disease progression (4.8 months versus 2.5 months).⁽⁴²⁾

Most recently, a phase 3 trial involving 641 patients with metastatic clear-cell RCC compared IFN- α combined with either bevacizumab or placebo. When compared with placebo, bevacizumab resulted in a significantly longer progression-free survival (10.2 months versus 5.4

months) and higher objective tumor response rate (30.6% versus 12.4%). In an interim analysis, there was no significant survival advantage. Common toxicities seen in this and previous trials were hypertension, proteinuria, and a tendency to bleeding and thrombotic events.⁽⁴³⁾

CONCLUSION

The grade of recommendation for the abovementioned treatment option is listed in the Table. Surgery still plays a significant role in the management of advanced and metastatic RCC. In a selected group of patients, resection of the primary tumor along with complete resection of solitary or limited metastases can lead to long-term disease-free or relapse-free survival. Nephrectomy before immunotherapy has been shown in phase 3 trials to result in a survival benefit in patients with good performance status and limited burden of disease, although the overall improvement in survival is modest. In patients with nonresectable disease or those with residual disease following maximal surgical extirpation, the systemic therapy with immunological agents and targeted therapy remain a viable option. Recent reports have indicated encouraging results with these agents. Sorafenib, sunitinib and temsirolimus have all been shown to significantly alter the natural history of advanced RCC, and many more agents are currently being evaluated. Trials evaluating combinations of these agents are currently underway or planned, and the optimal sequence of use of these agents is also being evaluated. However, much more evidence is necessary before the utility of these novel inhibitors of angiogenesis is established in providing the ultimate clinical benefit to patients diagnosed with RCC. In a recently reported phase

Grade Of Evidence in the Management of Metastatic Renal Cell Carcinoma

Intervention	Grade of Recommendation
Tumor nephrectomy + interferon- α *	A
Metastasectomy (synchronous and metachronous)*†	B
Radiotherapy	B
Chemotherapy (5-fluorouracil) + immunotherapy	B
Immunotherapy (control arm in trials, interferon- α + interleukin-2 for clear-cell histology)	A
Tyrosine kinase inhibitors (sorafenib as 2nd line, sunitinib as 1st line*, temsirolimus 1st line‡)	A

*Good performance status.

†Surgically resectable, metastasectomy in patients with residual disease should be performed in patients with resectable lesion previously responding to immunotherapy. This option has been recommended for osseous and brain lesions.

‡Poor-risk patients.

3, randomized, double-blind, placebo-controlled trial by Motzer and colleagues⁽⁴⁴⁾ the role of everolimus in patients with metastatic RCC was assessed. They noted that treatment with everolimus prolongs progression-free survival relative to placebo in patients with metastatic renal cell carcinoma that had progressed on other targeted therapies. The available agents for advanced RCC are toxic but can prolong life for a couple of months.

CONFLICT OF INTEREST

None declared.

REFERENCES

- Jemal A, Siegel R, Ward E, et al. Cancer statistics, 2008. *CA Cancer J Clin*. 2008;58:71-96.
- Eble JN. International agency for research on cancer. World Health Organization, editors. Pathology and genetics of tumours of the urinary system and male. Genital organs. Lyon: IARC Press; 2004.
- Janzen NK, Kim HL, Figlin RA, Belldegrun AS. Surveillance after radical or partial nephrectomy for localized renal cell carcinoma and management of recurrent disease. *Urol Clin North Am*. 2003;30:843-52.
- Citterio G, Bertuzzi A, Tresoldi M, et al. Prognostic factors for survival in metastatic renal cell carcinoma: retrospective analysis from 109 consecutive patients. *Eur Urol*. 1997;31(3):286-91.
- Latif F, Tory K, Gnarra J, et al. Identification of the von Hippel-Lindau disease tumor suppressor gene. *Science*. 1993;260:1317-20.
- Kaelin WG, Jr. The von Hippel-Lindau protein, HIF hydroxylation, and oxygen sensing. *Biochem Biophys Res Commun*. 2005;338:627-38.
- Kim WY, Kaelin WG. Role of VHL gene mutation in human cancer. *J Clin Oncol*. 2004;22:4991-5004.
- Mandriota SJ, Turner KJ, Davies DR, et al. HIF activation identifies early lesions in VHL kidneys: evidence for site-specific tumor suppressor function in the nephron. *Cancer Cell*. 2002;1:459-68.
- Michalopoulos GK, DeFrances MC. Liver regeneration. *Science*. 1997;276:60-6.
- Hudes G, Carducci M, Tomczak P, et al. Temsirolimus, interferon alfa, or both for advanced renal-cell carcinoma. *N Engl J Med*. 2007;356:2271-81.
- Minardi D, Lucarini G, Filosa A, et al. Prognostic role of tumor necrosis, microvessel density, vascular endothelial growth factor and hypoxia inducible factor-1alpha in patients with clear cell renal carcinoma after radical nephrectomy in a long term follow-up. *Int J Immunopathol Pharmacol*. 2008;21:447-55.
- Margulis V, Sanchez-Ortiz RF, Tamboli P, Cohen DD, Swanson DA, Wood CG. Renal cell carcinoma clinically involving adjacent organs: experience with aggressive surgical management. *Cancer*. 2007;109:2025-30.
- Mosharafa A, Koch M, Shalhav A, et al. Nephrectomy for metastatic renal cell carcinoma: Indiana University experience. *Urology*. 2003;62:636-40.
- Thyaviahally YB, Mahantshetty U, Chamarajanagar RS, Raibhattanavar SG, Tongaonkar HB. Management of renal cell carcinoma with solitary metastasis. *World J Surg Oncol*. 2005;3:48.
- Pantuck AJ, Belldegrun AS, Figlin RA. Cytoreductive nephrectomy for metastatic renal cell carcinoma: is it still imperative in the era of targeted therapy? *Clin Cancer Res*. 2007;13:693s-6s.
- Flanigan RC, Salmon SE, Blumenstein BA, et al. Nephrectomy followed by interferon alfa-2b compared with interferon alfa-2b alone for metastatic renal-cell cancer. *N Engl J Med*. 2001;345:1655-9.
- Mickisch GH, Garin A, van Poppel H, de Prijck L, Sylvester R. Radical nephrectomy plus interferon-alfa-based immunotherapy compared with interferon alfa alone in metastatic renal-cell carcinoma: a randomised trial. *Lancet*. 2001;358:966-70.
- Flanigan RC, Mickisch G, Sylvester R, Tangen C, Van Poppel H, Crawford ED. Cytoreductive nephrectomy in patients with metastatic renal cancer: a combined analysis. *J Urol*. 2004;171:1071-6.
- Snow RM, Schellhammer PF. Spontaneous regression of metastatic renal cell carcinoma. *Urology*. 1982;20:177-81.
- Troy AJ, Summers KL, Davidson PJ, Atkinson CH, Hart DN. Minimal recruitment and activation of dendritic cells within renal cell carcinoma. *Clin Cancer Res*. 1998;4:585-93.
- Rayman P, Wesa AK, Richmond AL, et al. Effect of renal cell carcinomas on the development of type 1 T-cell responses. *Clin Cancer Res*. 2004;10:6360S-6S.
- Quesada JR. Role of interferons in the therapy of metastatic renal cell carcinoma. *Urology*. 1989;34:80-3; discussion 7-96.
- [No authorlisted]. Interferon-alpha and survival in metastatic renal carcinoma: early results of a randomised controlled trial. Medical Research Council Renal Cancer Collaborators. *Lancet*. 1999;353:14-7.
- Pyrhonen S, Salminen E, Ruutu M, et al. Prospective randomized trial of interferon alfa-2a plus vinblastine versus vinblastine alone in patients with advanced renal cell cancer. *J Clin Oncol*. 1999;17:2859-67.
- Coppin C, Porzolt F, Awa A, Kumpf J, Coldman A, Wilt T. Immunotherapy for advanced renal cell cancer. *Cochrane Database Syst Rev*. 2005CD001425.
- Mule JJ, Yang JC, Afreniere RL, Shu SY, Rosenberg SA. Identification of cellular mechanisms operational in vivo during the regression of established pulmonary metastases by the systemic administration of high-dose recombinant interleukin 2. *J Immunol*. 1987;139:285-94.
- Yang JC, Sherry RM, Steinberg SM, et al. Randomized study of high-dose and low-dose interleukin-2 in patients with metastatic renal cancer. *J Clin Oncol*. 2003;21:3127-32.

28. McDermott DF, Regan MM, Clark JI, et al. Randomized phase III trial of high-dose interleukin-2 versus subcutaneous interleukin-2 and interferon in patients with metastatic renal cell carcinoma. *J Clin Oncol*. 2005;23:133-41.
29. Hotte S, Waldron T, Canil C, Winquist E. Interleukin-2 in the treatment of unresectable or metastatic renal cell cancer: a systematic review and practice guideline. *Can Urol Assoc J*. 2007;1:27-38.
30. Rosenberg SA. Interleukin 2 for patients with renal cancer. *Nat Clin Pract Oncol*. 2007;4:497.
31. Lassau N, Lamuraglia M, Leclere J, Rouffiac V. [Functional and early evaluation of treatments in oncology: interest of ultrasonographic contrast agents]. *J Radiol*. 2004;85:704-12.
32. Lamuraglia M, Escudier B, Chami L, et al. To predict progression-free survival and overall survival in metastatic renal cancer treated with sorafenib: pilot study using dynamic contrast-enhanced Doppler ultrasound. *Eur J Cancer*. 2006;42:2472-9.
33. Abrams TJ, Lee LB, Murray LJ, Pryer NK, Cherrington JM. SU11248 inhibits KIT and platelet-derived growth factor receptor beta in preclinical models of human small cell lung cancer. *Mol Cancer Ther*. 2003;2:471-8.
34. Motzer RJ, Hutson TE, Tomczak P, et al. Sunitinib versus interferon alfa in metastatic renal-cell carcinoma. *N Engl J Med*. 2007;356:115-24.
35. Motzer RJ, Rini BI, Bukowski RM, et al. Sunitinib in patients with metastatic renal cell carcinoma. *JAMA*. 2006;295:2516-24.
36. Wilhelm SM, Carter C, Tang L, et al. BAY 43-9006 exhibits broad spectrum oral antitumor activity and targets the RAF/MEK/ERK pathway and receptor tyrosine kinases involved in tumor progression and angiogenesis. *Cancer Res*. 2004;64:7099-109.
37. Escudier B, Szczylik C, Eisen T, et al. Randomized phase III trial of the Raf kinase and VEGFR inhibitor sorafenib (BAY 43-9006) in patients with advanced renal cell carcinoma (RCC). *J Clin Oncol*. 2005;23:LBA4510.
38. Chang YS, Adnane J, Trail PA, et al. Sorafenib (BAY 43-9006) inhibits tumor growth and vascularization and induces tumor apoptosis and hypoxia in RCC xenograft models. *Cancer Chemother Pharmacol*. 2007;59:561-74.
39. Motzer RJ, Bacik J, Schwartz LH, et al. Prognostic factors for survival in previously treated patients with metastatic renal cell carcinoma. *J Clin Oncol*. 2004;22:454-63.
40. Escudier B, Eisen T, Stadler WM, et al. Sorafenib in advanced clear-cell renal-cell carcinoma. *N Engl J Med*. 2007;356:125-34.
41. Presta LG, Chen H, O'Connor SJ, et al. Humanization of an anti-vascular endothelial growth factor monoclonal antibody for the therapy of solid tumors and other disorders. *Cancer Res*. 1997;57:4593-9.
42. Yang JC, Haworth L, Sherry RM, et al. A randomized trial of bevacizumab, an anti-vascular endothelial growth factor antibody, for metastatic renal cancer. *N Engl J Med*. 2003;349:427-34.
43. Escudier B, Pluzanska A, Koralewski P, et al. Bevacizumab plus interferon alfa-2a for treatment of metastatic renal cell carcinoma: a randomised, double-blind phase III trial. *Lancet*. 2007;370:2103-11.
44. Motzer RJ, Escudier B, Oudard S, et al. Efficacy of everolimus in advanced renal cell carcinoma: a double-blind, randomised, placebo-controlled phase III trial. *Lancet*. 2008;372:449-56.