

Preliminary histological study of the thymus in regularly slaughtered Chianina beef cattle to improve methods for the detection of illicit treatments

Martina Sebastianelli¹, Silvia Pavone¹, Claudio Forte¹, Stefano Mezzasoma², Maurizio Bordoni², Andrea Onofri³, Anna Fratto¹ and Elisabetta Manuali^{1*}

¹Laboratory of Veterinary and Comparative Histopathology, Istituto Zooprofilattico Sperimentale dell'Umbria e delle Marche 'Togo Rosati', via G. Salvemini 1, 06126 Perugia, Italy.

²Igiene degli allevamenti e delle Produzioni Zootecniche, Azienda Sanitaria Locale Umbria 1, Piazza del Tabacchificio 8, 06083 Bastia Umbra, Italy.

³Department of Agricultural and Environmental Sciences, Food and Environmental Sciences, University of Perugia, via Borgo XX Giugno 74, 06121 Perugia, Italy.

*Corresponding author at: Laboratory of Veterinary and Comparative Histopathology, Istituto Zooprofilattico Sperimentale dell'Umbria e delle Marche 'Togo Rosati', via G. Salvemini 1, 06126 Perugia, Italy. Tel.: +39 0753431, Fax +39 075343286, e-mail: e.manuali@izsum.it.

Veterinaria Italiana 2020, **56** (2), 137-140. doi: 10.12834/VetIt.1624.8712.1

Accepted: 01.03.2019 | Available on line: 31.12.2020

Keywords

Chianina cattle,
Thymus,
Cortex/medulla ratio.

Summary

Chianina is an Italian cattle breed appreciated for its meat and resilience skills. No standard values are present in literature regarding Chianina thymic involution. A possible early physiological involution has been reported during the Italian National Residue Plan screening tests. The aim of this work was to perform an anatomo-histopathological study of the thymus in Chianina cattle to improve knowledge about thymic involution in this breed. Forty Chianina bulls (16-24 months old), never treated with corticosteroids and regularly slaughtered in the Umbria region (Italy), were enrolled. Animals aged 19-21 months which received score 3 thymic atrophy had a prevalence of 0.15 (CI 95%: 0.02-0.45%), while the prevalence was 0.29 (CI 95%: 0.10-0.56%) among animals aged 22-24 months. The thymus/carcass weight and thymic cortex/medulla ratio resulted close to those reported in cattle experimentally challenged with corticosteroids. Results suggest that the Chianina breed could be characterized by a physiological premature involution of the thymus gland in comparison to other breeds. These results represent a starting point to increase the reliability of the National Residue Plan histological screening test.

Even if prohibited in the European Union by the Council Directive 96/23/EC¹, illicit treatments in beef cattle still represent a health safety problem. The rapid metabolism and elimination of these substances and the use of undetectable molecules can sometimes render the chemical investigations inconclusive (Imbimbo *et al.* 2012). Histological examination, introduced in Italy as screening test as part of the National Residues Plan (PNR - Ministry of Health)², still plays a key role to detect illegal treatments. It provides proof of morphological and functional alterations of the thymus caused by the

illegal use of corticosteroids with relatively low costs and in a short time (Castagnaro *et al.* 2006).

Treatments with corticosteroids cause early involution of the thymus, identifiable as both gross and microscopic lesions (Cannizzo *et al.* 2008). Thymus atrophy is considered a lasting indirect biomarker for the detection of treated animals (Vascellari *et al.* 2012), but recent findings seem to indicate that the cortex/medulla ratio (C/M) is strongly related to steroidal treatment in both veal calves and beef cattle, and that it is a more reliable

¹ Council Directive 96/22/EC of 29 April 1996 concerning the prohibition on the use in stockfarming of certain substances having a hormonal or thyrostatic action and of β -agonists, and repealing Directives 81/602/EEC, 88/146/EEC and 88/299/EEC.

² Ministero della Salute: Relazione finale. Piano Nazionale Residui 2009. Roma, Italy: 1-63. www.salute.gov.it/imgs/C_17_pubblicazioni_1296_allegato.pdf.

biomarker than the evaluation of fatty infiltration in the thymic parenchyma (Bozzetta *et al.* 2011).

Knowledge concerning the modifications of the thymus in beef bulls treated with corticosteroids is still fragmentary (Cannizzo *et al.* 2010), and there is an absolute lack of studies on the employment of these molecules in the national breeds. The experience gained during the PNR highlighted the need to clarify the meaning of the microscopic appearance of the thymus in young beef bulls belonging to the Chianina breed. Severe atrophy of the thymus is frequently observed in Chianina bulls even though illicit treatments with corticosteroids have always been excluded by liquid chromatography tandem mass spectrometry (LC-MS/MS). It is possible to suspect that early physiological involution of the thymus in Chianina bulls is likely related to genetic factors.

The aim of this work was to perform an anatomo-histopathological study of the thymus in regularly slaughtered Chianina beef cattle in the Umbria region (Italy), improve general knowledge about the physiological pattern of thymic involution in this breed and to increase the reliability of the PNR histological screening test.

A total of 40 Chianina beef bulls aged between 16 and 24 months, slaughtered in the Umbria region (Italy), were enrolled in this study. The animals came from two selected farms included in the PNR that resulted always negative for residues of corticosteroids when periodically checked. From documental analysis, conducted in the farms' treatment registers and veterinary prescriptions, it can be asserted that animals have never been subjected to corticosteroid or antimicrobial therapy.

At slaughtering, cervical and thoracic portions of the thymus of each animal were collected and weighed. The thymus weight/carcass weight ratio was calculated as suggested by Biolatti and colleagues (Biolatti *et al.* 2005). The central area of the thoracic thymus of each animal was collected and fixed in 10% neutral buffered formalin. The tissue samples were paraffin-embedded and stained with haematoxylin and eosin (HE). The morphology of the thymic parenchyma was evaluated for adipose tissue infiltration associated with cortical atrophy, according to Bozzetta and colleagues (Bozzetta *et al.* 2011), and Vascellari and colleagues (Vascellari *et al.* 2012), and a score from 1 to 3 (mild, moderate, severe) was attributed, as PNR guidelines request. The scoring system was blindly performed by three independent observers and inter-laboratory agreement was evaluated by K Cohen test (K Cohen = 0.84), confirming the histological grading assigned.

For the morphometrical evaluation, sections of

the thymus were examined at low magnification (5x) using a Nikon DS-Fi1 digital camera (Nikon Corporation, Tokyo, Japan) connected to the microscope Leica DMR (Leica Microsystems, Milan, Italy), using NIS-Elements Br-2 as software. The cortex/medulla ratios (C/M) were calculated as reported by Vascellari and colleagues (Vascellari *et al.* 2012).

Statistical analysis was carried out using R 2.7 version software. Descriptive statistics and box plots to graphically depict the groups of numerical data were performed. Kruskal-Wallis followed by Pairwise comparisons made with Wilcoxon's rank-sum test were used to compare histological and morphometrical data. The P value of 0.05 was the assumed significance level. A beta regression model was used to determine correlation between thymus weight/carcass weight ratio, age and atrophy score.

No differences were observed through the beta regression model when comparing weight data with the degrees of thymic atrophy of the samples. A negative correlation between age and T/C ratio was registered, in line with the normal physiologic pattern of thymic involution (Table I). The average value of 0.164 observed for thymus weight/carcass weight ratio in younger animals (16-18 months) is lower than that found in 5 months old veal calves experimentally treated for 21 days with DEX (T/C = 1.75) (Cannizzo *et al.* 2011); in 17-22-month-old Charolaise beef cattle challenged with DEX for 40 days, the average T/C value was 0.29 (Cannizzo *et al.* 2011). Comparing this value with the result (T/C = 0.134) obtained on the same age class (19-21 months), it is clear that the value showed by untreated Chianina bulls is still lower than that of the treated Charolaise, confirming a remarkable thymic involution in the untreated Chianina bulls included in the study.

A total of 21 samples (52.5%) showed slight thymic atrophy due to mild infiltration of adipose tissue (score 1) (Figure 1a), 12 samples (30%) showed moderate fatty infiltration and initial replacement of the cortex (score 2) (Figure 1b), and 7 samples (17.5%) showed severe adipose infiltration and marked

Table I. Chianina beef bulls. Average values of thymus weight, carcass weight, and T/C ratio for each age and relative SEM and P.

Age (months)	Thymus weight (g)	Carcass weight (kg)	T/C
16-18	600.60 A	370.10 A	0.164 A
19-21	537.20 AB	408.00 AB	0.134 AB
22-24	494.18 B	460.81 B	0.108 B
SEM	25.865	20.851	0.008
P	0.0495	0.0154	0.0007

T/C = Thymus weight/carcass weight ratio; SEM = Standard error of mean.

cortex atrophy that often reduced the medullary framework, up to the complete replacement of the lymphoid tissue by fat (score 3) (Figure 1c). The distribution of the degrees of atrophy according to age is shown in Table II, while descriptive statistics for C/M ratio is provided in Figure 2. None of the animals aged 16-18 months received score 3 (CI 95%: 0-0.03%). Animals aged 19-21 months which received score 3 had a prevalence of 0.15

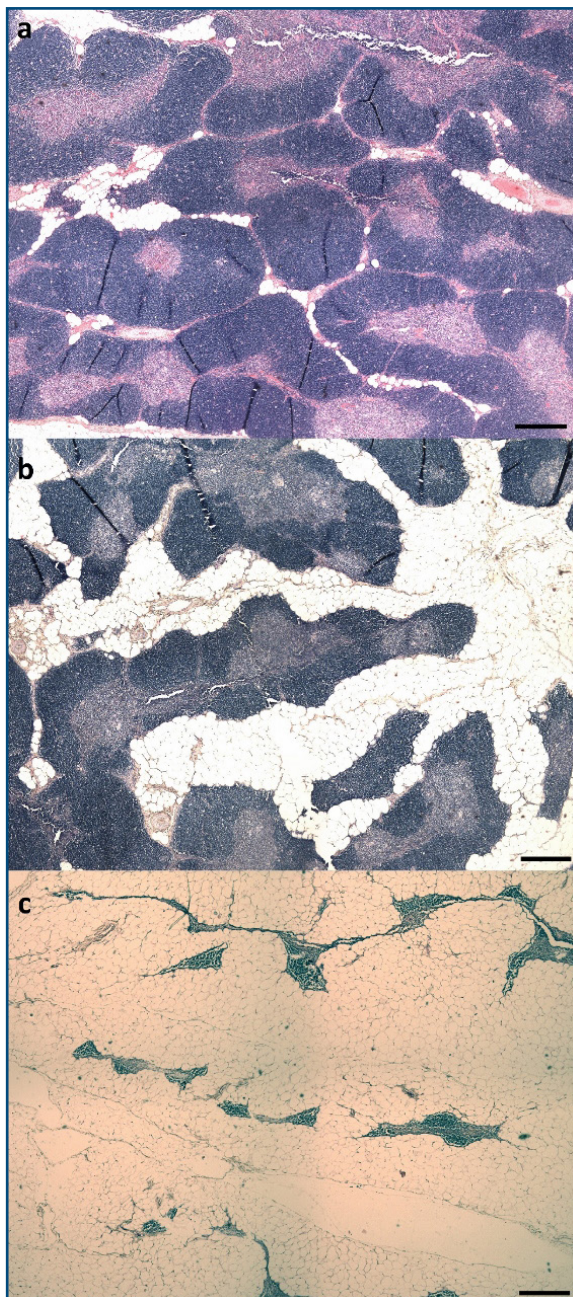


Figure 1. **a.** Slight thymic atrophy due to mild infiltration of adipose tissue (score 1). **b.** Moderate fatty infiltration and initial replacement of the cortex (score 2). **c.** Severe adipose infiltration and marked cortex atrophy that reduces the medullary framework, up to the complete replacement of the lymphoid tissue by fat. Remnants of the parenchyma are represented solely by small islets of lymphocytes, positioned around the vessels that run through the adipose tissue (score 3). Bars 200 μ m.

(CI 95%: 0.02-0.45%), while the prevalence of score 3 among animals aged 22-24 months was 0.39 (CI 95%: 0.10-0.56%).

The results of the morphometric investigations showed a mean value of thymic C/M diameter ratio of 0.6 for score 3 samples. This value was similar or lower than that reported in animals experimentally treated with corticosteroids (0.53 in Charolaise beef cattle, Vascellari *et al.* 2012; 1 for veal calves, Bozzetta *et al.* 2011). Even if the negative results derived from chemical and documentary investigations carried out during the official checks excluded the hypothesis of illicit treatments, considering the histological screening tests currently in use, 17.5%

Table II. Chianina beef bulls. Prevalence data of thymus atrophy score for each age and relative 95% confidence interval.

Age (months)	Thymus atrophy score	Prevalence	CI (95%)
16-18	1	0.80	0.44-0.97
	2	0.20	0.03-0.56
	3	0.00	0.00-0.31
19-21	1	0.54	0.25-0.81
	2	0.31	0.09-0.61
	3	0.15	0.02-0.45
22-24	1	0.35	0.14-0.62
	2	0.35	0.14-0.62
	3	0.39	0.10-0.56

Thymus atrophy score: 1 mild infiltration of adipose tissue at the periphery of the lobules, 2 moderate fat interstitial infiltration with thinning and initial replacement of the cortex, 3 severe adipose infiltration of the parenchyma and marked cortex atrophy that reduces the medullary framework, up to the complete replacement of the lymphoid tissue by fat.
CI = Confidence interval.

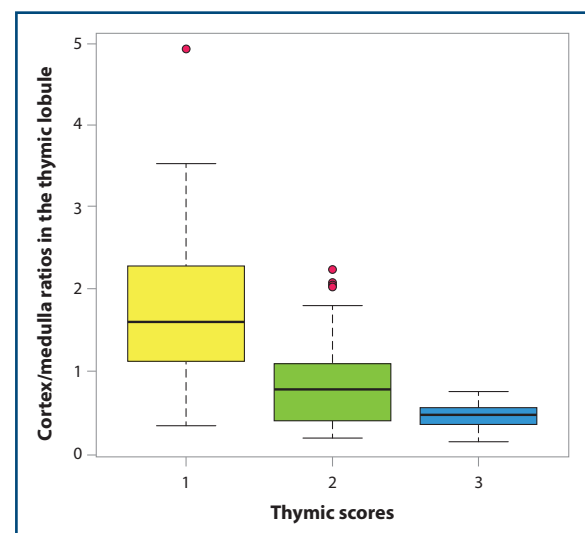


Figure 2. Correlation between atrophy score categories and cortex/medulla ratio values.

of the animals included in this study may have been illegally treated with corticosteroids.

We used suitable samples and proposed a valuable tool to verify the normal involution process of the thymus in the Chianina breed, contributing to the identification of the different age-dependent involution patterns that should be considered normotypical in this breed. The purpose of this study was also to improve the reliability of the histological method adopted within PNR screening tests, to

avoid overestimating the problem of illicit treatment with CSs in this breed and to report false positive cases in terms of screening. Our study showed an early thymic gland involution in Chianina beef cattle and provided the first data for this breed. Further studies should be performed on a greater number of animals held under controlled conditions, including challenges with corticosteroids, aimed at defining the complete physiological involution process of the thymus gland in the Chianina breed.

References

- Biancotto G., Stella R., Pozza G., Stefani A., Lega F. & Angeletti R. 2012. Sub-therapeutic treatments of bulls with dexamethasone: direct and indirect markers of treatment. *Food Addit Contam*, **30** (3), 430-442.
- Biolatti B., Bollo E., Cannizzo F.T., Zancanaro G., Tarantola M., Dacasto M., Cantiello M., Carletti M., Biolatti P.G. & Barbarino G. 2005. Effects of low-dose dexamethasone on thymus morphology and immunological parameters in veal calves. *J Vet Med A*, **52**, 202-208.
- Bozzetta E., Pezzolato M., Maurella C., Varello K., Richelmi G.B., Draisci R., Ferranti C., D'Angelo A. & Caramelli M. 2011. Development of an enhanced histopathological approach to detect low-dose dexamethasone illicit treatment in veal calves. *Food Addit Contam*, **28**, 1187-1192.
- Cannizzo F.T., Miniscalco B., Riondato F., Bollo E., Barbarino G., Giorgi P., Mazzini C. & Biolatti B. 2008. Effects of anabolic and therapeutic doses of dexamethasone on thymus morphology and apoptosis in veal calves. *Vet Rec*, **163**, 448-452.
- Cannizzo F.T., Capra P., Divari S., Ciccotelli V., Biolatti B. & Vincenti M. 2011. Effects of low-dose dexamethasone and prednisolone long term administration in beef calf: chemical and morphological investigation. *Anal Chim Acta*, **700**, 95-104.
- Castagnaro M. & Poppi L. 2006. Indirect biomarkers of illegal anabolic treatments: five years of activity under the microscope. *Vet Res Commun*, **30** (Suppl. 1), 105-108.
- Imbimbo P., Castigliengo L., Armani A., Biolatti B., Cannizzo F.T., Gianfaldoni D. & Guidi A. 2012. A histologic study on growth promoter target organs of slaughtered beef in Molise Region (Italy). *J Vet Med Sci*, **74** (10), 1253-1259.
- Vascellari M., Capello K., Stefani A., Biancotto G., Moro L., Stella R., Pozza G. & Mutinelli F. 2012. Evaluation of thymus morphology and serum cortisol concentration as indirect biomarkers to detect low-dose dexamethasone illegal treatment in beef cattle. *BMC Vet Res*, **8**, 129.