

Dermoscopic appearance of an amelanotic mucosal melanoma

Andreas Blum¹, Ulrike Beck-Zoul², Laura Held³, Sylvie Haase¹

1 Public, Private and Teaching Practice of Dermatology, Augustinerplatz 7, 78462 Konstanz, Germany

2 Public and Private Practice of Gynecology, Rosgartenstrasse 27, 78462 Konstanz, Germany

3 Dermatopathology, Siemensstraße 6/1, 88048 Friedrichshafen, Germany

Key words: melanoma, mucosal melanoma, dermoscopy

Citation: Blum A, Beck-Zoul U, Held L, Haase S. Dermoscopic appearance of an amelanotic mucosal melanoma. *Dermatol Pract Concept* 2016;6(4):5 .doi: 10.5826/dpc.0604a05

Received: August 24, 2016; **Accepted:** August 31, 2016; **Published:** October 31, 2016

Copyright: ©2016 Blum et al. This is an open-access article distributed under the terms of the Creative Commons Attribution License, which permits unrestricted use, distribution, and reproduction in any medium, provided the original author and source are credited.

Funding: None.

Competing interests: The authors have no conflicts of interest to disclose.

All authors have contributed significantly to this publication.

Corresponding author: Andreas Blum, MD, MSc, Public, Private and Teaching Practice of Dermatology, Augustinerplatz 7, 78462 Konstanz, Germany. Tel. +49 7531 643 11; Fax. +49 7531 600 54. Email: a.blum@derma.de

ABSTRACT **Background:** Hypomelanotic or amelanotic melanomas are challenging to identify, especially at mucosal sites. The dermoscopic clues to the diagnosis of mucosal melanomas have been reported to be structureless zones with the presence of blue, gray, or white colors.

Case: A female in her seventies noted a new lesion on the inside of her right labia that first appeared two months prior. Her past medical history was significant for rheumatoid arthritis requiring ongoing treatment with methotrexate for 20 years and adalimumab for 10 years. After no response to two weeks of local treatment for suspected herpes simplex infection, her gynecologist performed a skin biopsy. Based on the histopathological diagnosis of an amelanotic melanoma (Breslow thickness of 1.3 mm) the patient was referred to dermatology for further assessment. Polarized dermoscopy revealed a distinct asymmetric, sharply demarcated homogenous white papule (4 x 5 mm) as well as polymorphous vessels.

Conclusion: Dermoscopy may aid in the diagnosis of amelanotic mucosal melanomas. Our case revealed a structureless white area and polymorphous vessels. Additional clues to the diagnosis were the advanced age of the patient and the clinical presentation of a new lesion.

Case Report

A female in her seventies, skin phototype II, presented to her gynecologist with a two-month history of a lesion on the inside of her right labia minora. Her past medical history was significant for rheumatoid arthritis requiring ongoing treatment with methotrexate for 20 years and adalimumab for 10

years. Her gynecologist prescribed, based on the suspicion of a herpes simplex infection, acyclovir 5% cream and, after some days, a hydrocortisone 1% / clotrimazole 1% cream for two weeks. Because no change was visible at the follow-up examination, a biopsy was taken of a part of the nodule. Based on the histopathological diagnosis of an amelanotic melanoma (Breslow thickness of 1.3 mm), the patient was

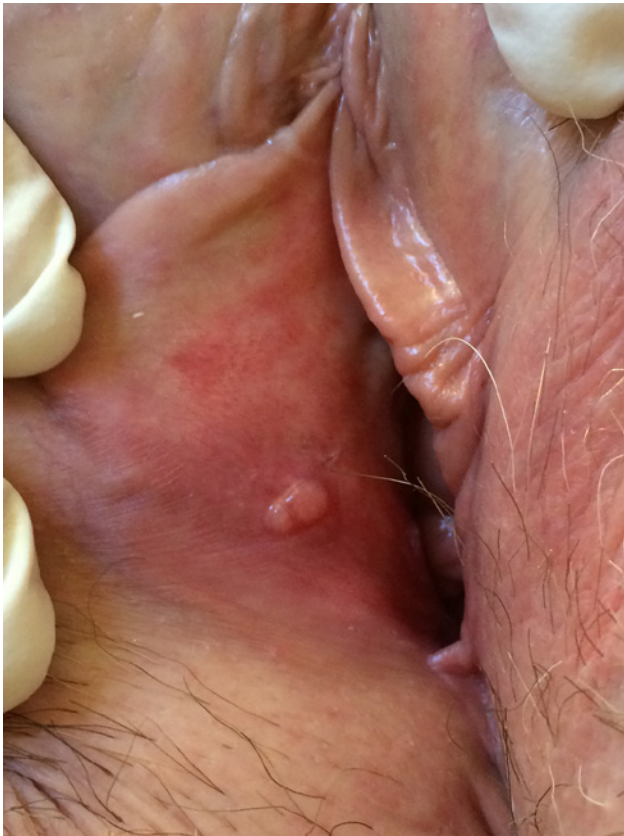

Figure 1. Clinical appearance of a non-pigmented lesion of the right labia. [Copyright: ©2016 Blum et al.]

referred to dermatology for closer examination. Clinically a whitish papule on the inside of her right labia minora was visible (Figure 1).

Under polarized dermoscopy a distinct asymmetric, sharp demarcated homogenous white papule (4 x 5 mm) with polymorphous vessels was present (Figure 2).

Histologic examination revealed malignant melanoma mucosal type with densely packed atypical spindly-shaped melanocytes with hyperchromatic nuclei, confirmed by positivity of anti-MelA antibody (Figure 3).

Conclusion

This case suggests that amelanotic mucosal melanoma may reveal diagnostic clues upon dermoscopic examination. A multicenter study that examined the dermoscopic appearance of mucosal lesions revealed that the combination of structureless zones with blue, gray or white color(s) is useful for the diagnosis of malignant lesions [1]. The highest diagnostic sensitivity was achieved when considering only the presence of blue, gray, or white color [1-3]. Furthermore, polymorphous vessels is also a hint for malignancy, particularly melanoma [4,5]. Additional clues to the diagnosis of our case included the age of the patient and the presentation of a new lesion [1].

Pigmented and non-pigmented lesions at the mucosa are difficult to examine clinically and dermoscopically. Therefore,

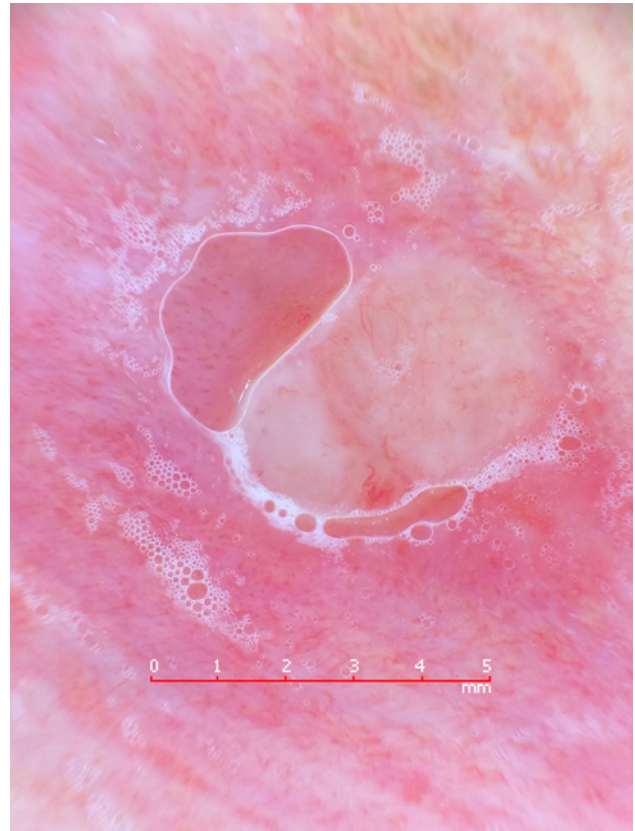


Figure 2. Polarized dermoscopy showing a distinct asymmetric, sharp demarcated homogenous white papule (4 x 5 mm) with polymorphous vessels (e.g., linear, curved, hairpin-like with different diameter) (handyscope, FotoFinder, Bad Birnbach, Germany; iPhone 5, Apple Inc., Cupertino, USA). [Copyright: ©2016 Blum et al.]

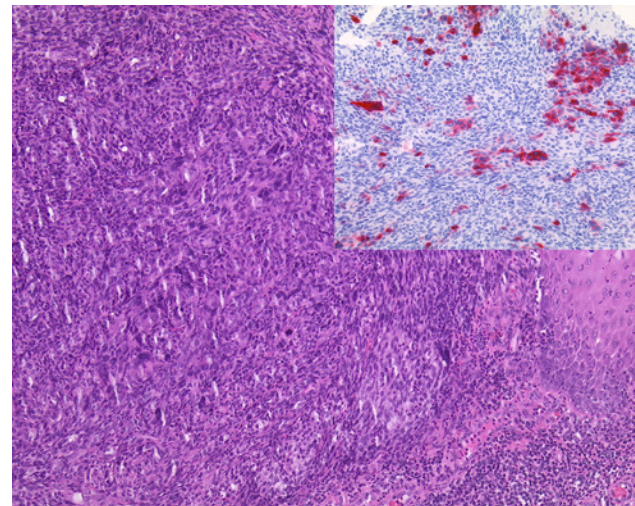


Figure 3. Histologic appearance: Histology revealed mucosal melanoma on hematoxylin and eosin: densely packed atypical spindly-shaped melanocytes with hyperchromatic nuclei, confirmed by positivity with anti-MelA antibody (top right inset). [Copyright: ©2016 Blum et al.]

the correct diagnosis is often delayed, leading to a poor prognosis of malignant tumors, especially mucosal melanomas [6]. Possible differential diagnoses of our case include herpes infection, condylomata acuminata, condyloma lata of syphilis, inflamed cysts or glands, and squamous cell carcinoma.

This observation encourages the use of the dermoscope at the mucosa even in non-pigmented lesions to diagnose a malignant process as soon as possible. All suspicious lesions should undergo prompt biopsy for definitive diagnosis.

References

1. Blum A, Simionescu O, Argenziano G, et al. Dermoscopy of pigmented lesions of the mucosa and the mucocutaneous junction: results of a multicenter study by the International Dermoscopy Society (IDS). *Arch Dermatol* 2011;147(10):1181-7. PMID:21680757. DOI: 10.1001/archdermatol.2011.155.
2. de Giorgi V, Massi D, Salvini C, et al. Thin melanoma of the vulva: a clinical, dermoscopic-pathologic case study. *Arch Dermatol* 2005;141(8):1046-7. PMID:16103344. DOI: 10.1001/archderm.141.8.1046.
3. Lin J, Koga H, Takata M, Saida T. Dermoscopy of pigmented lesions on mucocutaneous junction and mucous membrane. *Br J Dermatol* 2009;161(6):1255-61. PMID:19673880. DOI: 10.1111/j.1365-2133.2009.09251.x.
4. Menzies SW, Kreusch J, Byth K, et al. Dermoscopic evaluation of amelanotic and hypomelanotic melanoma. *Arch Dermatol* 2008;144:1120-7. PMID:18794455. DOI: 10.1001/archderm.144.9.1120.
5. Menzies SW, Moloney FJ, Byth K, et al. Dermoscopic evaluation of nodular melanoma. *JAMA Dermatol* 2013;149:699-709. PMID:23553375. DOI:10.1001/jamadermatol.2013.2466.
6. Mehra T, Grözinger G, Mann S, et al. Primary localization and tumor thickness as prognostic factors of survival in patients with mucosal melanoma. *PLoS One* 2014;10;9(11):e112535. PMID: 25383553. DOI:10.1371/journal.pone.0112535.